

# Relaxation of the Medial Collateral Ligament to Facilitate Pediatric Meniscal Surgery



Benjamin Sherman, D.O., Tanner Harrah, D.O., and John A. Schlechter, D.O.

**Abstract:** Meniscal injuries are becoming increasingly common in the pediatric population. During arthroscopic evaluation, pediatric patients typically have pristine articular cartilage and tight medial joint spaces. Therefore, when an arthroscope enters the medial compartment, iatrogenic damage to the articular cartilage may occur. Additionally, proper visualization of the medial meniscus (posterior horn or meniscocapsular junction) can prove to be difficult, and potential pathology may be missed. Proposed methods of increasing medial compartment visualization include the use of a 70° arthroscope placed through the intercondylar notch (Gillquist maneuver), creation of a posteromedial portal, or relaxation of the deep medial collateral ligament (MCL). Similar techniques have been described for use in adults for partial meniscectomy, but not in the pediatric population. The purpose of this Technical Note is to describe the steps to successfully perform the relaxation technique for meniscal repairs in pediatric patients, using an extra-articular outside-in percutaneous method.

**M**eniscal pathology in children and adolescents is common because of increasing participation in youth sports. Treatment typically consists of arthroscopic evaluation with partial meniscectomy versus repair. Repairs are preferred over meniscectomy in this population to preserve meniscal tissue and delay degenerative changes.<sup>1</sup> During arthroscopic evaluation, pediatric patients typically have pristine articular cartilage and tight medial joint spaces. Therefore, when an arthroscope enters the medial compartment, iatrogenic damage to the articular cartilage may occur. Additionally, proper visualization of the medial meniscus (posterior horn or meniscocapsular junction) can prove to be difficult, and potential pathology may be missed.

Recent studies indicate that in patients with anterior cruciate ligament (ACL) tears, there are concomitant

meniscal ramp lesions in 9% to 17%.<sup>2</sup> This area of the posteromedial meniscocapsular junction is known as the “blind spot,” and on average 21.5% of the posteromedial meniscus cannot be visualized using standard arthroscopic evaluation.<sup>3</sup> If missed, these ramp lesions can increase the stress on the reconstructed ACL and potentiate failure.

Proposed methods of increasing medial compartment visualization include the use of a 70° arthroscope placed through the intercondylar notch (Gillquist maneuver),<sup>4</sup> creation of a posteromedial portal,<sup>5</sup> or relaxation of the deep medial collateral ligament (MCL).<sup>6-12</sup> The use of a 70° arthroscope or a posteromedial portal may provide adequate visualization of the tear but will not improve the working room for instrumentation. These techniques necessitate the use of specialized instruments (e.g., suture lassos, tissue penetrators) to mend a posteromedial meniscocapsular lesion, whereas MCL relaxation does not. The purpose of this Technical Note is to describe the steps to successfully perform MCL relaxation for meniscal repairs in pediatric patients.

## Surgical Technique

### Indications

We perform this technique in every pediatric patient undergoing ACL reconstruction with suspected medial meniscal pathology to better evaluate for far posterior meniscocapsular tears, complex trilaminar vertical

*From the Riverside University Health System (B.S., T.H., J.A.S.), Moreno Valley, California, and the Children's Hospital of Orange County (J.A.S.), Orange, California, U.S.A.*

*The authors report the following potential conflicts of interest or sources of funding: J.A.S. reports other from Arthrex. Full ICMJE author disclosure forms are available for this article online, as [supplementary material](#).*

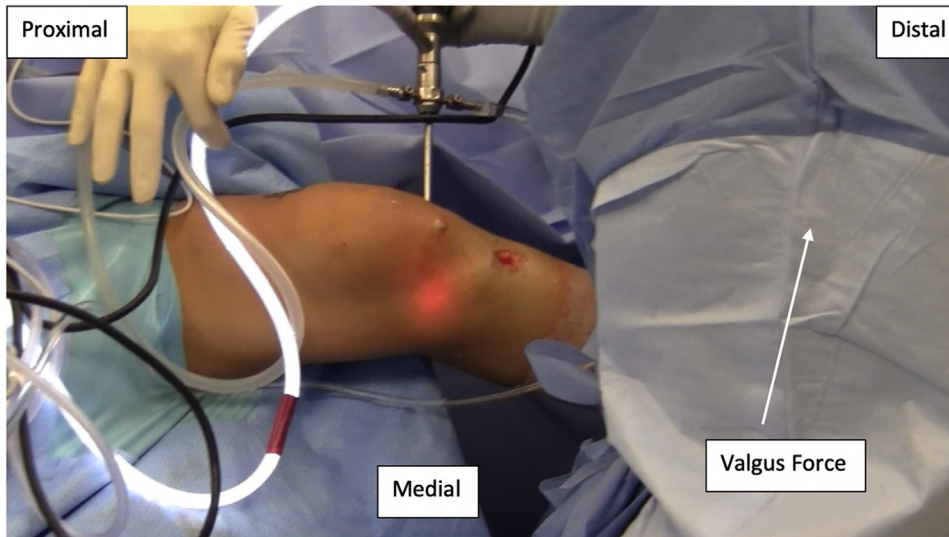*Received May 22, 2019; accepted July 17, 2019.*

*Address correspondence to Benjamin Sherman, D.O., Riverside University Health System, Moreno Valley, CA 92555. E-mail: [Sherms04@gmail.com](mailto:Sherms04@gmail.com)*

*© 2019 by the Arthroscopy Association of North America. Published by Elsevier. This is an open access article under the CC BY-NC-ND license (<http://creativecommons.org/licenses/by-nc-nd/4.0/>).*

*2212-6287/19670*

*<https://doi.org/10.1016/j.eats.2019.07.010>*



**Fig 1.** The positioning for relaxation of the medial collateral ligament (MCL) as viewed on a left knee from the medial side. The surgeon has placed the knee on his hip and is providing a valgus force to place the MCL on stretch.

tears, and ramp lesions. Additional indications include inadequate visualization of the medial compartment during knee arthroscopy.

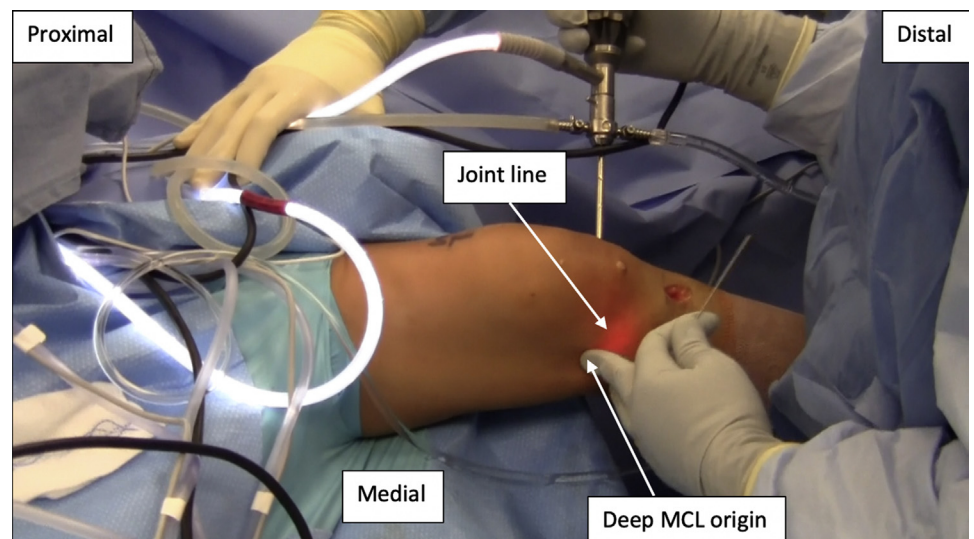
#### Preoperative Preparation and Positioning

The patient is positioned supine on a standard operative table and given general anesthesia with endotracheal intubation. A nonsterile tourniquet is placed high on the operative thigh, and a lateral post is placed around the level of the tourniquet. The patient is prepped and draped in the standard fashion.

#### Approach

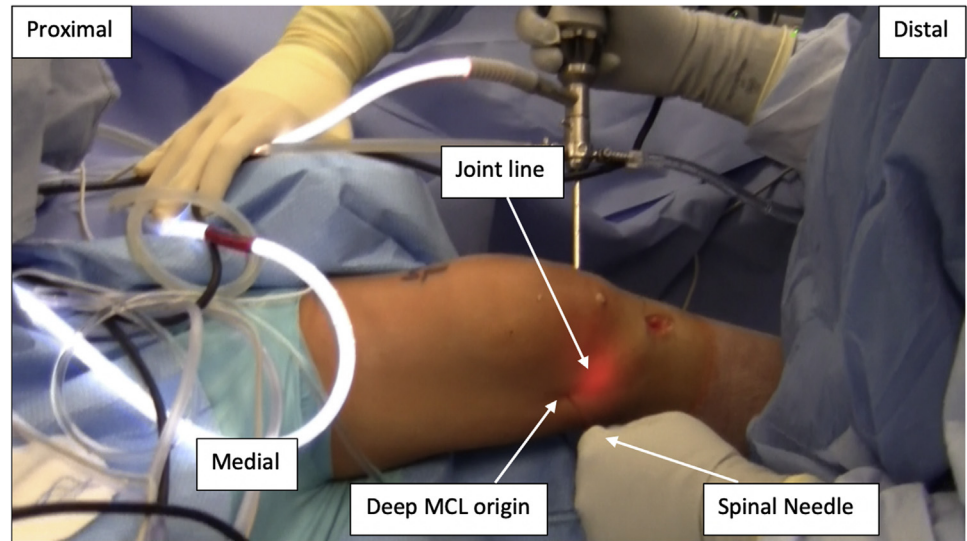
While viewing the medial compartment using the standard 4.0-mm, 30° arthroscope, the patient's

operative leg is placed onto the surgeon's hip. The surgeon provides a valgus force to place the MCL on stretch with the knee flexed to ~20° to 30° (Fig 1). Rotation is assessed and controlled by keeping the transepicondylar axis of the femur as close to horizontal as possible. The location of the deep MCL fibers is palpated ~1 fingerbreadth proximal to the medial joint line and just distal to the medial epicondyle (Fig 2). An 18-gauge spinal needle is then introduced into the deep MCL fibers with the bevel pointed proximally (Fig 3). A sawing motion is performed while inserting and withdrawing the needle into the deep tissue without allowing the needle to be withdrawn from the skin (Figs 4 and 5). This liberates the MCL and creates what we



**Fig 2.** This picture demonstrates the positioning for relaxation of the medial collateral ligament (MCL) as viewed on a left knee from the medial side. The location of the deep MCL fibers is palpated approximately 1 fingerbreadth proximal to the medial joint line and just distal to the medial epicondyle.

**Fig 3.** The medial collateral ligament (MCL) relaxation technique as viewed on a left knee from the medial side. An 18-gauge spinal needle is introduced 1 finger-breadth proximal to the medial joint line and just distal to the medial epicondyle into the deep MCL fibers with the bevel pointed proximally.

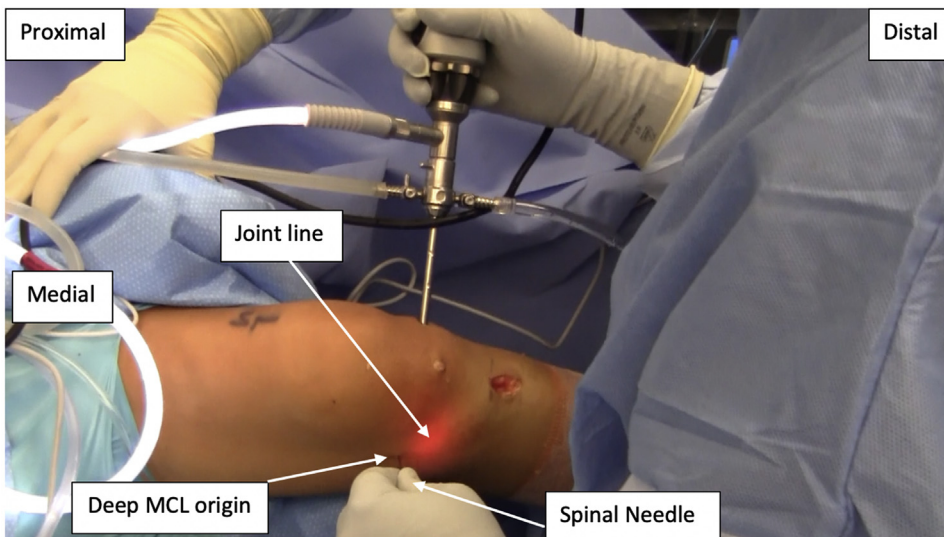


believe to be equivalent to a grade 2 MCL aberrancy. The arthroscope is positioned to monitor for accidental intra-articular penetration or meniscal injury and, most importantly, to assess incremental opening of the joint space (Fig 6). The movement of the spinal needle is immediately halted once visualization is adequate for assessment and repair (Fig 7). The amount of relaxation necessary is performed on a case-by-case basis (Fig 8). An all-inside suture repair device (Fast Fix 360; Smith and Nephew) can then be used to perform the meniscus repair with improved working space and visualization (Fig 9). The Video 1 demonstrates the technique for MCL relaxation and performing a meniscal repair in a

pediatric patient. Tables 1 and 2 review the advantages/disadvantages and pearls/pitfalls of using the MCL relaxation technique.

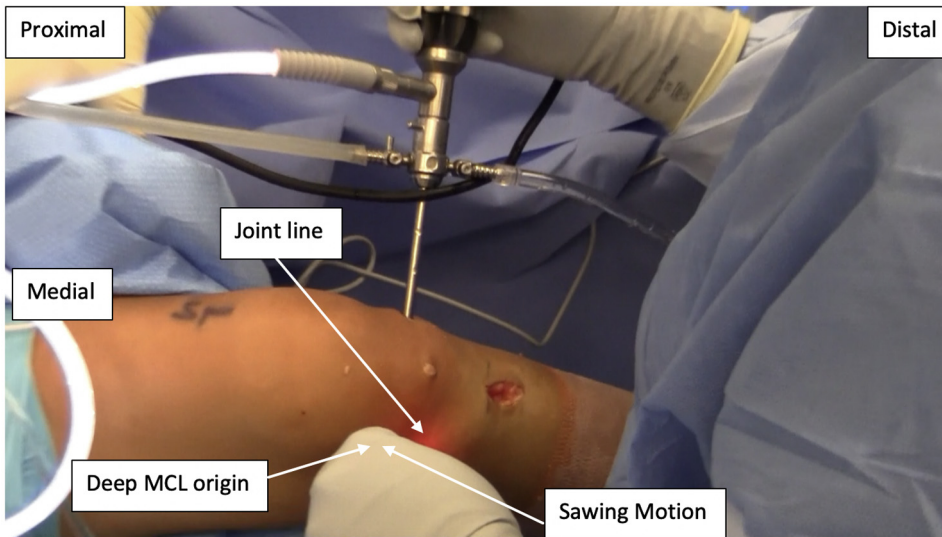
#### Postoperative Management

Postoperatively, children are placed into a brace with locked range of motion, and weightbearing restrictions are determined by the procedure performed. Immediate full range of motion is encouraged, and children are permitted to remove the brace for home exercises, physiotherapy, and continuous passive motion. Postoperative pain control is often obtained using a regional block with 0.25% bupivacaine with epinephrine, especially



**Fig 4.** The medial collateral ligament relaxation technique as viewed on a left knee from the medial side. The 18-gauge spinal needle is used in a sawing motion while inserting and withdrawing the needle into the deep tissue without allowing the needle to be withdrawn from the skin. The needle is moved anterior and posterior as seen when the surgeon lifts and lowers his hand.





**Fig 5.** This picture demonstrates the medial collateral ligament (MCL) relaxation technique as viewed on a left knee from the medial side. The 18-gauge spinal needle is used in a sawing motion while inserting and withdrawing the needle into the deep tissue without allowing the needle to be withdrawn from the skin. The needle is moved anterior and posterior as seen when the surgeon lifts and lowers his hand.

when meniscal work is performed in conjunction with cruciate reconstruction. No more than 10 doses of opiate medication are prescribed, and in the senior author's experience, usually <5 to 8 doses are typically used. The children are started in physical therapy within 1 to 2 weeks of surgery and progressed according to protocol.

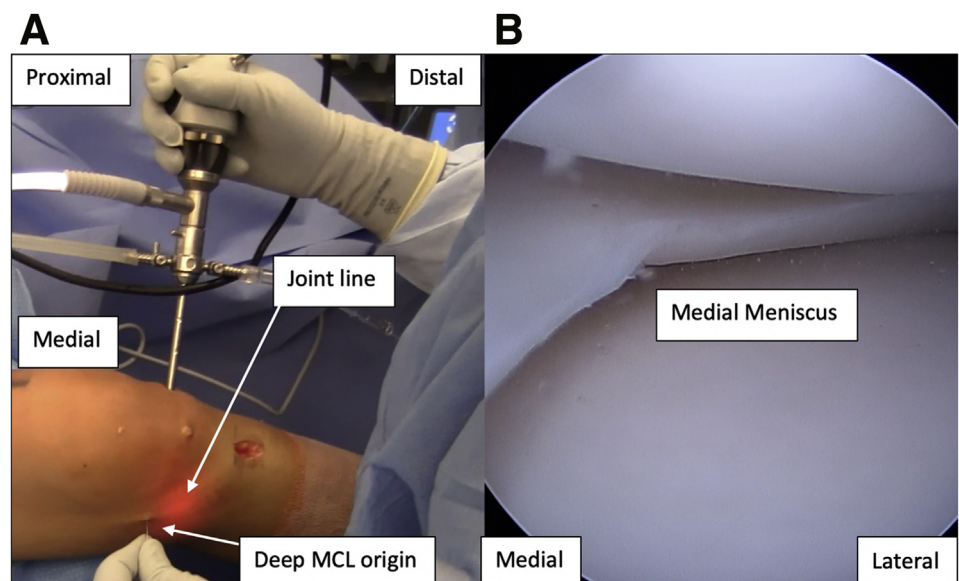
### Discussion

Medial compartment visualization during knee arthroscopy can be challenging, especially in the pediatric population. Advanced arthroscopic techniques such as relaxation of the MCL and accessory portal creation have been suggested to improve visualization.

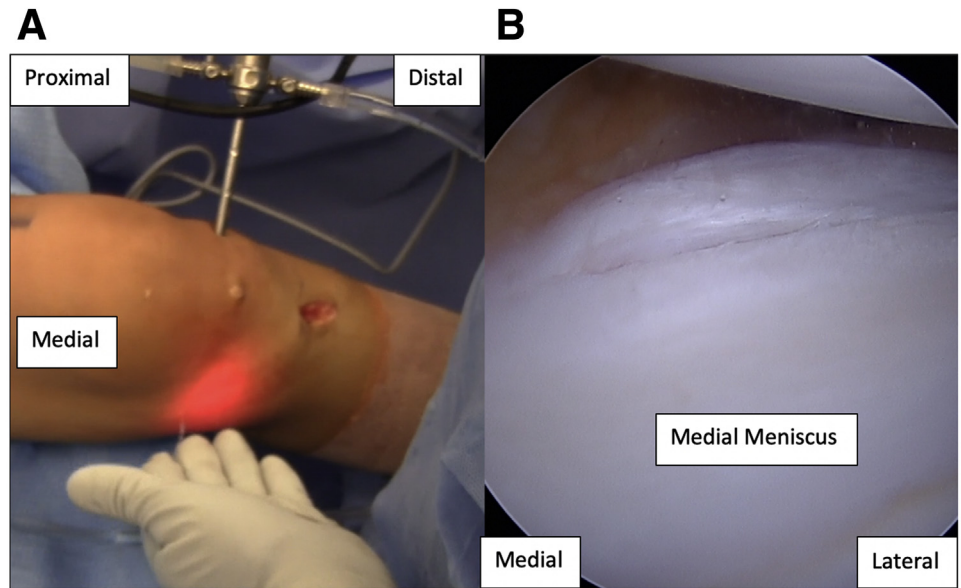
Without these advanced visualization techniques, diagnosing and treating medial meniscocapsular tears can be very challenging. Sonnery-Cottet et al.<sup>13</sup> examined the accuracy of the standard anterolateral portal in diagnosing medial meniscocapsular tears in 302 patients undergoing ACL reconstruction. The study found that 125 patients (41.4%) had medial meniscus tears, and of those, 50 (40%) were in the posterior meniscocapsular junction.<sup>13</sup> Using the standard anterolateral portal, none of the meniscocapsular tears could be diagnosed unless viewed through deep in notch (58%) or through a posteromedial portal (42%).<sup>13</sup>

Similar to use of a posteromedial portal, relaxation of the MCL increases visualization of the posterior

**Fig 6.** (A) The starting location for relaxation of the medial collateral ligament (MCL) as viewed on a left knee from the medial side. (B) The placement of the 30° arthroscope to monitor for intraarticular penetration of the 18-gauge spinal needle.



**Fig 7.** (A) The position of the knee after completing the medial collateral ligament relaxation technique as viewed on a left knee from the medial side. (B) The increase in medial compartment space after the relaxation technique has been performed using a 30° arthroscope.

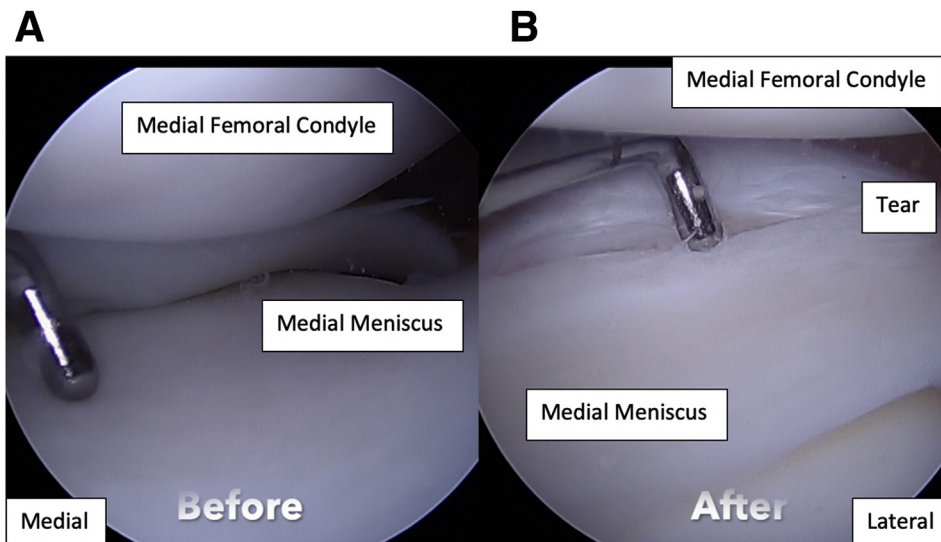


horn of the medial meniscus and allows for increased working space. The major concerns with MCL relaxation are valgus knee instability and injury to the saphenous nerve. Claret-Garcia et al.<sup>8</sup> performed an ultrasound study on 12 cadavers to determine the increase in medial joint space after liberation of the MCL. The study determined that relaxation of the deep MCL caused an increase in medial joint space by 1.9 mm at rest and 2.9 mm with valgus force.<sup>8</sup> Additionally, the study performed dissections of the cadavers afterward and found no incidence of injury to the infrapatellar branch of the saphenous nerve and a mean distance of 9 mm.<sup>8</sup> Similarly, Claret

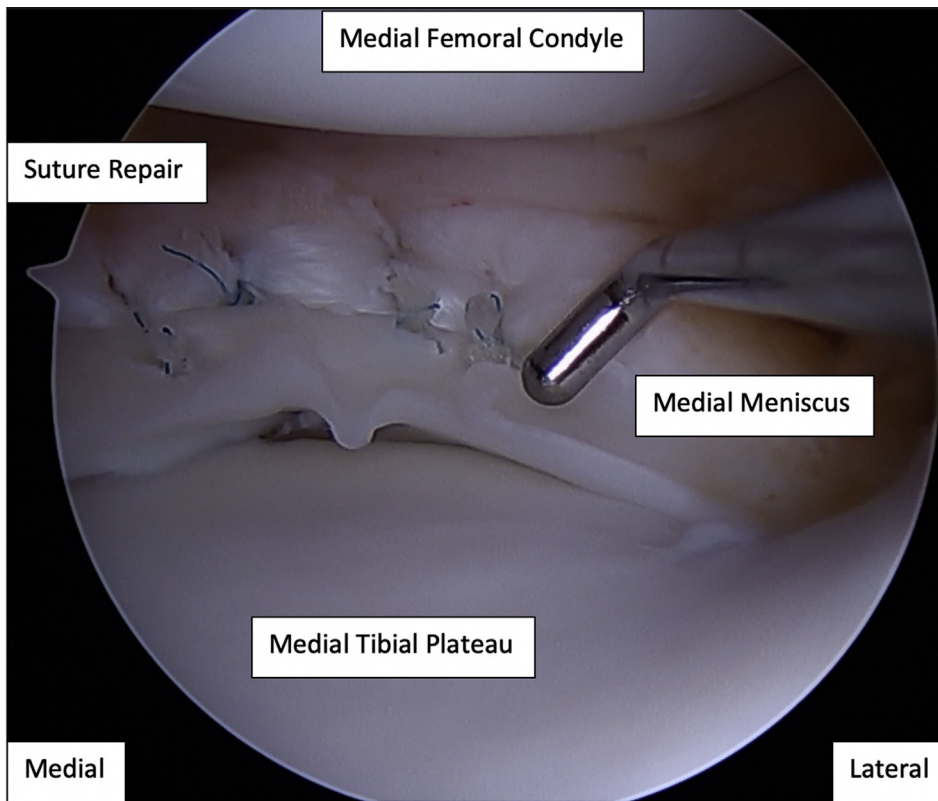
et al.<sup>7</sup> performed a retrospective review of 140 patients who had undergone arthroscopic meniscectomy with and without relaxation of the MCL. The study found no postoperative instability and improved clinical outcomes in the group that underwent meniscectomy with relaxation of the MCL.<sup>7</sup> Relaxation of the MCL is a safe and effective technique for increasing visualization and working space in the medial compartment.

### Conclusions

Although available studies have examined this technique in adults, we have used relaxation of the



**Fig 8.** Two arthroscopic images of a left knee as viewed in the medial compartment using a 30° arthroscope before (A) and after (B) relaxation of the medial collateral ligament to improve visualization.



**Fig 9.** A left knee as viewed in the medial compartment using a 30° arthroscope after performing the medial collateral ligament relaxation technique and a meniscal repair.

**Table 1.** Advantages and Disadvantages

Advantages	Disadvantages
Improved medial compartment visualization	Theoretical valgus instability
Decreased risk of iatrogenic chondral injury	Possible saphenous nerve injury
Increased working room	Possible iatrogenic meniscal injury
	Fluid extravasation

**Table 2.** Surgical Pearls and Pitfalls

Pearls	Pitfalls
Perform technique near the femoral attachment of the medial collateral ligament (MCL) to avoid intra-articular penetration	Using a larger than 18-gauge needle may cause the needle to bend, which may cause inaccurate needle position
Use the arthroscope to monitor release, halting the needle motion once visualization is adequate, and to watch for intra-articular injury	Vigorous insertion and withdrawal through the dermis at varied locations may increase the chance of saphenous nerve injury, intra-articular penetration in multiple sites, and thus fluid extravasation and potential meniscal injury

MCL in a pediatric population for the past several years without any observed valgus instability or saphenous nerve injury. We believe that this technique can be used safely and is efficacious in reducing iatrogenic cartilage damage when embarking on assessment and treatment of the medial meniscus in the pediatric population.

**References**

1. Mosich GM, Lieu V, Ebramzadeh E, Beck JJ. Operative treatment of isolated meniscus injuries in adolescent patients: A meta-analysis and review. *Sports Health* 2018;10(4):311-316.
2. Chahla J, Dean CS, Moatshe G, et al. Meniscal ramp lesions: Anatomy, incidence, diagnosis, and treatment. *Orthop J Sports Med* 2016;4(7). 2325967116657815.
3. Morin WD, Steadman JR. Arthroscopic assessment of the posterior compartments of the knee via the intercondylar notch: The arthroscopist’s field of view. *Arthroscopy* 1993;9(3):284-290.
4. Gillquist J, Hagberg G. A new modification of the technique of arthroscopy of the knee joint. *Acta Chir Scand* 1976;142(2):123-130.
5. Tolin BS, Sapega AA. Arthroscopic visual field mapping at the periphery of the medial meniscus: A comparison of different portal approaches. *Arthroscopy* 1993;9(3):265-271.
6. Buyukdogan K, Laidlaw MS, Miller MD. Meniscal ramp lesion repair by a trans-septal portal technique. *Arthrosc Tech* 2017;6(4):e1379-e1386.



7. Claret G, Montanana J, Rios J, et al. The effect of percutaneous release of the medial collateral ligament in arthroscopic medial meniscectomy on functional outcome. *Knee* 2016;23(2):251-255.
8. Claret-Garcia G, Montanana-Burillo J, Tornero-Dacasa E, et al. Pie crust technique of the deep medial collateral ligament in knee arthroscopy: Ultrasound and anatomic study. *J Knee Surg* 2018;32(8):764-769.
9. Zhu W, Tang Q, Liao L, Li D, Yang Y, Chen Y. Application of pie-crusting the medial collateral ligament release in arthroscopic surgery for posterior horn of medial meniscus in knee joint. *Zhong nan da xue xue bao Yi xue ban* 2017;42(9):1053-1057 [in Chinese].
10. Atoun E, Debbi R, Lubovsky O, Weiler A, Debbi E, Rath E. Arthroscopic trans-portal deep medial collateral ligament pie-crusting release. *Arthrosc Tech* 2013;2(1):e41-e43.
11. Bert JM. First, do no harm: Protect the articular cartilage when performing arthroscopic knee surgery! *Arthroscopy* 2016;32(10):2169-2174.
12. Jeon SW, Jung M, Chun YM, et al. The percutaneous pie-crusting medial release during arthroscopic procedures of the medial meniscus does neither affect valgus laxity nor clinical outcome. *Knee Surg Sports Traumatol Arthrosc* 2018;26(10):2912-2919.
13. Sonnery-Cottet B, Conteduca J, Thaunat M, Gunepin FX, Seil R. Hidden lesions of the posterior horn of the medial meniscus: A systematic arthroscopic exploration of the concealed portion of the knee. *American J Sports Med* 2014;42(4):921-926.