

Can Three-Dimensional Transvaginal Sonography Replace Office Hysteroscopy in Detecting Uterine Abnormalities in Infertility Patients?

Nikita Naredi, Rajesh Sharma¹, Pranay Gurmeet²

ART Centre, Army Hospital Bhopal, Pune, Maharashtra, ¹ART Centre, Army Hospital (R and R), New Delhi, ²ART Centre, Military Hospital Jalandhar, Jalandhar, Punjab, India

ABSTRACT

Background: Evaluation of uterine cavity is an important step during investigation of infertile women. The presence of uterine pathology causes impaired receptivity, failed implantation and poor pregnancy outcomes. Various investigative modalities though available; have their limitations. Hysteroscopy considered the gold standard diagnostic modality is invasive; thus, an investigation which could overcome its limitations was required. 3-Dimensional transvaginal sonography (3D TVS), which non-invasively visualizes uterine morphology, registers all three imaging planes simultaneously could be an alternative to hysteroscopy. **Aim:** To compare 3-D TVS with the gold standard office hysteroscopy for evaluating uterine cavity in sub fertile women. **Setting and Design:** It was a comparative study carried out at the Reproductive Medicine Centre of a tertiary care hospital. **Materials and Methods:** Over 12 months, 154 women with infertility underwent both hysteroscopy and 3D TVS. The primary outcome was to compare the sensitivity and specificity of 3D TVS in diagnosing endouterine abnormalities and assess if 3-DTVS could replace hysteroscopy for evaluation of uterine cavity. **Statistical Analysis:** The sensitivity, specificity, positive and negative predictive value and diagnostic accuracy of the 3-D TVS was calculated. **Results:** The 3-D TVS had a sensitivity of 88.46% ; specificity of 99.21% for detection of uterine abnormalities with hysteroscopy as gold standard. The Positive Predictive Value was 95.83%; Negative Predictive Value 97.69% and diagnostic accuracy was 97.4%. It was seen that of 24 lesions diagnosed by 3D TVS, hysteroscopy was in agreement with 21 lesions. **Conclusion:** 3D TVS with advantages of giving better spatial orientation, non-invasive, pain free, can replace hysteroscopy for screening endouterine lesions. With no statistically significant superiority of hysteroscopy over 3D TVS as seen in this study it may be deemed unnecessary in 50% patients having normal uterine cavity.

KEYWORDS: Three-dimensional transvaginal sonography, hysteroscopy, intrauterine abnormalities

INTRODUCTION

Evaluation and assessment of the uterine cavity form one of the most basic and important steps during investigation of infertile women as normal anatomy of the uterine cavity is essential for the physiological function of the endometrium and thus pregnancy to ensue. The presence of uterine pathology may cause

endometrial dysfunction, impaired receptivity, failed implantation and poor pregnancy outcomes such as recurrent miscarriages, preterm labour, etc.^[1] Although uterine factor infertility per-se affects only about

Address for correspondence: Dr Nikita Naredi, Senior Advisor (Obs & Gynae) & ART Specialist, Military Hospital, Bairagarh, Bhopal - 462 031, Madhya Pradesh, India. E-mail: nikitanaledi@gmail.com

Received: 02-07-2021
Accepted: 18-11-2021

Revised: 20-08-2021
Published: 31-12-2021

Access this article online

Quick Response Code:



Website:
www.jhrsonline.org

DOI:
10.4103/jhrs.jhrs_97_21

This is an open access journal, and articles are distributed under the terms of the Creative Commons Attribution-NonCommercial-ShareAlike 4.0 License, which allows others to remix, tweak, and build upon the work non-commercially, as long as appropriate credit is given and the new creations are licensed under the identical terms.

For reprints contact: WKHLRPMedknow_reprints@wolterskluwer.com

How to cite this article: Naredi N, Sharma R, Gurmeet P. Can three-dimensional transvaginal sonography replace office hysteroscopy in detecting uterine abnormalities in infertility patients?. J Hum Reprod Sci 2021;14:392-9.

3%–5% of the population, as many as 10%–15% of women seeking treatment for infertility are found to have uterine abnormalities.^[2] It has also been observed that unsuspected intrauterine pathologies may negatively affect the uterine environment and thereby the likelihood of achieving an ongoing pregnancy.^[3] Abnormal uterine findings have been found in 34%–62% of infertile women and the most common ones encountered are intrauterine synechiae/adhesions, polyps, submucous myomas as well as uterine malformations.^[4] This makes it imperative to diagnose and treat both significant and not so significant uterine abnormalities in patients seeking infertility treatment.^[4,5] A variety of modalities have been utilised in clinical practise for assessing uterine cavity such as hysterosalpingography (HSG), transvaginal sonography (TVS) or two-dimensional (2D) TVS, diagnostic hysteroscopy, saline infusion sonohysterography (saline sonohysterography [SSG]), three-dimensional TVS (3D TVS) and even magnetic resonance imaging (MRI). However, diagnostic hysteroscopy has remained the gold standard for infertility investigation for uterine pathologies for many decades.^[4,5]

In spite of the multiple advantages of hysteroscopy such as direct visualisation of the uterine cavity, revealing the nature, location, shape, size of the abnormality and being therapeutic, it is not without limitations.^[6,7] It is invasive, has operator's skill dependency and is not available at all centres. In addition, it is not a completely safe procedure having some known complications such as uterine perforation, cervical laceration, bleeding, limited access in cases of cervical stenosis.

A newer or advanced imaging modality which could overcome the limitations of hysteroscopy was a felt need and this was achieved with the advent of 3D transvaginal ultrasonography. 3D TVS, a new technique of imaging, has the ability to register all three imaging planes simultaneously as well as visualise the surfaces three dimensionally.^[8,9] It thus provides a unique diagnostic tool for non-invasive visualisation of the uterine morphology as well as the diagnosis of congenital uterine anomalies.^[10] The wide literature on myriad modalities for assessing endouterine pathologies in subfertile women along with their pros and cons prompted us to carry out a study comparing the two most promising modalities: 3D transvaginal ultrasound (TVS) and hysteroscopy. We aimed to compare the sensitivity, specificity, negative predictive value (NPV) and positive predictive value (PPV) of 3D TVS in comparison to hysteroscopy in diagnosing various intrauterine abnormalities and assess if 3D TVS can replace routine hysteroscopy for evaluation of subfertile women before *an in vitro* fertilisation (IVF) cycle.

MATERIALS AND METHODS

This prospective study was a diagnostic test evaluation carried out at the Assisted Reproductive Technology (ART) Centre of a Tertiary Care Hospital, over a period of 1 year from 1 March 2018 to 28 February 2019 after the approval of the Institutional Ethical Committee (approval number: AFMRC 4828/2017/IEC/2 dated 25 January 2017). It was performed in line with the principles of the Declaration of Helsinki. The main aim of the study was to compare the accuracy of 3D ultrasonography with office hysteroscopy (OH) and to assess the sensitivity, specificity, NPV and PPV of 3D TVS in comparison to OH in detecting uterine pathologies such as fibroids, polyps, adhesions and congenital anomalies in infertility patients planned for an IVF cycle. The least calculated number of women who could be included in the study were 86 patients. The calculation was based on a statistical significance level of 0.05% to yield a power of 90%. However, total of 154 participants were included depicting an adequate sample size. After obtaining written informed consent, only those patients who fulfilled the following inclusion and exclusion criteria were included in the study.

Inclusion criteria

- i. Women between 20 and 40 years of age
- ii. Cases of primary infertility or secondary infertility with no living child
- iii. No medical contraindications for pregnancy.

Exclusion criteria

- i. Patients with diagnosed uterine anomalies
- ii. Cases of premature ovarian failure
- iii. History of any previous uterine surgery
- iv. Cervical stenosis and inability to perform OH.

History and evaluation

After a detailed and thorough history taking all women underwent a baseline haematological and biochemical profile to rule out any associated disorders. A baseline hormonal profile encompassing assays of follicle stimulating hormone, luteinising hormone, anti-Mullerian hormone, serum prolactin (on day 2 of menstrual cycle) and thyroid profile was done.

Two-dimensional transvaginal sonography

A baseline TVS was carried out for all women presenting for infertility treatment irrespective of the day of their cycle and then enrolled for the study. The enrolled patients were given an appointment to report for a 3D TVS and Hysteroscopy within 10 days of their commencement of periods (follicular phase of the cycle). The operator doing the above two investigations were blinded to the findings of the 2D TVS.

Three-dimensional transvaginal sonography

A DC70 Mindray Ultrasound machine (Mindray, China), equipped with a DE11-3E 2.6–12.8 MHz endocavitary probe, was used to acquire 2D and 3D images during the early follicular phase of the menstrual cycle. Scanning was performed by two certified gynaecologists/infertility specialists in accordance with the following image acquisition protocol:

- (1) Examinations were performed during the early follicular phase, to facilitate the assessment of the uterine cavity, endometrial thickness and cervical appearance.
- (2) A 3 step examination protocol was followed:
 - (a) Initially, a 2D examination of the pelvis was performed and then, a 2D image of the sagittal section or mid-longitudinal plane of the uterus was obtained. To obtain the optimal 3D volume, the region of interest (ROI) was adjusted. The angle sweep taken was 90°. One to three static uterine volumes were obtained [Figure 1]

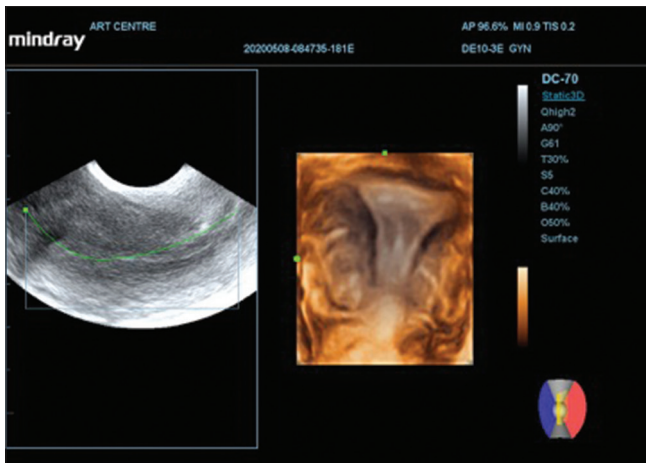


Figure 1: A mid-longitudinal (sagittal) section of the uterus in two dimensional with the region of interest adjusted for optimal acquisition of three-dimensional volume. The rendered image obtained by adjusting the rendering box containing the region of interest in Window A to include the uterine fundus

- (b) To obtain the rendered image, the rendering box containing the ROI in Window A was adjusted and the most important prerequisite was to include the uterine fundus. The automated mode was used for acquisition. It was mandatory that the multiplanar display being examined should have the whole uterus captured. The multiplanar view with longitudinal, transverse and coronal sections were utilised to analyse the 3D dataset which was captured. It was also made sure that the endometrium was evident in all 3 planes including the upper endometrial cavity and the isthmic portions of each tubes [Figure 1]
- (c) After the contrast and gain were modified and adjusted, the uterine morphology was analysed in different modes (rendered, tomographic ultrasound image, Omni View).

The most important anatomical features to be visualised for delineation and characterisation of the uterine anatomy were fundus and borders of the uterine cavity, interstitial portions of the fallopian tubes and uterine wall thickness. Capturing and analysis of all the images were carried out both in real time and after examination. The time taken for acquiring 3D image and their analysis ranged between 2 and 4 mins.

After image acquisition, the uterine cavity and the myometrium were studied for any uterine lesions: polyps/adhesions/myomas (submucous, intramural)/septum or other Mullerian anomalies [Figures 2 and 3]. The patients were then taken up for hysteroscopy.

Hysteroscopy

OH was done on the same day by another clinician who was not aware of the details of the ultrasonography report or the abnormality suspected by 3D TVS. The OH was performed by the vaginoscopic approach using a 3.7 mm/30° diagnostic single-flow office hysteroscope (Karl Storz) based with a 2.9-mm optic.

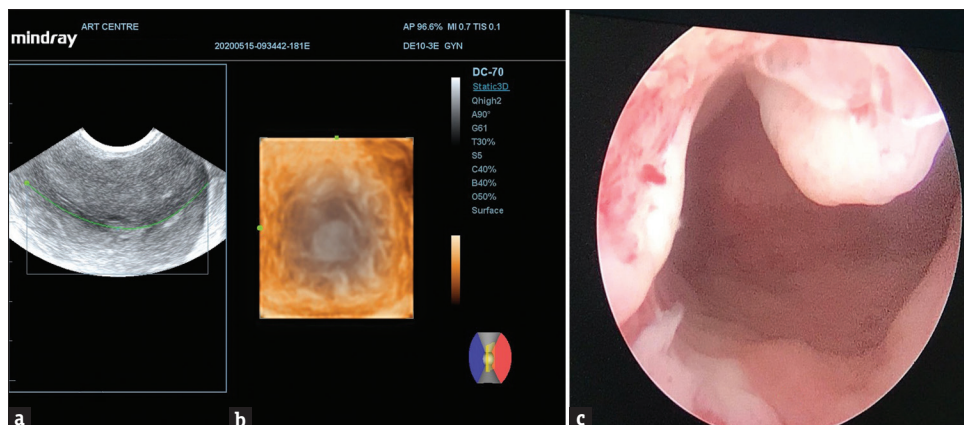


Figure 2: (a) Endometrial polyp as diagnosed by two-dimensional transvaginal sonography; (b) three-dimensional transvaginal sonography and on hysteroscopy; (c) Endometrial polyp

Continuous infusion of saline was done to accomplish distention of the uterine cavity. Hysteroscopy was considered complete only when the entire uterine cavity and both tubal ostia were visualised during the procedure. If OH could not be carried out due to cervical adhesion or cervical stenosis, the patient was excluded from the study.

Any abnormality detected in the form of polyps/septum/adhesions/myomas was noted and endorsed in the pro forma once both the modalities were carried out [Figures 2-4].

Statistical analysis

The data were recorded in Microsoft Excel worksheet and analysed by using statistical software Statistical Package for the Social Sciences (SPSS) Version 24.0 (IBM Corp. Released 2016. IBM SPSS Statistics for Windows, Version 24.0. Armonk, NY, USA: IBM Corp.).

Thereafter, the sensitivity, specificity, NPV and the PPV were calculated for 3D TVS with hysteroscopy as the gold standard. The diagnostic accuracy of 3D TVS was also assessed.

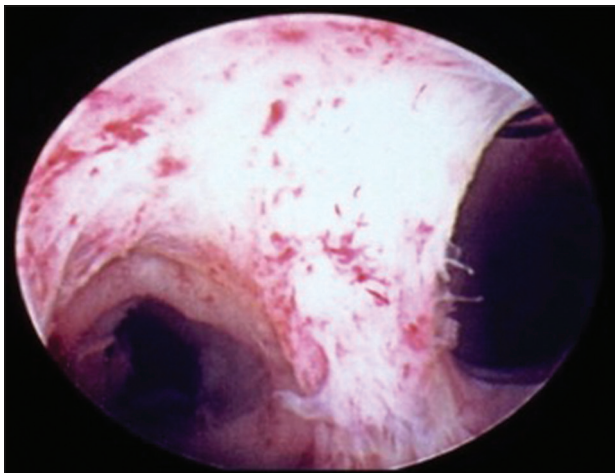


Figure 3: Two-dimensional and three-dimensional and hysteroscopic image of a unicornuate uterus

RESULTS

Subject characteristics

A total of 154 patients were included in the study who underwent both 3D transvaginal ultrasound as well as hysteroscopy on the same day by two different examiners. The patients' demographic profile in terms of age, body mass index, duration of infertility and endocrinological profile has been depicted in Table 1 with the mean age of the women being 27.8 ± 3.7 years and mean duration of infertility being 5.5 ± 3.1 years. The causes of subfertility in our study group are illustrated in Table 2. The most common cause of infertility was polycystic ovarian disease followed by a combined male and female factor subfertility.

Findings of three-dimensional transvaginal sonography

Of the total 154 women who underwent 3D TVS as part of the study, 130 women were found to have normal uterine cavity. The remainder 24 (15.58%) were detected to have uterine pathologies in the form of Mullerian anomalies, intrauterine lesion like polyps and adhesions. The most common pathology detected was polyp followed by septate uterus in 7 and 6 cases, respectively [Table 3].

Table 1: Demographic characteristics of the study subjects (n=154)

Characteristic	Mean±SD
Age (years)	27.8±3.7
BMI (kg/m ²)	24.97±4.48
Duration of infertility (years)	5.5±3.1
Hormonal profile	
LH (IU/L)	5.58±3.71
FSH (IU/L)	6.24±2.88
AMH (ng/ml)	4.73±3.96

SD: Standard deviation, BMI: Body mass index, LH: Luteinising hormone, FSH: Follicle-stimulating hormone, AMH: Anti-Mullerian hormone

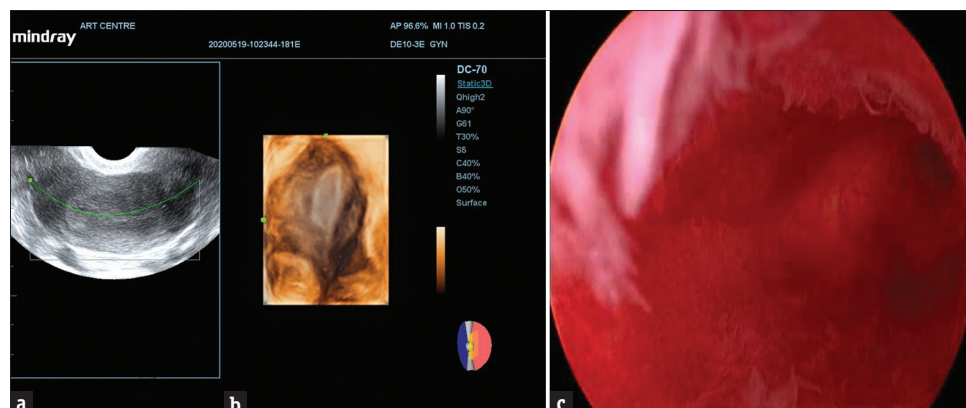


Figure 4: (a and b) Septation as seen on hysteroscopy. (c) Uterine septation

Findings on hysteroscopy

Hysteroscopy which followed 3D TVS detected uterine pathologies in 26 (16.88%) women of the total 154 study subjects and a normal uterine cavity in 128 women. The most common pathology found during hysteroscopy was a septate uterus followed by a polyp [Table 3].

Comparison of three-dimensional transvaginal sonography with hysteroscopy

As shown in Table 4, the 3D TVS was found to have a sensitivity of 88.46% and a specificity of 99.21% for the diagnosis and detection of uterine abnormalities with

Table 2: Cause of infertility in the study group

Cause	Frequency
PCOS	36
PCOS + tubal factor	5
PCOS + uterine factors	4
Combined (male + female factors)	25
Tubal factor	15
Unexplained	23
DOR	13
Male factor	12
Endometriosis	6
Endometriosis + tubal factor	6
Endometriosis + PCOS	4
Uterine factor	4
Cervical	1

PCOS: Polycystic ovarian syndrome, DOR: Decreased ovarian reserve

Table 3: Findings of three-dimensional transvaginal sonography and hysteroscopy

Finding	3D TVS (n=154)	Hysteroscopy (n=154)
Normal	130	128
Adhesion	1	2
Asherman's syndrome	1	1
Uterine septate	2	3
Bicornuate uterus	4	0
Arcuate uterus	3	3
Polyp	7	6
Septate	6	10
Periosteal fibrosis	0	1

3D TVS: three-dimensional transvaginal sonography

Table 4: Comparison of three-dimensional transvaginal sonography with hysteroscopy

3D USG	Office hysteroscopy		Total	Sensitivity (%)	Specificity (%)
	+	-			
+	23	1	24	88.46	99.21
-	3	127	130		
Total	26	128	154		

Positive predictive value: 95.83%, Negative predictive value: 97.69%, Diagnostic accuracy: 97.4%. 3D USG: 3D ultrasonography. +: Uterine abnormality detected. -: Uterine abnormality not detected

hysteroscopy taken as the gold standard. The PPV was 95.83% and NPV was 97.69%. The diagnostic accuracy of 3D TVS was 97.4%.

On subanalysis, it was seen that out of the 24 uterine lesions diagnosed by 3D TVS, the hysteroscopy was in agreement with 21 of the uterine lesions. The most common abnormality on 3D TVS was polyp found in 7 women which was further confirmed by hysteroscopy in 6 out of 7 of them.

As far as the congenital uterine anomalies are concerned the 3D TVS detected 6 septate uteri, however, OH documented septations to be present in 10 of the women. The four bicornuate uterus documented by 3D TVS were not confirmed by hysteroscopy.

DISCUSSION

The abnormalities of the uterus and uterine cavity being a contributor to infertility; its assessment forms a core component of infertility evaluation both for elucidating the aetiology and improving the treatment outcome, especially the various ART. The various intrauterine pathologies both congenital and acquired which hinder fertility and commonly encountered are fibroids, endometrial polyps, adhesions, Mullerian anomalies, etc.. The pathogenetic mechanism postulated for their impairment of fertility are altering endometrial receptivity, interfering with implantation, causing recurrent miscarriage and poor pregnancy outcome.^[1]

A variety of modalities have been used both by gynaecologists and reproductive medicine specialist alike for diagnosis of uterine abnormalities such as HSG, TVS or 2D TVS, diagnostic hysteroscopy, SSG, MRI and 3D TVS.^[1,11] Although the validity and limitation of every methodology have been measured and discussed in published data, diagnostic hysteroscopy has remained the gold standard in uterine cavity evaluation for infertility investigation.^[4,12,13]

In spite of being the gold standard for evaluating the uterine cavity for intracavitary lesions (polyps and myomas) by direct visualisation, hysteroscopy is invasive and not without complications.^[1] Furthermore, a concomitant laparoscopy with hysteroscopy may be mandatory for confirming Müllerian anomalies. Therefore, the invent and wide usage of 3D TVS occurred in the last decade. It has the advantage of providing a coronal view, being accurate, non-invasive and a pain free tool for endouterine evaluation. Thus, it revolutionised its place for evaluating uterine cavity and postulated to be a good alternative to the previous gold standards (combined hysteroscopy with laparoscopy or the MRI).

In our study of 154 women, we found normal uterine cavity on 3D TVS in 130 of them as opposed to 128 normal cavities on hysteroscopy which means 16.88% were detected to have a uterine pathology on the gold standard modality and 15.58% on 3D imaging depicting a concordance in the two investigative tools. This is in agreement to the published studies which says that although uterine factor infertility affects 10%–15% of couples seeking treatment for infertility, abnormal uterine findings may be found in 34%–62% of infertile women.^[2,4] The most common endouterine pathologies which have been visualised on imaging or hysteroscopy in the subfertile women are synechiae/adhesions, polyps and submucous myomas as well as uterine malformations.^[4] In our subject population too, the most common pathologies encountered were endometrial polyp and uterine septum. We did not get any fibroids or myomas in the present study population.

The initial work to establish the usefulness of 3D TVS for assessing endouterine pathologies compared it with HSG or 2D TVS which subsequently shifted to hysteroscopy which had established its place as ‘the’ investigation of choice for intrauterine lesions. Kupesic along with his coworkers assessed the role of 3D TVS as screening modality for subfertile women presenting for treatment. Their main goal of the study was to assess the true incidence of surgically correctable uterine abnormalities in the infertile population of 3850 women by doing screening through 3D TVS followed by operative hysteroscopy for its correction which was in concordance with TVS finding.^[14] It was not a comparative study between 3D TVS and hysteroscopy like ours, however, they opined that 3D TVS can be used as a screening method for detection of uterine abnormalities in patients suffering from infertility.

Midan *et al.* also wanted to evaluate the diagnostic accuracy of 3D TVS in comparison to diagnostic hysteroscopy and inferred that the total diagnostic accuracy for 3D TVS was 97.57% versus 93.71% for the hysteroscopy. Our study too found a diagnostic accuracy of 97.4% for 3D USG, but our study population was different than the study population of Midan *et al.*^[15] We studied all the women presenting for subfertility, but their study was on women suspected to have uterine lesions on HSG or 2D TVS. Their work inferred that diagnostic accuracy of 3D TVS is markedly higher in subjects with Mullerian anomalies than that of hysteroscopy as 3D TVS has better assessing capability for the surface contours and the myometrium. While in cases with intracavitary lesions, hysteroscopy had the upper hand over 3D TVS. Even we observed that the bicornuate uterus which was seen on 3D TVS was not

picked up by hysteroscopy. As far as intrauterine lesions are concerned, there was agreement in the findings in both the modalities in our study with minor differences which was not statistically significant. Apirakviriyaya *et al.* in their prospective observational cross-sectional study on 69 women with infertility studied the efficacy of 3D TVS and compared it to hysteroscopy and found 3D TVS to have a diagnostic accuracy of 84.1%.^[16] This comparative work on 3D TVS and hysteroscopy revealed a sensitivity of 68.2% and specificity of 91.5%, specificity with 79% PPV and 86% NPV which is lesser than our study. In this study by Apirakviriyaya, hysteroscopy diagnosed pathological findings in 22 of 69 cases (31.8%). There were 18 endometrial polyps, 3 submucous myomas and 1 septate uterus. 3D TVS successfully detected every case of submucous myoma and uterine anomaly. For detection of endometrial polyps, 3D TVS had 61.1% sensitivity, 91.5% specificity and 83.1% diagnostic accuracy. Thus, they concluded that hysteroscopy is a mandatory evaluative tool for subfertile women for accurate diagnosis.^[16] In our study, we had not calculated the sensitivity and specificity for individual pathologies, however, endometrial polyps were not missed out by 3D TVS. Seven were detected on 3D TVS and six were confirmed by hysteroscopy giving a high diagnostic accuracy.

Faivre *et al.* in their research compared OH and pelvic MRI and in turn estimated the accuracy of 3D ultrasonography in the evaluation of septate and bicornuate uterus.^[17] They concluded that transvaginal 3D ultrasonography appears to be extremely accurate for the diagnosis and classification of congenital uterine anomalies, more than OH and MRI. Their study stated that 3D TVS can become the only mandatory imaging in the assessment of the uterine cavity in patients with a suspected septate or bicornuate uterus.^[17] Bicornuate uterus can more efficiently be diagnosed by 3D TVS rather than hysteroscopy. Laparoscopy becomes mandatory in suspected cases.^[17] Even in our study, the 4 bicornuate uterus diagnosed by 3D TVS was not confirmed by hysteroscopy and laparoscopy was not done which is a limitation of our study. All septate uterus were confirmed by the gold standard hysteroscopy. Thus, most of the work has revealed a superiority of 3D TVS over hysteroscopy as far as Mullerian anomalies are concerned.^[15,16] This difference can be attributed to inability of hysteroscopy to visualise the external surface of the uterine cavity unless augmented by laparoscopy or magnetic resonant imaging. On the other hand, 3D TVS has the advantage of the coronal view like an MRI image which can overcome this problem by easily evaluating the exterior surface of the uterine cavity.

Although most studies have found concordance between OH and 3D TVS, Mishra did not find 3D TVS to be as sensitive as OH and in addition also found it to have a low PPV. In their study, considering OH as gold standard, 3D TVS had 17.11% sensitivity, 97.26% specificity, 44.83% PPV and 90.02% NPV.^[18] With their study, focusing primarily on endouterine assessment just before IVF, concluded that OH should be considered as the primary modality to assess uterine cavity before IVF as intrauterine abnormalities lead to poor implantation and in turn poor pregnancy rate in an IVF cycle.^[18] Laganà *et al.* also reported that despite the diagnostic accuracy and mini invasiveness of 3D SHG, it cannot be a substitute of hysteroscopy for diagnosing endouterine disease. It could be considered as a preliminary screening and then subject patients to hysteroscopic confirmation.^[19]

Most of the studies and workers across the globe have validated the role of 3D TVS in evaluation of the uterus and the uterine cavity in women presenting for subfertility and its treatment thereof. Sufficient evidence supports the advantages of 3D TVS in the clinical practice of reproductive medicine. As far as its status in comparison to the gold-standard hysteroscopy is concerned, there are mixed results with some finding it to be as diagnostically accurate and some research documenting hysteroscopy to be superior. In spite of the conflicting results, multiple advantages of 3D TVS including coronal view with better spatial orientation, accuracy and pain free, relative low cost support its place for evaluating uterine cavity and as a good alternative to the previous gold standards (combined hysteroscopy with laparoscopy or the MRI). In our study, there was no statistically significant superiority of hysteroscopy over 3D TVS. A diagnostic accuracy of 97.4% and a specificity of 99.21% with a NPV of 97.69% definitely secures its place to be used as a screening modality for uterus rather than going for hysteroscopy directly.

The small subject population and the non-usage of laparoscopy in combination to hysteroscopy for uterine anomalies is definitely a limitation of the study but nevertheless conforms to various other works about its place as a modality of choice for assessing uterine lesions.

Non-availability of a 3D TVS in all infertility units may be a restriction, but its usage is manifold for it to be ignored. We need to continue to test it prospectively and examine its best usage in the clinical setting both for the clinicians and for patients to be comfortable, with this, non-invasive modality of assessment.

CONCLUSION

3D TVS is a cost-effective, non-invasive imaging modality with no complications as compared to hysteroscopy with a high specificity of 99.21% and high NPV (97.69%), should be considered as a first-line investigation tool for infertility work-up and with larger studies further documenting its diagnostic accuracy has a great potential to replace hysteroscopy for women undergoing IVF.

Data availability/data sharing

Corresponding author will provide the data upon reasonable request

Financial support and sponsorship

Nil.

Conflicts of interest

There are no conflicts of interest.

REFERENCES

1. Pundir J, El Toukhy T. Uterine cavity assessment prior to IVF. *Womens Health (Lond)* 2010;6:841-7.
2. Van Voorhis BJ. Ultrasound assessment of the uterus and fallopian tube in infertile women. *Semin Reprod Med* 2008;26:232-40.
3. Rogers PA, Milne BJ, Trounson AO. A model to show human uterine receptivity and embryo viability following ovarian stimulation for *in vitro* fertilization. *J In Vitro Fert Embryo Transf* 1986;3:93-8.
4. Brown SE, Coddington CC, Schnorr J, Toner JP, Gibbons W, Oehninger S. Evaluation of outpatient hysteroscopy, saline infusion hysterosonography, and hysterosalpingography in infertile women: A prospective, randomized study. *Fertil Steril* 2000;74:1029-34.
5. Rama Raju GA, Shashi Kumari G, Krishna KM, Prakash GJ, Madan K. Assessment of uterine cavity by hysteroscopy in assisted reproduction programme and its influence on pregnancy outcome. *Arch Gynecol Obstet* 2006;274:160-4.
6. Loverro G, Nappi L, Vicino M, Carriero C, Vimercati A, Selvaggi L. Uterine cavity assessment in infertile women: Comparison of transvaginal sonography and hysteroscopy. *Eur J Obstet Gynecol Reprod Biol* 2001;100:67-71.
7. Ayida G, Chamberlain P, Barlow D, Kennedy S. Uterine cavity assessment prior to *in vitro* fertilization: Comparison of transvaginal scanning, saline contrast hysterosonography and hysteroscopy. *Ultrasound Obstet Gynecol* 1997;10:59-62.
8. Brunner M, Obruca A, Bauer P, Feichtinger W. Clinical application of volume estimation based on three-dimensional ultrasonography. *Ultrasound Obstet Gynecol* 1995;6:358-61.
9. King DL, King DL Jr., Shao MY. Three-dimensional spatial registration and interactive display of position and orientation of real-time ultrasound images. *J Ultrasound Med* 1990;9:525-32.
10. Maymon R, Herman A, Ariely S, Dreazen E, Buckovsky I, Weinraub Z. Three-dimensional vaginal sonography in obstetrics and gynaecology. *Hum Reprod Update* 2000;6:475-84.
11. McLaren JF. Infertility evaluation. *Obstet Gynecol Clin North Am* 2012;39:453-63.
12. Sylvestre C, Child TJ, Tulandi T, Tan SL. A prospective study to evaluate the efficacy of two- and three-dimensional sonohysterography in women with intrauterine lesions. *Fertil Steril* 2003;79:1222-5.

13. La Sala GB, Blasi I, Gallinelli A, Debbi C, Lopopolo G, Vinci V, *et al.* Diagnostic accuracy of sonohysterography and transvaginal sonography as compared with hysteroscopy and endometrial biopsy: A prospective study. *Minerva Ginecol* 2011;63:421-7.
14. Kupesic S, Kurjak A, Skenderovic S, Bjelos D. Screening for uterine abnormalities by three-dimensional ultrasound improves perinatal outcome. *J Perinat Med* 2002;30:9-17.
15. Midan MF, Eid SM, ElSherbiny AM. Comparative study between three dimensional ultrasonography and office hysteroscopy in infertile women with uterine cavity abnormalities. *Middle East Fertil Soc J* 2017;22:329-32.
16. Apirakviriya C, Rungruxsivorn T, Phupong V, Wisawasukmongchol W. Diagnostic accuracy of 3D-transvaginal ultrasound in detecting uterine cavity abnormalities in infertile patients as compared with hysteroscopy. *Eur J Obstet Gynecol Reprod Biol* 2016;200:24-8.
17. Faivre E, Fernandez H, Deffieux X, Gervaise A, Frydman R, Levailant JM. Accuracy of three-dimensional ultrasonography in differential diagnosis of septate and bicornuate uterus compared with office hysteroscopy and pelvic magnetic resonance imaging. *J Minim Invasive Gynecol* 2012;19:101-6.
18. Mishra VV, Goyal PA, Gondhali RP, Aggrawal RS, Choudhary SD. Uterine cavity assessment prior to *in vitro* fertilization: Comparison of 3D transvaginal ultrasonography accuracy versus office hysteroscopy. *Indian J Obstet Gynecol Res* 2016;3:270.
19. Laganà AS, Ciancimino L, Mancuso A, Chiofalo B, Rizzo P, Triolo O. 3D sonohysterography vs. hysteroscopy: A cross-sectional study for the evaluation of endouterine diseases. *Arch Gynecol Obstet* 2014;290:1173-8.