

Combined Anterolateral Ligament Reconstruction and Capsular Reinforcement in the Skeletally Immature Knee



Neeraj M. Patel, M.D., M.P.H., M.B.S., and Nakul S. Talathi, M.D.

Abstract: Graft failure after anterior cruciate ligament reconstruction remains a challenging complication in the pediatric population. The anterolateral ligament (ALL) contributes to rotational stability, and early evidence in adults suggests that ALL reconstruction may lower the risk of anterior cruciate ligament graft rupture. We present a technique for combined ALL reconstruction and anterolateral capsular reinforcement using iliotibial band autograft in skeletally immature patients. This procedure seeks to provide additional rotational stability in varying degrees of flexion while avoiding the physes and eliminating the need for implants.

Graft failure rates after anterior cruciate ligament (ACL) reconstruction may be as high as 19% in children and adolescents,¹⁻³ with an estimated 6 times greater risk than young athletes tearing the native ACL.⁴ Studies have highlighted age,⁵ female sex,⁶ and early return to sport^{2,7} as significant risk factors for reinjury after primary ACL reconstruction. Sonnery-Cottet et al.⁸ showed that in high-risk patients, including those who are younger than 25 years and play pivoting sports, reconstruction of the anterolateral ligament (ALL) in conjunction with ACL reconstruction lowered the rate of graft rupture and was associated with greater odds of returning to the preinjury level of sport. Biomechanically, the ALL may play an important role in providing rotational stability to the knee,⁹ including improved stability with the pivot-shift test.¹⁰

The literature on ALL reconstruction (ALLR) in children and adolescents is scarce. In fact, Shea et al.^{11,12} reported that the anatomy of the ALL was inconsistent in pediatric cadavers. Regardless, given the promise shown by ALLR in enhancing stability in adults, as well as the well-described high risk of ACL graft failure in children,^{1,2,4,13,14} additional anterolateral reinforcement may be beneficial for some patients in this population.

We describe a technique for combined ALLR and anterolateral capsular reinforcement using iliotibial band (ITB) autograft in children with open physes (Video 1). Incorporating and simplifying aspects of previous techniques, the present method includes the following advantages: use of autograft, adaptability to any age group, no drilling or implant use, relatively small incisions, no risk of convergence with the femoral ACL tunnel, and relatively straightforward conceptual nature of the reconstruction.

From the Division of Orthopaedic Surgery, Ann & Robert H. Lurie Children's Hospital of Chicago, Chicago, Illinois, U.S.A. (N.M.P.); and Department of Orthopaedic Surgery, University of California—Los Angeles Health, Los Angeles, California, U.S.A. (N.S.T.).

The authors report no conflicts of interest in the authorship and publication of this article. Full ICMJE author disclosure forms are available for this article online, as [supplementary material](#).

Received April 14, 2020; accepted July 9, 2020.

Address correspondence to Neeraj M. Patel, M.D., M.P.H., M.B.S., Division of Orthopaedic Surgery, Ann & Robert H. Lurie Children's Hospital of Chicago, 225 E Chicago Ave, Box 69, Chicago, IL 60611, U.S.A. E-mail: neepatel@luriechildrens.org

© 2020 by the Arthroscopy Association of North America. Published by Elsevier. This is an open access article under the CC BY-NC-ND license (<http://creativecommons.org/licenses/by-nc-nd/4.0/>).

2212-6287/20660

<https://doi.org/10.1016/j.eats.2020.07.003>

Surgical Technique

Operative Indications

There is currently little evidence to guide surgical indications for pediatric ALLR with concurrent ACL reconstruction. Given that many of these patients are at increased risk of ACL graft failure because of their young age, concomitant ALLR is typically considered at our institution if any of the following additional criteria are met: knee hyperextension greater than 10°, Beighton-Horan score greater than 4, indicating generalized laxity, grade 2 or higher pivot-shift test result, or revision

ACL reconstruction. In addition, age, sex, and sport played are taken into consideration.

ACL Reconstruction

All patients undergo physal-sparing ACL reconstruction prior to ALLR. We use an all-inside, all-epiphyseal technique based on principles previously described by Lawrence et al.¹⁵ and McCarthy et al.¹⁶ Quadriceps tendon autograft with femoral and tibial suspensory fixation is typically used for ACL reconstruction. The ACL graft is tensioned prior to ALLR.

Graft Harvest

After ACL reconstruction, the distance between the Gerdy tubercle and the lateral epicondyle of the femur is measured. This distance is doubled to approximate the total length of ITB graft that will be required for ALLR, and a small mark is placed on the skin at this point on the lateral thigh. Approximately 8 to 10 cm of graft is typically sufficient for this procedure. If a lateral incision was previously used for ACL reconstruction, this is extended proximally so that it is 2 to 3 cm in length (Fig 1). The skin and subcutaneous tissues are dissected to the level of the ITB. The anterior and posterior borders of the ITB are visualized clearly, and the overlying soft tissues are cleared proximally and distally with an elevator (Fig 2). When the surgeon is exposing the ITB distally, this dissection should proceed in the direction of the Gerdy tubercle. The central 1 cm of the ITB is identified and marked anteriorly and posteriorly. A 10-mm parallel blade is advanced proximally about 2 cm to incise the central centimeter of the ITB (Fig 3). A scalpel or scissors can be used if a parallel blade is unavailable, but care must be taken to maintain adequate graft width during proximal and distal advancement.

A straight osteotome is then advanced along the anterior and posterior ITB incisions up to the length previously marked on the skin. An osteotome is

preferred over a scalpel or scissors to maintain the proper plane of the incisions and avoid accidental graft narrowing proximally. The plane underlying the ITB graft is identified, and care is taken to ensure that the graft is free in this plane as well as anteriorly and posteriorly (Fig 4).

A second, 2-cm longitudinal incision is made just distal to the joint line, centered halfway between the Gerdy tubercle and the fibular head (Fig 1). The overlying soft tissues are cleared so that there is now a plane communicating with the first incision. Once the ITB can be clearly visualized all the way to its attachment at the Gerdy tubercle, the parallel blade is advanced distally from the previous ITB incisions toward the Gerdy tubercle (Fig 5). Care must be taken near the joint line to avoid iatrogenic damage to the underlying joint capsule, meniscus, or cartilage when proceeding with distal graft dissection. The graft length is rechecked by doubling the distance between the Gerdy tubercle and the lateral epicondyle. Once the length is considered sufficient, the graft is detached proximally. The ITB graft is fully freed just distal to the joint line, but its attachment to the Gerdy tubercle is left intact throughout the procedure (Fig 6).

Anterolateral Capsular Reinforcement

With the knee in flexion, the lateral epicondyle is palpated through the proximal incision. Although the femoral attachment of the ALL is the subject of debate, especially in children,^{11,17-21} the most commonly cited attachment point is just posterior and proximal to the lateral epicondyle. Accordingly, this point is identified within the proximal incision, and the overlying soft tissues are carefully dissected. If suspensory fixation was used for all-epiphyseal ACL reconstruction, the cortical button will typically be positioned distal to the physis and somewhat anterior. Therefore, the ALL graft attachment should typically be attached posterior to the button and not proximal to it. Care must be taken during dissection to avoid iatrogenic damage to the perichondral ring near the physis. With longitudinal tension held on the ITB graft, No. 0 nonabsorbable suture is used to stitch the graft to the periosteum distal to the physis and just posterior to the lateral epicondyle (Fig 7). It is important that the knee is in 90° of flexion when this limb of the graft is fixed to the femur to prevent over-tightening it. Fixation of this limb in extension may result in significant tightness and suture failure after the knee is flexed. Once fixed, this limb of the graft now provides reinforcement to the anterolateral joint capsule, especially when the knee is in flexion.

ALL Reconstruction

The midpoint between the Gerdy tubercle and the anterior aspect of the fibular head is identified within the distal incision, just distal to the joint line but proximal to

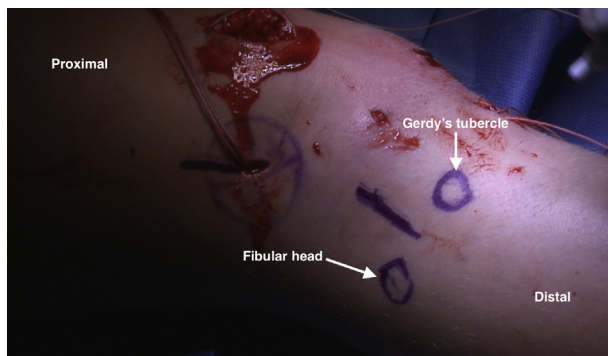


Fig 1. Planned incisions for procedure on right knee, patient in supine position. If a lateral incision was previously used for anterior cruciate ligament reconstruction, this is extended proximally. The distal incision will be halfway between the Gerdy tubercle and the anterior border of the fibular head, just distal to the joint line.

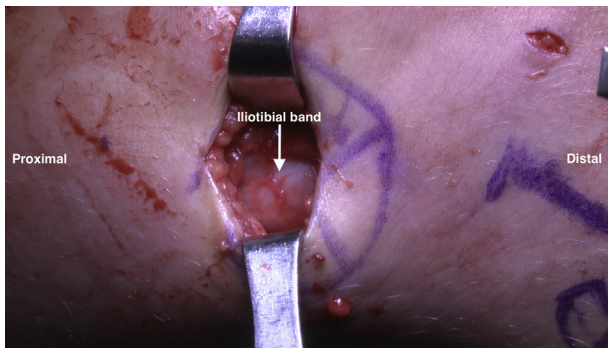


Fig 2. The anterior and posterior borders of the iliotibial band are identified within the proximal incision in a right knee, patient in supine position.

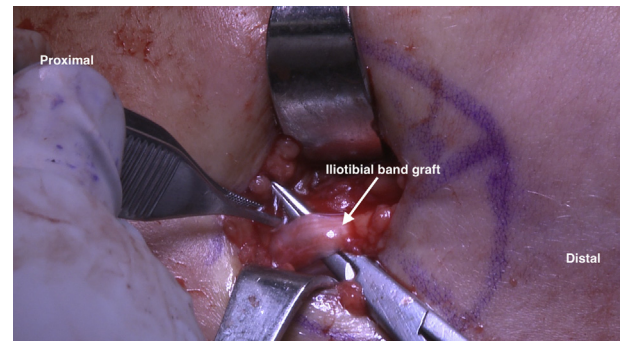


Fig 4. Care is taken to ensure that the strip of iliotibial band is free deep, anterior, and posterior in a right knee, patient in supine position.

the tibial physis. This will be the tibial attachment of the ALL graft, as it has consistently been defined in previous studies.²²⁻²⁵ The soft tissues overlying the periosteum are incised, again with care taken not to injure the perichondral ring near the physis. Once sufficient femoral fixation is confirmed, the knee is brought into full extension and the graft is passed subcutaneously into the distal incision. With longitudinal tension held distally, No. 0 nonabsorbable suture is used to stitch the end of the ITB graft into the epiphyseal periosteum halfway between the Gerdy tubercle and the fibular head (Fig 8). The knee is maintained in full extension with the tibia in neutral rotation as the graft is tensioned and fixed. Care is taken to avoid crossing the physis with the graft. Sufficient tibial fixation is confirmed, and any excess ITB graft is removed. The completed reconstruction now consists of an anterolateral capsular reinforcement extending from the Gerdy tubercle to the distal femur, as well as an ALLR from the distal femur to the proximal tibia (Fig 9). Graft tension and stability are confirmed from 0° to 90° of knee flexion to confirm acceptable motion and graft fixation strength.

In skeletally mature patients, we use a similar technique but with suture anchors for fixation in the femur

and tibia. The incisions are then closed in the standard, layered fashion. Depending on the type of regional anesthesia used, additional local analgesic may be injected around the lateral incisions if additional coverage is required. Pearls and pitfalls of this technique are described in Table 1.

Postoperative Rehabilitation

Concomitant ALLR does not necessitate modification of our typical postoperative ACL rehabilitation protocol. We recommend that surgeons continue to use their preferred postoperative protocol.

Discussion

In this article, we detail an ITB autograft technique for combined anterolateral capsule reinforcement and ALLR in skeletally immature children. The strengths of this technique include use of ITB autograft with no drilling, implant, or allograft requirements. This avoids any convergence with the femoral ACL tunnel, as well as violation of the femoral and tibial physes. Furthermore, this technique can be performed through 2 relatively small incisions and is easily adjusted for skeletally mature patients.

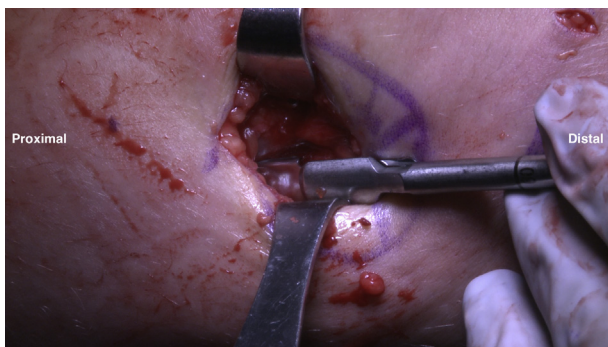


Fig 3. A 10-mm parallel blade is used to incise the central centimeter of the iliotibial band within the proximal incision in a right knee, patient in supine position. These anterior and posterior incisions in the iliotibial band are then extended proximally, as shown here.

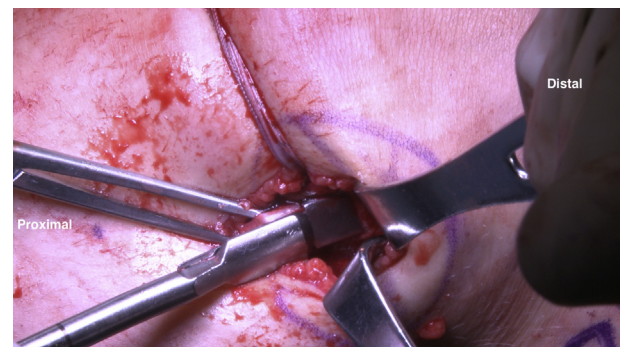


Fig 5. The previous incisions through the central centimeter of the iliotibial band are extended distally toward the Gerdy tubercle in a right knee, patient in supine position. Care must be taken near the joint line to avoid inadvertent damage to the capsule or underlying structures.

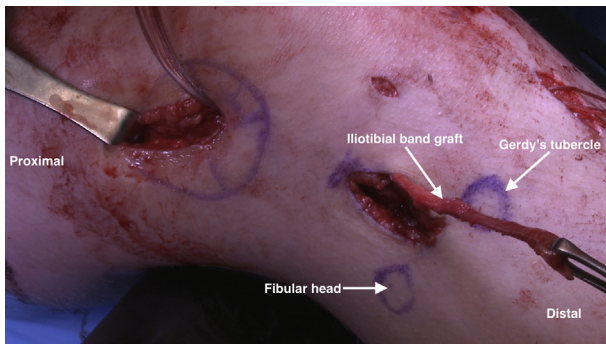


Fig 6. The iliotibial band graft is detached proximally and freed just distal to the joint line but remains attached to the Gerdy tubercle at all times, as shown in a right knee, patient in supine position.

Although the recent interest in the ALL has resulted in several biomechanical,^{9,10,26} anatomic,^{27,28} and outcome studies in the adult literature,^{8,29} the role and anatomy of this ligament in children are less clear. Shea et al.¹² studied 8 pediatric cadavers younger than 10 years and were able to identify the ALL in only 1 specimen. The same authors then evaluated 14 older pediatric cadavers and identified the ALL in 9, suggesting that the ALL may develop at an older age as increased physiological stresses are placed on the knee.¹¹ In a biomechanical study, Trentacosta et al.³⁰ compared stability after performing all-epiphyseal ACL reconstruction with ALLR with that after the modified Macintosh procedure. The modified Macintosh procedure restored rotational stability closer to normal values at most flexion angles, whereas the all-epiphyseal ACL reconstruction with ALLR improved rotational stability at lower flexion angles, but not at 60° and 90°. However, it is important to note that these experiments were conducted on adult cadaveric specimens and the clinical relevance after graft incorporation and rehabilitation remains to be seen. Nonetheless, such concerns about stability at higher flexion angles

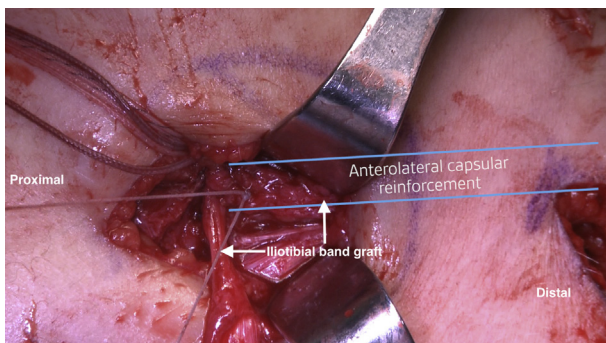


Fig 7. With the right knee in 90° of flexion, patient in supine position, and longitudinal tension held on the graft, the graft is sutured to the periosteum just distal to the physis and posterior to the lateral epicondyle. Once fixed, this limb of the graft provides reinforcement to the anterolateral capsule.

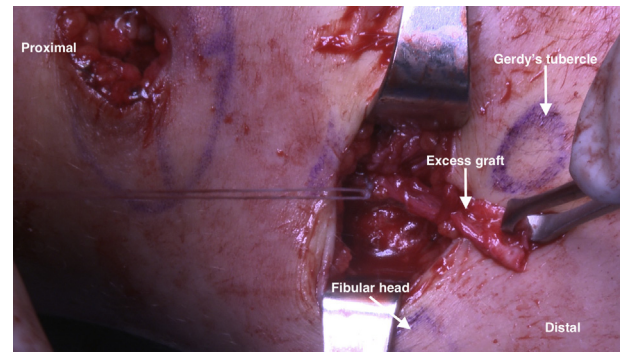


Fig 8. The graft is passed subcutaneously into the distal incision in a right knee, patient in supine position. With the knee in full extension and the tibia in neutral rotation, longitudinal tension is held on the graft, and the graft is sutured to the tibial periosteum just proximal to the physis and halfway between the Gerdy tubercle and the fibular head.

influenced the current technique. The first limb of the graft in this method—the capsular reinforcement spanning between the Gerdy tubercle and the distal femur—is tensioned and fixed in 90° of flexion to provide enhanced stability at higher flexion angles. Given the early clinical evidence of the benefits of ALLR and lateral extra-articular tenodesis procedures in young populations,^{8,31} as well as the known high risk of graft failure in children after ACL reconstruction, select pediatric patients may benefit from ALLR.

There are few clinical data on ALLR in skeletally immature children. Kocher et al.³² modified the Macintosh technique to develop a combined intra- and extra-articular ACL reconstruction method using the ITB. Although this technique does not anatomically reconstruct the ACL or ALL, it shares aspects of both and provides a good option in this challenging population. At long-term follow-up of 237 subjects, Kocher et al.³³ found that this technique resulted in a graft rupture rate of 6.6% and improved patient-reported outcome scores compared with preoperative values.

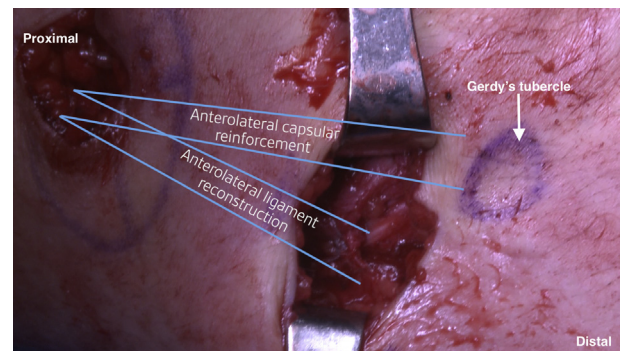


Fig 9. Patient in supine position. The final reconstruction, shown in a right knee, consists of an anterolateral capsular reinforcement extending from the Gerdy tubercle to the distal femur, as well as an anterolateral ligament reconstruction from the distal femur to the proximal tibia.

Table 1. Pearls and Pitfalls**Pearls**

The ACL graft should be tensioned prior to the ALL to minimize anterolateral overconstraint.

The surgeon should ensure that the length of the ITB graft is sufficient (usually about 8 cm but could be more or less depending on patient size). This is marked before cutting.

Although a 2-incision technique may be preferred for esthetic reasons, a single, longer incision can be used to ensure optimal visualization if needed.

When the first limb of the graft is being attached to the distal femur (capsular reinforcement), the knee should be flexed to 90°.

The knee is kept in extension with the tibia in neutral rotation when the second limb of the graft (ALL reconstruction) is fixed to the proximal tibia.

When modifying this technique for skeletally mature patients and using suture anchors for fixation, the surgeon should perform drilling for femoral fixation (posterior and proximal to the lateral epicondyle) while aiming slightly anterior and proximal to avoid ACL tunnel convergence.

Pitfalls

The surgeon should consider using an osteotome to continue the incisions along the anterior and posterior borders of the ITB graft. This allows the incision to stay in the original plane and trajectory. Use of a scalpel or scissors could lead to accidental narrowing of the graft proximally. Care should be taken to incise only the ITB when developing the graft. Dissecting too deep near the joint line risks iatrogenic damage to the capsule or even the underlying meniscus and cartilage. We recommend using scissors or a scalpel when developing the graft near the joint line to avoid this risk.

The surgeon should avoid aggressive dissection around the perichondral ring near the physes.

ACL, anterior cruciate ligament; ALL, anterolateral ligament; ITB, iliotibial band.

One possible factor in these promising results is that the extra-articular limb of the reconstruction is a lateral tenodesis similar to an ALLR. However, there is no strong evidence comparing this technique with others.

Although our technique has similarities to previously described ALLR techniques, there are differences as well. Whereas most previous methods used hamstring autograft or allograft,²²⁻²⁵ we use an ITB autograft in a manner similar to that described by Ferretti et al.³⁴ Among all published ALLR techniques, there remains significant variation in the degree of knee flexion required when tensioning and fixing the graft. Previous authors have reported 0° of flexion,³⁵⁻³⁷ 30°,^{22,24,38} 45° to 60°,³⁹ and 60° to 90°.²³ Both of the published outcome studies placed the knee in 20° of flexion when fixing the ALL graft.^{8,29} We typically flex the knee to 90° for tensioning of the first limb (capsular reinforcement) and extend the knee during tensioning and fixation of the ALL limb. Schon et al.²⁸ examined knee kinematics after ALL graft fixation at flexion angles of 0°, 15°, 30°, 45°, 60°, 75°, and 90° in cadaveric knees and found no significant differences between fixation angles. Additional evidence is required to determine the optimal flexion angle of the knee when tensioning and fixing the graft.

Of note, there are no published outcome data on this specific ALLR technique, nor are there biomechanical studies that have evaluated the effect on knee stability between this technique and other techniques. We are currently gathering follow-up data in our pediatric population, although none were available at the time of this writing. Although our experience with this technique has been favorable thus far, potential risks and limitations may exist. For example, inadequate analgesia along the lateral thigh and knee may result in increased post-operative pain. This, along with the presence of a reconstruction of a ligament additional to the ACL, could lead to difficulties with early motion in some patients. For these

reasons, we recommend local analgesia around the lateral wounds and emphasize the importance of early motion. Overconstraint of the knee is another potential concern with this technique and similar techniques, although there is little recent literature on the clinical relevance of this concern in the setting of modern, anatomic ACL reconstruction. We recommend tensioning the ACL graft prior to performing this additional procedure and maintaining the tibia in neutral rotation when tensioning the ALL. Long-term clinical outcome studies will be crucial in determining the role of ALLR in children and adolescents.

In conclusion, we describe a relatively straightforward physal-sparing technique for combined capsular reinforcement and reconstruction of the anterolateral ligament in skeletally immature patients. The procedure uses an ITB autograft and avoids the need for drilling, implants, or allograft while sparing the physes. Despite the variable anatomy of the ALL in children, this technique seeks to provide additional rotational stability at varying degrees of knee flexion, making it promising for young patients with rotational instability and generalized laxity who participate in high-risk sports.

Acknowledgment

The authors acknowledge Mr. Jesse Arsenau for his expertise in recording and editing the video associated with this article.

References

1. DeFrancesco CJ, Storey EP, Flynn JM, Ganley TJ. Pediatric ACL reconstruction and return to the operating room: Revision is less than half of the story. *J Pediatr Orthop* 2019;39:516-520.
2. Dekker TJ, Godin JA, Dale KM, Garrett WE, Taylor DC, Riboh JC. Return to sport after pediatric anterior cruciate ligament reconstruction and its effect on subsequent

- anterior cruciate ligament injury. *J Bone Joint Surg Am* 2017;99:897-904.
3. Patel NM, Bram JT, Talathi NS, DeFrancesco CJ, Lawrence JTR, Ganley TJ. Which children are at risk for contralateral anterior cruciate ligament injury after ipsilateral reconstruction? *J Pediatr Orthop* 2020;40:162-167.
 4. Webster KE, Feller JA, Leigh WB, Richmond AK. Younger patients are at increased risk for graft rupture and contralateral injury after anterior cruciate ligament reconstruction. *Am J Sports Med* 2014;42:641-647.
 5. Kaeding CC, Pedroza AD, Reinke EK, Huston LJ, Spindler KP. Risk factors and predictors of subsequent ACL injury in either knee after ACL reconstruction: Prospective analysis of 2488 primary ACL reconstructions from the MOON cohort. *Am J Sports Med* 2015;43:1583-1590.
 6. Paterno MV, Huang B, Thomas S, Hewett TE, Schmitt LC. Clinical factors that predict a second ACL injury after ACL reconstruction and return to sport: Preliminary development of a clinical decision algorithm. *Orthop J Sports Med* 2017;5:2325967117745279.
 7. Paterno MV, Rauh MJ, Schmitt LC, Ford KR, Hewett TE. Incidence of second ACL injuries 2 Years after primary ACL reconstruction and return to sport. *Am J Sports Med* 2014;42:1567-1573.
 8. Sonnery-Cottet B, Saithna A, Cavalier M, et al. Anterolateral ligament reconstruction is associated with significantly reduced ACL graft rupture rates at a minimum follow-up of 2 years: A prospective comparative study of 502 patients from the SANTI Study Group. *Am J Sports Med* 2017;45:1547-1557.
 9. Spencer L, Burkhart TA, Tran MN, et al. Biomechanical analysis of simulated clinical testing and reconstruction of the anterolateral ligament of the knee. *Am J Sports Med* 2015;43:2189-2197.
 10. Nitri M, Rasmussen MT, Williams BT, et al. An in vitro robotic assessment of the anterolateral ligament, part 2: Anterolateral ligament reconstruction combined with anterior cruciate ligament reconstruction. *Am J Sports Med* 2016;44:593-601.
 11. Shea KG, Milewski MD, Cannamela PC, et al. Anterolateral ligament of the knee shows variable anatomy in pediatric specimens. *Clin Orthop Relat Res* 2017;475:1583-1591.
 12. Shea KG, Polousky JD, Jacobs JC Jr, Yen YM, Ganley TJ. The anterolateral ligament of the knee: An inconsistent finding in pediatric cadaveric specimens. *J Pediatr Orthop* 2016;36:e51-e54.
 13. Morgan MD, Salmon LJ, Waller A, Roe JP, Pinczewski LA. Fifteen-year survival of endoscopic anterior cruciate ligament reconstruction in patients aged 18 years and younger. *Am J Sports Med* 2016;44:384-392.
 14. Wiggins AJ, Grandhi RK, Schneider DK, Stanfield D, Webster KE, Myer GD. Risk of secondary injury in younger athletes after anterior cruciate ligament reconstruction: A systematic review and meta-analysis. *Am J Sports Med* 2016;44:1861-1876.
 15. Lawrence JT, Bowers AL, Belding J, Cody SR, Ganley TJ. All-epiphyseal anterior cruciate ligament reconstruction in skeletally immature patients. *Clin Orthop Relat Res* 2010;468:1971-1977.
 16. McCarthy MM, Graziano J, Green DW, Cordasco FA. All-epiphyseal, all-inside anterior cruciate ligament reconstruction technique for skeletally immature patients. *Arthrosc Tech* 2012;1:e231-e239.
 17. Daggett M, Ockuly AC, Cullen M, et al. Femoral origin of the anterolateral ligament: An anatomic analysis. *Arthroscopy* 2016;32:835-841.
 18. Dodds AL, Halewood C, Gupte CM, Williams A, Amis AA. The anterolateral ligament: Anatomy, length changes and association with the Segond fracture. *Bone Joint J* 2014;96-b:325-331.
 19. Helito CP, Demange MK, Bonadio MB, et al. Anatomy and histology of the knee anterolateral ligament. *Orthop J Sports Med* 2013;1:2325967113513546.
 20. Helito CP, Helito PV, Bonadio MB, et al. Correlation of magnetic resonance imaging with knee anterolateral ligament anatomy: A cadaveric study. *Orthop J Sports Med* 2015;3:2325967115621024.
 21. Kennedy MI, Claes S, Fuso FA, et al. The anterolateral ligament: An anatomic, radiographic, and biomechanical analysis. *Am J Sports Med* 2015;43:1606-1615.
 22. Chahla J, Menge TJ, Mitchell JJ, Dean CS, LaPrade RF. Anterolateral ligament reconstruction technique: An anatomic-based approach. *Arthrosc Tech* 2016;5:e453-e457.
 23. Helito CP, Bonadio MB, Gobbi RG, et al. Combined intra- and extra-articular reconstruction of the anterior cruciate ligament: The reconstruction of the knee anterolateral ligament. *Arthrosc Tech* 2015;4:e239-e244.
 24. Smith JO, Yasen SK, Lord B, Wilson AJ. Combined anterolateral ligament and anatomic anterior cruciate ligament reconstruction of the knee. *Knee Surg Sports Traumatol Arthrosc* 2015;23:3151-3156.
 25. Sonnery-Cottet B, Daggett M, Helito CP, Fayard JM, Thaunat M. Combined anterior cruciate ligament and anterolateral ligament reconstruction. *Arthrosc Tech* 2016;5:e1253-e1259.
 26. Musahl V, Getgood A, Neyret P, et al. Contributions of the anterolateral complex and the anterolateral ligament to rotatory knee stability in the setting of ACL injury: A roundtable discussion. *Knee Surg Sports Traumatol Arthrosc* 2017;25:997-1008.
 27. DePhillipo NN, Cinque ME, Chahla J, Geeslin AG, LaPrade RF. Anterolateral ligament reconstruction techniques, biomechanics, and clinical outcomes: A systematic review. *Arthroscopy* 2017;33:1575-1583.
 28. Schon JM, Moatshe G, Brady AW, et al. Anatomic anterolateral ligament reconstruction of the knee leads to overconstraint at any fixation angle. *Am J Sports Med* 2016;44:2546-2556.
 29. Sonnery-Cottet B, Thaunat M, Freychet B, Pupim BH, Murphy CG, Claes S. Outcome of a combined anterior cruciate ligament and anterolateral ligament reconstruction technique with a minimum 2-year follow-up. *Am J Sports Med* 2015;43:1598-1605.
 30. Trentacosta N, Pace JL, Metzger M, et al. Biomechanical evaluation of pediatric anterior cruciate ligament (ACL) reconstruction techniques with and without the anterolateral ligament (ALL). *J Pediatr Orthop* 2020;40:8-16.
 31. Getgood AMJ, Bryant DM, Litchfield R, et al. Lateral extra-articular tenodesis reduces failure of hamstring

- tendon autograft anterior cruciate ligament reconstruction: 2-Year outcomes from the STABILITY study randomized clinical trial. *Am J Sports Med* 2020;48:285-297.
32. Kocher MS, Garg S, Micheli LJ. Physeal sparing reconstruction of the anterior cruciate ligament in skeletally immature prepubescent children and adolescents. Surgical technique. *J Bone Joint Surg Am* 2006;88:283-293 (suppl 1, pt 2).
 33. Kocher MS, Heyworth BE, Fabricant PD, Tepolt FA, Micheli LJ. Outcomes of physeal-sparing ACL reconstruction with iliotibial band autograft in skeletally immature prepubescent children. *J Bone Joint Surg Am* 2018;100:1087-1094.
 34. Ferretti A, Monaco E, Fabbri M, Mazza D, De Carli A. The fascia lata anterolateral tenodesis technique. *Arthrosc Tech* 2017;6:e81-e86.
 35. Mediavilla I, Aramberri M, Tiso G, Murillo-Gonzalez JA. Combined double bundle anterior cruciate ligament reconstruction and anterolateral ligament reconstruction. *Arthrosc Tech* 2018;7:e881-e886.
 36. Monaco E, Mazza D, Redler A, Drogo P, Wolf MR, Ferretti A. Anterolateral ligament repair augmented with suture tape in acute anterior cruciate ligament reconstruction. *Arthrosc Tech* 2019;8:e369-e373.
 37. Saithna A, Thauinat M, Delaloye JR, Ouanezar H, Fayard JM, Sonnery-Cottet B. Combined ACL and anterolateral ligament reconstruction. *JBJS Essent Surg Tech* 2018;8:e2.
 38. Wagih AM, Elguindy AM. Percutaneous reconstruction of the anterolateral ligament of the knee with a polyester tape. *Arthrosc Tech* 2016;5:e691-e697.
 39. Ferreira Mde C, Zidan FF, Miduati FB, Fortuna CC, Mizutani BM, Abdalla RJ. Reconstruction of anterior cruciate ligament and anterolateral ligament using interlinked hamstrings—Technical note. *Rev Bras Ortop* 2016;51:466-470.