

# Cadaveric Study of Mode of Termination of Gonadal Veins: Implications for Procedures Utilizing Terminal Ends of Gonadal Veins as Entry Portals

Rekha Lalwani, Sunita A. Athavale, Ketu Chauhan<sup>1</sup>, Guljari Lal Nigam<sup>1</sup>, C. S. Ramesh Babu<sup>2</sup>, Sheetal Kotgirwar

Department of Anatomy, All India Institute of Medical Sciences, Bhopal, Madhya Pradesh, <sup>1</sup>Department of Anatomy, LLRM Medical College, Meerut, <sup>2</sup>Department of Anatomy, Muzaffarnagar Medical College, Muzaffarnagar, Uttar Pradesh, India

## Abstract

**Context:** The terminal ends of gonadal veins act as an entry portal in gonadal embolization procedures used for treating varicocele in males and pelvic congestion disease in females. Here, we studied the modes of termination of gonadal veins in adult cadavers. **Materials and Methods:** Thirty-five adult formalin-fixed cadavers (seventy sides) were studied over a period of 4 years. The modes of termination of gonadal veins were observed under the following study variables: (a) number, (b) locale of termination, and (c) termination angle. **Results:** Variations in study parameters were observed in eight sides of seven cadavers (seven unilateral and one bilateral). Double veins at termination were observed in six cadavers; anomalous termination was observed in three cadavers. Angle of termination differed from normal in 3 cadavers. In one of these cadavers, the left ovarian vein drained into the left suprarenal vein. **Conclusion:** Duplication of terminal ends, anomalous drainage site, and varied angles of termination call for caution to ensure the success of procedures, which use terminal ends of gonadal veins as entry portals.

**Keywords:** Inferior vena cava, ovarian vein, renal vein, suprarenal vein, testicular vein

## INTRODUCTION

There is renewed interest in gonadal venous anatomy due to its potential use for renal vein lengthening in live donor kidney transplantation.<sup>[1,2]</sup> Gonadal veins also serve as an entry portal for newer techniques used for treating varicocele such as percutaneous retrograde varicocele occlusion and laparoscopic varicolectomy in males and pelvic congestion disease in females.<sup>[3,4]</sup> While phlebography visualization of vessels precedes such procedures, Letcher *et al.*<sup>[5]</sup> observed that gonadal phlebography is technically not feasible in some cases and it did not correlate exactly with operative findings.

Some isolated reports documenting gonadal vein anatomy<sup>[6-17]</sup> indicate the frequent occurrence of variations, which are not adequately described in the standard texts of anatomy.<sup>[18,19]</sup> Few anatomical studies available have documented variations in western<sup>[5,20-22]</sup> and black<sup>[23]</sup> population. However, such a study representing the Indian population is lacking. Hence, we aimed to observe the modes of termination of gonadal veins in adult cadavers of the Indian origin.

## MATERIALS AND METHODS

Thirty-five adult formalin-fixed cadavers (23 male and 12 female) from the collection of the department of anatomy, over period of 4 years were used in this study. The abdominal and peritoneal cavity was opened by standard anatomical dissection. After the removal of gut and mesentery from the abdominal cavity, the retroperitoneum and gonadal veins were dissected and were carefully cleaned. The mode of termination of gonadal veins (within 1 cm of termination) was observed under the following study variables: (a) number, (b) locale of termination, and (c) termination angle, and the variations were documented.

**Address for correspondence:** Dr. Rekha Lalwani, Department of Anatomy, All India Institute of Medical Sciences, Saket Nagar, Bhopal - 462 020, Madhya Pradesh, India. E-mail: rekha.anatomy@aiimsbhopal.edu.in

This is an open access article distributed under the terms of the Creative Commons Attribution-NonCommercial-ShareAlike 3.0 License, which allows others to remix, tweak, and build upon the work non-commercially, as long as the author is credited and the new creations are licensed under the identical terms.

**For reprints contact:** reprints@medknow.com

**How to cite this article:** Lalwani R, Athavale SA, Chauhan K, Nigam GL, Babu CS, Kotgirwar S. Cadaveric study of mode of termination of gonadal veins: Implications for procedures utilizing terminal ends of gonadal veins as entry portals. *J Nat Sc Biol Med* 2017;8:210-2.

### Access this article online

Quick Response Code:



Website:  
www.jnsbm.org

DOI:  
10.4103/0976-9668.210005

## RESULTS

Variations in study parameters were observed in eight sides of seven cadavers (seven unilateral and one bilateral).

**Number:** The termination of the vein was mostly as a single vein. Double termination was observed in seven cadavers (10% of cases). The testicular vein duplicated before termination in six cases (one right and five left). Ovarian vein also showed duplication in single case on the left side.

**Locale of termination** was mostly into the inferior vena cava (IVC) on the right side and into the renal vein on the left side. Anomalous drainage was observed in only three cases:

- i. Termination of the right testicular vein in right renal vein [Figure 1]
- ii. Termination of the left testicular vein into IVC [Figure 2]. Such anomalous drainage occurred in cases of double veins only
- iii. In one case (left side), the ovarian vein ascended in front of the left renal vein to join the left suprarenal vein [Figure 3].

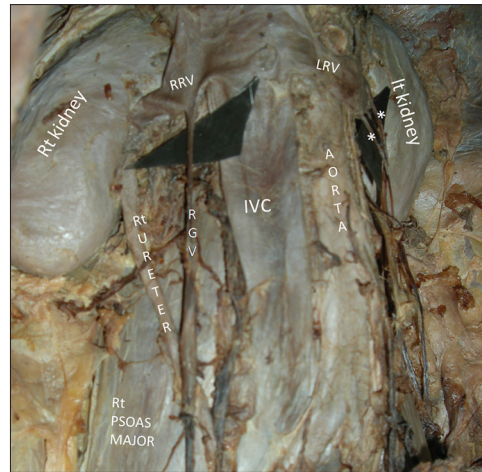
Angle of termination was observed to be acute on the right side in all cases and perpendicular on the left side except in three cadavers where it was variable. The following variations were observed:

- i. Left testicular vein joined IVC at an acute angle [Figure 2]
- ii. Left testicular vein (double at termination) ran parallel to the left renal vein and draining at its anterior and posterior surface, respectively [Figure 4]
- iii. Left ovarian vein ascended anterior to the left renal vein to drain in left suprarenal vein just before the latter joined the left renal vein [Figure 3].

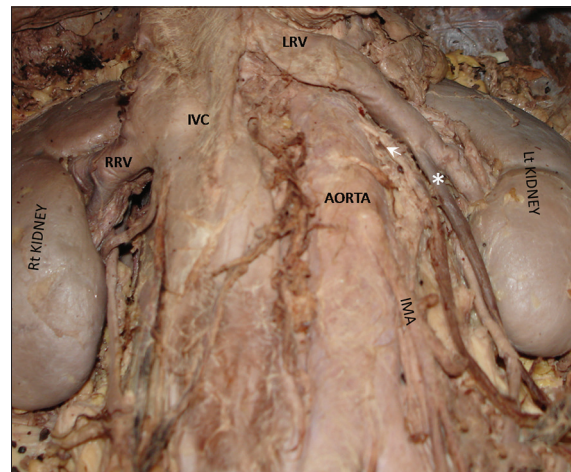
## DISCUSSION

Venous variations are a rule rather than exception, and veins are the most variable structures in the human body. In dissection-based studies, single testicular vein termination is reported in 78–85% of cases;<sup>[5,21]</sup> however, we observed single testicular vein termination in 90% of the cadavers studied. This difference may be due to inclusion of ovarian veins in the present study, which are relatively less variable. Interestingly, double termination of gonadal veins was reported in 12.9% of cases in a computed tomography-based study,<sup>[24]</sup> which is comparable to our observations.

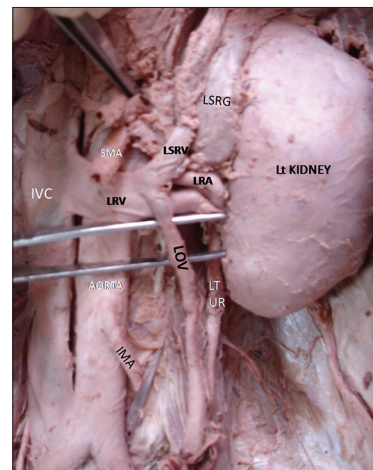
The locale of termination of testicular veins was also variable in some cases. Such variability was observed to be double termination. Several case reports have also documented drainage of the right gonadal vein into right renal vein<sup>[6,7,25]</sup> and termination of left gonadal (ovarian) vein into IVC.<sup>[10]</sup> Interestingly, termination of the left gonadal (ovarian) vein in left suprarenal vein as observed in the present study is not described before. In a previous report, right ovarian vein draining into right renal vein



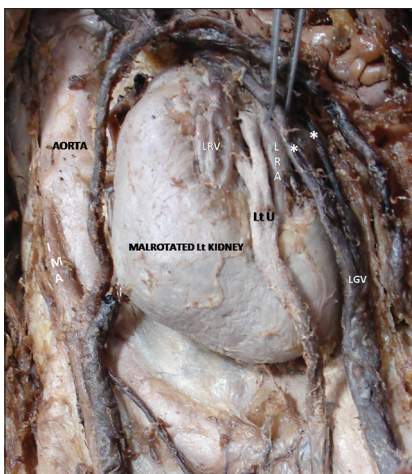
**Figure 1:** Two left gonadal veins (\*) draining in left renal vein and right gonadal vein anomalously terminating in right renal vein, IVC = inferior vena cava



**Figure 2:** Two left gonadal veins (and \*), one of them (\*) is terminating in left renal vein and another () in inferior vena cava. RRV = right renal vein; IMA = inferior mesenteric artery



**Figure 3:** Left ovarian vein draining at the terminal part of the left suprarenal vein. LRA = left renal artery; LRV = left renal vein; SMA = superior mesenteric artery; IMA = inferior mesenteric artery; LSRG = left suprarenal gland; LT UR = left ureter



**Figure 4:** Malrotation of the left kidney (hilum directed toward lateral side) showing two left gonadal veins depicted by \* draining into left renal vein on its anterior and posterior surfaces. LRA = left renal artery; Lt U = left ureter; IMA = inferior mesenteric artery

instead of IVC was observed in 10% of cases;<sup>[26]</sup> however, we did not find any anomalous drainage in ovarian veins on the right side.

Anatomical variations in gonadal vein terminations and its implications to clinical procedures have been emphasized during presurgical evaluation of varicocele cases and were such variations lead to poor treatment outcomes.<sup>[19]</sup> More recently, percutaneous embolization techniques for treatment of varicocele are also performed. In this, the right femoral vein is punctured to insert an angiocatheter to gain access to the internal spermatic vein via the IVC and the left renal vein. Although widely used, this technique has high unperformable rates (8–30%) due to the venous anatomical variations leading to difficulties in gaining proper venous access.<sup>[3]</sup> Hence, a study of anatomical variations in gonadal veins in different population groups is justified and necessary to improve the success of clinical procedures involving access to these veins. Specifically, in recent times, utility of gonadal veins for lengthening short renal vessels in cases of live donor transplant is also reported.<sup>[1,2]</sup>

## CONCLUSION

We report here the variations in terminal ends of gonadal veins in the Indian population. The variations were observed in about 11% of cases with preponderance on the left side. Testicular veins were relatively more variable as compared to ovarian veins. We believe our observations will be useful to radiologist, urologist, and urosurgeons for planning of operative procedures and to decrease the rate of failures especially in cases of varicocele.

## Financial support and sponsorship

Nil.

## Conflicts of interest

There are no conflicts of interest.

## REFERENCES

- Feng JY, Huang CB, Fan MQ, Wang PX, Xiao Y, Zhang GF. Renal vein lengthening using gonadal vein reduces surgical difficulty in living-donor kidney transplantation. *World J Surg* 2012;36:468-72.
- He B, Mou L, Mitchell A, Delriviere L. Meticulous use of techniques for reconstruction of multiple renal arteries in live donor kidney transplantation. *Transplant Proc* 2013;45:1396-8.
- Chan P. Management options of varicoceles. *Indian J Urol* 2011;27:65-73.
- Bittles MA, Hoffer EKZW. Gonadal vein embolization: Treatment of varicocele and pelvic congestion syndrome. *Semin Intervent Radiol* 2008;25:261-70.
- Lechter A, Lopez G, Martinez C, Camacho J. Anatomy of the gonadal veins: A reappraisal. *Surgery* 1991;109:735-9.
- Tubbs RS, Salter EG, Oakes WJ. Unusual drainage of the testicular veins. *Clin Anat* 2005;18:536-9.
- Biswas S, Chattopadhyay JC, Panicker H, Anbalagan J, Ghosh SK. Variations in renal and testicular veins – A case report. *J Anat Soc India* 2006;55:69-71.
- Kyuchukov NH, Stilyanka YD. Variations of the bilateral testicular veins. *J Biomed Clin Res* 2009;2:176-8.
- Rosalino UA, Latorre GC, Pinto AC, Toscano MP. Uncommon drainage of the gonadal vein: Case report. *J Morphol Sci* 2011;28:135-6.
- Paraskevas GK, Ioannidis O, Natsis K, Martoglou S. Abnormal bilateral drainage of testicular veins: Embryological aspects and surgical application. *Rom J Morphol Embryol* 2012;53:635-8.
- Sharma P, Salwan SK. Anomalous right testicular artery and vein: Embryologic explanation and clinical implications. *J Clin Diagn Res* 2011;5:1631-3.
- Vijisha P, Muganthan N, Devi JR, Anbalagan J. A study of renal vein and gonadal vein variations. *NJCA* 2012;1:125-8.
- Diwan Y, Singal R, Diwan D, Goyal S, Singal S, Kapil M. Bilateral variations of testicular vessels: Embryological background and clinical implications. *JBCRS* 2013;2:60-2.
- Nayak BS, Rao KM, Shetty SD, Sirasanagandla SR, Kumar N, Guru A. Terminal bifurcation of the right testicular vein and left testicular arterio-venous anastomosis. *Kathmandu Univ Med J (KUMJ)* 2013;11:168-70.
- Gupta R, Gupta A, Aggarwal N. Variations of gonadal veins: Embryological prospective and clinical significance. *J Clin Diagn Res* 2015;9:AC08-10.
- Shankar VV, Das S. Unilateral variation of the renal vein and testicular vein-a case report. *Int J Curr Res Rev* 2016;8:38-41.
- Shakya P, Das B, Shakya NK, Mohanty C, Das BK. variation in the drainage of gonadal vein. *Peoples J Sci Res* 2016;9:57-60.
- Standing S, Ellis H, Healy JC, Jhonson D, Williams A, Collins P, *et al.* *Gray's Anatomy – The Anatomical Basis of Clinical Practice*. 39<sup>th</sup> ed. London: Churchill Livingstone; 2005. p. 1307-23.
- Hollinshead WH. *Anatomy for Surgeons: The Thorax Abdomen and Pelvis*. 2<sup>nd</sup> ed., Vol. 1. New York: Harper and Row; 1971. p. 566-7.
- Comhaire F, Kunnen M, Nahoum C. Radiological anatomy of the internal spermatic vein (s) in 200 retrograde venograms. *Int J Androl* 1981;4:379-87.
- Favorito LA, Costa WS, Sampaio FJ. Applied anatomic study of testicular veins in adult cadavers and in human fetuses. *Int Braz J Urol* 2007;33:176-80.
- Pieri S, Agresti P, Fiocca G, Regine G. Phlebographic classification of anatomic variants in the right internal spermatic vein confluence. *Radiol Med* 2006;111:551-61.
- Asala S, Chaudhary SC, Masumbuko-Kahamba N, Bidmos M. Anatomical variations in the human testicular blood vessels. *Ann Anat* 2001;183:545-9.
- Kara T, Younes M, Erol B, Karcaaltincaba M. Evaluation of testicular vein anatomy with multidetector computed tomography. *Surg Radiol Anat* 2012;34:341-5.
- Jetti R, Jevoor P, Vollala VR, Potu BK, Ravishankar M, Virupaxi R. Multiple variations of the urogenital vascular system in a single cadaver: A case report. *Cases J* 2008;1:344.
- Koc Z, Ulusan S, Oguzkurt L. Right ovarian vein drainage variant: Is there a relationship with pelvic varices? *Eur J Radiol* 2006;59:465-71.