

# A comparison of preincisional and postincisional ultrasound guided transversus abdominis plane block

Emy Ambooken, Joe John Chirayath, P. Raghavan

Department of Anesthesiology, Amala Institute Of Medical Sciences, Kerala, India

## Abstract

**Background and Aims:** Transversus abdominis plane blocks are part of the multimodal analgesia used for lower abdominal surgeries. Our aim of this study was to compare the analgesic efficacy of preincisional and postincisional TAP blocks in patients undergoing total abdominal hysterectomies.

**Material and Methods:** 54 American Society of Anesthesiologists physical status I and II patients aged between 30 and 60 years who underwent a total abdominal hysterectomy under spinal anesthesia in our hospital were chosen for the study. Alternate patients satisfying the inclusion criteria were either given a preincisional or postincisional transversus abdominis plane block bilaterally. Postoperatively, the numeric pain intensity scale was observed, along with nausea, vomiting, and sedation scores.

**Results:** Pain scores were significantly lower ( $P < 0.05$ ) in the preincisional TAP block group from the 2<sup>nd</sup> postoperative hour onwards till 12 h, and thereafter it was comparable between both the groups. The total morphine requirement was significantly less in the preincisional TAP group ( $P$ -value 0.001). Also, the mean time to the first request for morphine was significantly longer in patients belonging to the preincisional TAP block group ( $P$ -value of 0.002). There were no significant differences in the sedation scores postoperatively, except at the 4<sup>th</sup> hour, where it was significantly higher ( $P$ -value of 0.024) in the postincisional TAP group. Post operative nausea and vomiting was significantly higher and so the dose of the antiemetic used was also observed to be more in the postincisional TAP block group.

**Conclusion:** Preincisional TAP blocks are more effective than postincisional ones with better analgesia and lesser side effects, for total abdominal hysterectomies.

**Keywords:** Multimodal analgesia, postincisional transversus abdominis plane block, preincisional transversus abdominis plane block, total abdominal hysterectomy

## Introduction

Total abdominal hysterectomy is a common gynecological procedure that is associated with significant postoperative pain and discomfort.<sup>[1]</sup> The pain experienced by patients after abdominal surgery is mainly from the anterior abdominal wall incision. Postoperative analgesia after surgery is usually provided by systemic opioids, nonsteroidal anti-inflammatory

drugs and/or central neuraxial blocks with or without opioids. Other effective techniques include transversus abdominis plane (TAP) blocks and paravertebral blocks.<sup>[2,3]</sup>

For postoperative pain relief, ultrasound guided TAP block could be given either before the surgical incision or after the surgery. However, to date, information regarding their comparative efficacy is sparse. The purpose of this prospective cohort study was to compare the efficacy of pre versus post incisional ultrasound guided TAP block in providing postoperative analgesia. We

Address for correspondence: Dr. Joe John Chirayath,  
Department of Anesthesiology, Amala Institute of Medical Sciences,  
Thrissur - 680555, Kerala, India.  
E-mail: joechirayath@yahoo.com

### Access this article online

Quick Response Code:



Website:  
www.joacp.org

DOI:  
10.4103/joacp.JOACP\_283\_19

This is an open access journal, and articles are distributed under the terms of the Creative Commons Attribution-NonCommercial-ShareAlike 4.0 License, which allows others to remix, tweak, and build upon the work non-commercially, as long as appropriate credit is given and the new creations are licensed under the identical terms.

For reprints contact: WKHLRPMedknow\_reprints@wolterskluwer.com

**How to cite this article:** Ambooken E, Chirayath JJ, Raghavan P. A comparison of preincisional and postincisional ultrasound-guided transversus abdominis plane block. *J Anaesthesiol Clin Pharmacol* 2021;37:406-10.

Submitted: 25-Aug-2019

Revised: 04-Nov-2019

Accepted: 20-Dec-2019

Published: 12-Oct-2021

hypothesized that patients receiving TAP blocks prior to surgical incision would have better postoperative pain relief and requires less opioid administration during the postoperative period.

## Material and Methods

Ethical approval for this study was provided by the institutional ethics committee (AIMSIEC/59/2014). It was registered at Clinical Trials Registry-India (Reference number: CTRI/2018/04/013312). URL: <http://ctri.nic.in/Clinicaltrials/rmaindet.php?trialid=24886&EncHid=55714.65979&modid=1&compid=19> A written informed consent was obtained from all patients enrolled in the study. 54 American Society of Anesthesiologists physical status I and II patients aged between 30 and 60 years undergoing total abdominal hysterectomy with or without oophorectomy using a Pfannenstiel incision under spinal anesthesia were chosen for the study. Patients with bleeding diathesis, BMI  $\geq 30$ , failed block, those who did not give consent and those in whom surgery was done under general anesthesia were excluded from the study.

Patients satisfying the inclusion criteria were alternately allocated to receive a TAP block either immediately after the surgery (postincisional) (Group A) or after the spinal anesthesia and about 20 min prior to the surgical incision (preincisional) (Group B). Anesthesia was standardized in all the patients. Midazolam 2 mg was given intravenously to all patients before the spinal anesthetic. Then a subarachnoid block with 17.5 mg 0.5% hyperbaric bupivacaine was done in the lateral position. No prophylactic antiemetics were administered. In addition, a standard postoperative analgesic regimen comprising of paracetamol intravenously and tramadol intramuscularly was given as part of multimodal analgesia.

The transversus abdominis plane block was performed under real-time ultrasound guidance using a linear array probe of 6–13 MHz (Venue 40, GE Healthcare), either before surgery (preincision) or at the end of surgery (postincision) by a trained anesthesiologist. It was done bilaterally just above the level of the iliac crest.

The total volume of the local anesthetic injected was 40 mL of 0.25% Bupivacaine (20 mL on each side) in a dose not exceeding 2 mg/kg. Patients in whom the stipulated volume could not be given due to toxicity concerns were excluded from the study.

Vital signs (heart rate, respiratory rate, and noninvasive blood pressure) were monitored by three trained ICU nurses who were not aware of when the block was given. Pain severity was assessed by them using the numeric pain intensity scale (0 = no pain and 10 = worst possible pain). Rescue

analgesia was given to patients by the nurses on demand or when the pain score was  $>3$ . It was in the form of morphine as 2 mg aliquots intravenously every 20 min till their pain score became  $\leq 3$ , to a maximum dose of 0.1 mg/kg. The time to first need of rescue analgesia (in the form of morphine) and the total dose of morphine received during the 24 hour postoperative period were recorded.

Complications of TAP block like intramuscular hematoma and abscess, visceral puncture, or perforation were specifically looked for. We also monitored the undesirable side effects of opioid usage like postoperative nausea and vomiting (PONV), sedation, and respiratory depression. These assessments were performed at 1/2, 1, 2, 4, 6, 12, and 24 h after the surgical procedure.

PONV was measured using a categorical scoring system (none = 0; mild = 1; moderate = 2; severe = 3) and the need for rescue antiemetic with ondansetron 4 mg was noted. Sedation scores were rated using a sedation scale (awake and alert = 0; quietly awake = 1; asleep but easily arousable = 2; deep sleep = 3).

The primary outcome measures included the numeric pain intensity scores, postoperative opioid consumption in the first 24 h and any complications of TAP block. The secondary outcome measures included PONV, sedation, and the need for rescue antiemetics.

We also did a cadaveric study on 3 human cadavers onto 6 hemi abdominal walls, to detect whether a drug injected in the transversus abdominis plane after the surgical incision, would leak out through the incisional site. After putting a Pfannenstiel incision on the cadaver, the transversus abdominis plane was identified by anatomical dissection. 20 mL of methylene blue was injected on both sides into the transversus abdominis plane and the incisional site was checked for any leakage of the dye.

### Sample size calculation

One of the primary endpoints of this study was the mean time to requirement for a rescue analgesic after transversus abdominis plane block. As per previous study by Yasser Mohamed Amr *et al.*,<sup>[4]</sup> time for first analgesic requirement in the ward was  $135 \pm 18$  minutes in the first group and  $120 \pm 16$  minutes in the second group. Based on this, by power analysis, we determined that a sample size of 27 patients per group is required with 90% power of the study and 5% alpha error. Hence, total patients enrolled for the study was 54.

### Statistical analysis

All data were collected, coded and entered into a Microsoft Excel sheet and analyzed using statistical package for social

**Table 1: Demographic data**

	Postincisional TAP group A (n=27)	Preincisional TAP group B (n=27)
Age (year) (mean±SD)	45.92±3.51	45.07±3.91
Weight (kg) (mean±SD)	61.85±4.34	62.11±5.04
Height (cm) (mean±SD)	166.92±3.44	166.07±2.35
BMI (kg/m <sup>2</sup> ) (mean±SD)	22.26±2.22	22.54±2.04
Mean duration of surgery (h) (mean±SD)	1.76±0.30	1.79±0.33

sciences (SPSS version 23). Data were assessed with independent t-test and Mann-Whitney U test. All results were presented in the form of the mean  $\pm$  standard deviation or number and percentage as appropriate. A 'P' value  $\leq 0.05$  was statistically significant.

## Results

This study had 54 patients. The characteristics of these patients are shown in Table 1. Statistical analysis revealed no significant differences between the groups in their demographic data and duration of the operative procedure.

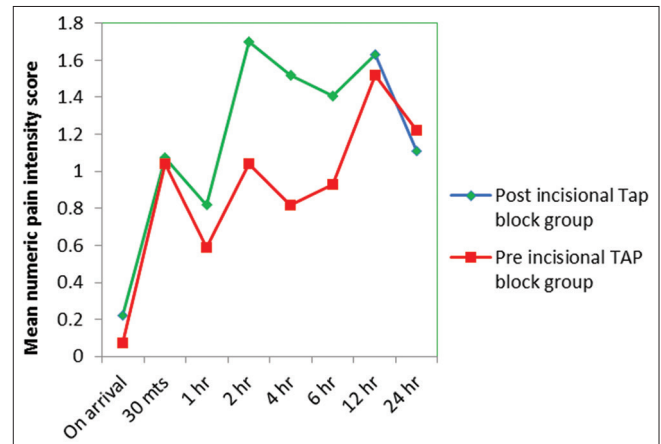
The mean value of pain scores was calculated at various time intervals and presented in Figure 1. Pain scores were found to be significantly less ( $P < 0.05$ ) in the pre-incisional TAP block group from the 2<sup>nd</sup> hour till 12 h. Thereafter it was comparable between the two groups. The total morphine requirement was significantly less in the preincisional TAP group ( $P$ -value 0.001).

The mean time to first request for morphine was significantly longer in the preincisional TAP block group (preincisional TAP block group  $10.8 \pm 2.68$  h versus post incisional TAP group  $3.64 \pm 3.44$  h with a  $P$  value of 0.002). 67% of patients in the postincisional TAP block group required rescue analgesia whereas only 19 of patients of the preincisional group required it [Figure 2].

Sedation scores were comparable in the postoperative period except at the 4<sup>th</sup> hour, where it was significantly higher ( $P$ -value of 0.024) in the post incisional TAP block group. Respiratory depression was not recorded in any patient.

Incidence of postoperative nausea and vomiting was higher in the postincisional TAP block group. 30% of patients in the postincisional TAP block group had vomiting when compared to 19% in the other group. The mean value of nausea score was significantly higher in the post incisional TAP block group during the 2<sup>nd</sup> and 4<sup>th</sup> postoperative hours [Figure 3].

In the cadaver study, we noticed that methylene blue injected into the transversus abdominis plane after the Pfannenstiel incision leaked out through the incision on both sides in all the



**Figure 1:** Comparison of the mean value of pain score in both groups

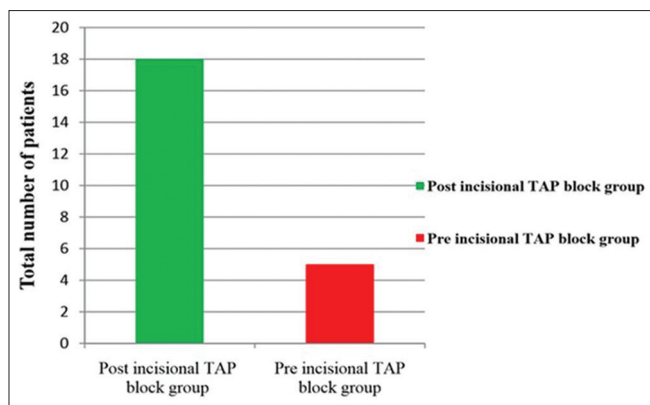
3 cadavers bilaterally, and continued to leak for about 10 min post procedure [Figure 4].

## Discussion

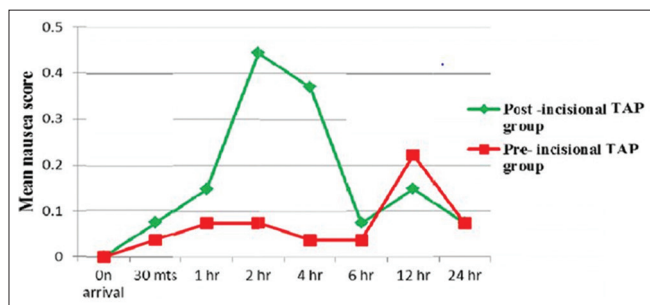
Total abdominal hysterectomies are associated with significant postoperative pain. Adequate postoperative pain relief is important to prevent negative outcomes such as tachycardia, hypertension, myocardial ischemia, decrease in alveolar ventilation, and poor wound healing.<sup>[5]</sup> A major component of total abdominal hysterectomy pain arises from the abdominal wall incision and therefore blockade of the sensory supply to the anterior abdominal wall should help in alleviating the postoperative pain. The entire sensory supply of the anterior abdominal wall could be blocked by the transversus abdominis plane block,<sup>[6,7]</sup> and is more effective when performed under ultrasound guidance.<sup>[8]</sup> Studies showed that both preincision and postincision TAP blocks have been used. We wanted to compare both these methods with regards to postoperative pain relief and adverse effects if any. Our study showed a significant decrease in pain scores in the preincisional TAP block group from the 2<sup>nd</sup> hour onwards. The initial similarity must be because of the spinal anesthetic.

The reasons for more postoperative pain relief with the preincisional TAP block might be due to:

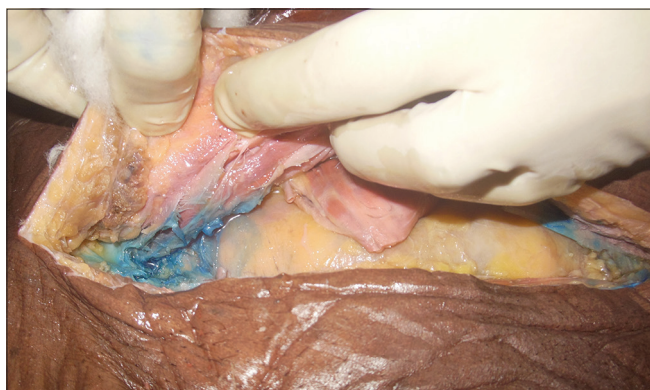- 1) Preemptive analgesia: Analgesia initiated before the surgical procedure which reduces the physiological



**Figure 2:** Comparison of the total number of patients in both groups requiring rescue analgesics



**Figure 3:** Comparison of mean nausea scores in the first 24 h postoperative period



**Figure 4:** Picture showing leakage of methylene blue through surgical incision when dye was injected after pfannenstiel incision

consequences of nociceptive transmission, thus providing more effective postoperative pain relief than an analgesic treatment initiated after surgery.<sup>[9,10]</sup>

- Part of the drug deposited in the TAP plane might be leaking out through the surgical incision when the drug was given after surgery. This was supported by the leakage of methylene blue through the surgical site in all the 3 cadavers bilaterally of our cadaveric study when it was given after the surgical incision.

Pain scores were less in the pre-incisional TAP block group and only 19% in that group requested rescue analgesia (whereas

67% in the other group needed rescue analgesia). Because of the increased duration of analgesia with preincisional TAP blocks, the meantime to the first request for rescue analgesia was significantly longer ( $P$ -value of 0.003) in that group. Total morphine consumption was more in the postincisional TAP block group and that may be why they experienced more unpleasant effects of parenteral opioids like increased nausea and vomiting. Sedation scores were comparable between both the groups except at the 4<sup>th</sup> hour where it was higher in the postincisional TAP block group. This might be due to the early rescue morphine given for pain.

Even though there are many studies mentioning the efficacy of ultrasound-guided TAP block using a classical approach,<sup>[11-16]</sup> only very few have mentioned about different approaches for TAP block under ultrasound guidance.<sup>[17,18]</sup> If post incisional TAP block has to be performed, we would recommend a more posterior approach, as that might reduce the leaking of the drug through the surgical incision. Further studies are needed for evaluating the efficacy of a more posterior approach to the postincisional TAP block. In a similar study, sedation scores were significantly more in the postincisional TAP block group.<sup>[4]</sup> This might be due to morphine bolus as rescue analgesia in a dose of 0.1 mg/kg. We didn't experience such a difference, and that might be because in our study we had given morphine as rescue analgesia in 2 mg aliquots till the pain score was  $\leq 3$ .

One of the limitations of our study might be that the observations were done for only 24 h, whereas studies have shown that the effect of TAP blocks lasted up to 48 h. Moreover, this study was confined only to one surgery and we did not extend it to include other abdominal surgeries.

## Conclusions

TAP blocks, as part of multimodal analgesia, are an acceptable choice for postoperative pain relief after lower abdominal surgeries. Our study showed that a preincisional TAP block reduced acute pain, analgesic requirements, and incidence of PONV when compared with a block performed after completion of the surgical procedure

## Acknowledgments

Department Of Anatomy, Government Medical College, Thrissur for allowing to do the cadaver study.

## Financial support and sponsorship

Nil.

## Conflicts of interest

There are no conflicts of interest.



## References

1. Ng A, Swami A, Smith G, Davidson AC, Emembolu J. The analgesic effects of intraperitoneal and incisional bupivacaine with epinephrine after total abdominal hysterectomy. *Anesth Analg* 2002;95:158-62.
2. Carney J, McDonnell JG, Ochana A, Bhinder R, Laffey JG. The transversus abdominis plane block provides effective postoperative analgesia in patients undergoing total abdominal hysterectomy. *Anesth Analg* 2008;107:2056-60.
3. Melnikov AL, Bjoergo S, Kongsgaard UE. Thoracic paravertebral block versus transversus abdominis plane block in major gynecological surgery: A prospective, randomized, controlled, observer-blinded study. *Local Reg Anesth* 2012;5: 55-61.
4. Amr YM, Amin SM. Comparative study between effect of pre- versus post-incisional transversus abdominis plane block on acute and chronic post-abdominal hysterectomy pain. *Anesth Essays Res* 2011;5:77-82.
5. Vadivelu N, Mitra S, Narayan D. Recent advances in postoperative pain management. *Yale J Biol Med* 2010;83:11-25.
6. McDonnell JG, O'Donnell BD, Farrell T, Gough N, Tuite D, Power C, *et al.* Transversus abdominis plane block: A cadaveric and radiological evaluation. *Reg Anesth Pain Med* 2007;32:399-404.
7. Zorica J, Niaz A, Nagaraja R. Transversus abdominis plane block: How safe is it? *Anesth Analg* 2008;107:1758-9.
8. Atim A, Bilgin F, Kilickaya O, Purtuloglu T, Alanbay I, Orhan ME, *et al.* The efficacy of ultrasound-guided transversus abdominis plane block in patients undergoing hysterectomy. *Anesth Intensive Care* 2011;39:630-4.
9. Woolf CJ, Chong MS. Preemptive analgesia-treating postoperative pain by preventing the establishment of central sensitization. *Anesth Analg* 1993;77:362-79.
10. Dahl JB, Moiniche S. Pre-emptive analgesia. *Br Med Bull* 2004;71:13-27.
11. Shibata Y, Sato Y, Fujiwara Y, Komatsu T. Transversus abdominis plane block. *Anesth Analg* 2007;105:883.
12. Chaudhuri S, Goyal S. Ultrasound-guided transversus abdominis plane block: A technically easier analgesic option in obese compared to epidural. *Anesth Essays Res* 2012;6:226-8.
13. El-Dawlatly AA, Turkistani A, Kettner SC, Machata AM, Delvi MB, Thallaj A, *et al.* Ultrasound-guided transversus abdominis plane block: Description of a new technique and comparison with conventional systemic analgesia during laparoscopic cholecystectomy. *Br J Anaesth* 2009;102:763-7.
14. Belavy D, Cowlshaw PJ, Howes M, Phillips F. Ultrasound-guided transversus abdominis plane block for analgesia after Caesarean delivery. *Br J Anaesth* 2009;103:726-30.
15. Mukhtar K, Singh S. Transversus abdominis plane block for laparoscopic surgery. *Br J Anaesth* 2009;102:143-4.
16. Niraj G, Searle A, Mathews M, Misra V, Baban M, Kiani S, *et al.* Analgesic efficacy of ultrasound-guided transversus abdominis plane block in patients undergoing open appendicectomy. *Br J Anaesth* 2009;103:601-5.
17. Carney J, Finnerty O, Rauf J, Bergin D, Laffey JG, Mc Donnell JG. Studies on the spread of local anaesthetic solution in transversus abdominis plane blocks. *Anesthesia* 2011;66:1023-30.
18. Escudero-Fung M, Lehman EB, Karamchandani K. Timing of Transversus Abdominis Plane Block and Postoperative Pain Management. *Local Reg Anesth* 2020;13:185-193.