

Tropical Enteropathies

John Louis-Auguste¹ · Paul Kelly^{1,2}

Published online: 24 May 2017

© The Author(s) 2017. This article is an open access publication

Abstract

Purpose of Review The term ‘tropical enteropathy’ originated in observations in the 1960s that small intestinal morphology and function differed in the tropics from the norms found in temperate climates. It was subsequently shown that this enteropathy is more closely related to environmental conditions than latitude, and it was re-labelled ‘environmental enteropathy’. It is now recognised that environmental enteropathy (also now called environmental enteric dysfunction) has implications for the health and linear growth of children in low- and middle-income countries, and it may underlie poor responses to oral vaccination in these countries. The purpose of this review is to define and clarify this enteropathy despite the confusing terminology it has attracted and to contrast it with other enteropathic states.

Recent Findings Recent work has begun to demonstrate the nature of the mucosal lesion and the relationship with microbial translocation which is currently thought to link a failure of mucosal barrier function and the cascade of systemic inflammation which inhibits growth. The evidence is still correlative rather than definitive, but derives some additional support from animal models. There are some common features between environmental enteropathy and other enteropathies, but there are important differences also. The mechanism of the link between enteropathy and vaccine failure is not

understood, and neither is it clear how the more severe form of enteropathy, which we refer to as malnutrition enteropathy, is driven by nutrient depletion and intestinal infection.

Summary Tropical enteropathies form a group of disorders which include environmental and nutritional enteropathies. The long-term health implications of these disorders for health in low-income countries are just being explored, but the scale of their effects is very large, with millions of people affected.

Keywords Tropical enteropathy · Environmental enteropathy · Environmental enteric dysfunction · Tropical sprue · Malnutrition

Introduction

The History of ‘Tropical Enteropathy’

A number of investigations into overt, symptomatic diarrhoea and malabsorption in the tropics in the early 1960s used apparently asymptomatic, healthy and well-nourished adults and children from the same population as control subjects. Unexpectedly, they uniformly identified a high prevalence of abnormal intestinal permeability (as measured by urinary sugar recovery) and/or histological abnormalities (villous blunting, crypt hypertrophy, villous fusion and mucosal inflammation) in these controls [1]. Studies in American soldiers and Peace Corps volunteers stationed in Thailand [2] and in Peace Corps volunteers in modern-day Bangladesh [3] showed that the condition was acquired and that these abnormalities were similar to those observed in the indigenous population [4]. Furthermore, histological examination of foetal and neonatal intestine also showed that these abnormalities were not present during development and only became apparent after 6 months.

This article is part of the Topical Collection on *Small Intestine*

✉ Paul Kelly
m.p.kelly@qmul.ac.uk

¹ Blizard Institute, Barts & The London School of Medicine, Queen Mary University of London, Newark Street, London E1 2AT, UK

² TROPGAN, University of Zambia School of Medicine, University Teaching Hospital, Lusaka, Zambia

These changes were reversible, as demonstrated by prospective assessment of small bowel histology and absorption. Peace Corps volunteers who had lived in India or Pakistan returned to histological and absorptive normality, usually within 2 years after returning to the USA [5]. Furthermore, adult students from endemic areas moving to the USA to study also normalised intestinal structure and function [6], and in the UK, it was noted that there was a relationship between villus morphology and the time from last visit to the tropics [7]. Based on the initial studies which were exclusively conducted in the tropics, the condition was labelled ‘tropical enteropathy’ [8].

The Adoption of ‘Environmental Enteropathy’

However, an extensive worldwide study clearly demonstrated that the observed abnormalities were not observed in some affluent, tropical populations (such as Singapore and Qatar) [9], and the condition is therefore more correctly termed environmental enteropathy (EE). Brunser, working in Santiago which is not tropical, noted the same enteropathy in children living in insanitary slums [10]. Numerous subsequent studies have confirmed that EE is highly prevalent throughout the developing world irrespective of climate and, in particular, is associated with economic conditions [8, 9, 11]. It is seasonal [12].

Early studies of EE demonstrated significant abnormalities in sugar absorption and permeability assays. These tests provide a safe and non-invasive measurement of intestinal permeability and absorptive function, and as such are suited to studies of enteropathy in children in particular [13–15]. Sugar tests have therefore become the de facto test of choice in studies of enteropathy, though recent studies have started to change this. Studies in adults and children typically show reduced urinary recovery of absorbable sugars such as xylose (indicating impaired absorptive capacity) and increased urinary levels of inabsorbable sugars such as lactulose (indicating increased intestinal permeability). The increased intestinal permeability to small sugars as measured by sugar absorption assays is correlated to significant and pathological abnormalities of intestinal barrier function, for example as measured by plasma LPS levels [13, 16]. In turn, chronic endotoxaemia depresses IGF1 secretion providing a mechanism of growth suppression [17••].

There is also increasing evidence from human studies that EE is associated with impaired absorption of macro- and micronutrients. An early study in Bangladeshi children showed that the xylose malabsorption was correlated with some malabsorption of carbohydrates [15]. Children with EE in rural Malawi have disordered zinc homeostasis, with impaired capacity to resorb endogenous zinc in distal small bowel (studied by measuring faecal excretion of isotopic zinc after intravenous administration [18]) regardless of zinc status,

resulting in net loss of zinc [14]. There was a strong positive correlation between L/M ratio and excretion of endogenous zinc [14].

Definition of Enteropathy

The central feature of all the tropical enteropathies is villus remodelling, with blunting and reduction in surface area. This can be identified microscopically [12] (Fig. 1) or with high-definition endoscopes (Fig. 2).

Current thinking, however, is that in order to appreciate the full ramifications of enteropathy, particularly in order to measure long-term effects, it will be necessary to describe it in several domains or axes of measurement. These include villus blunting, mucosal inflammation, barrier failure, microbial translocation, systemic inflammation and malabsorption [19].

Current Views About Environmental Enteropathy

Causation

It is really not understood why the insanitary environment precipitates EE. Current hypotheses include:

- Environmental exposure to faecal organisms of human origin, including established enteropathogens [20, 21]
- Environmental exposure to faecal organisms of animal origin
- Mycotoxins [22]
- Nutrient deficiencies, including micronutrients and macronutrients
- Inflammation generated by other infectious processes such as recurrent respiratory infections [8]

There is no firm evidence for any of these. Two major trials of water and sanitation interventions are due to report main

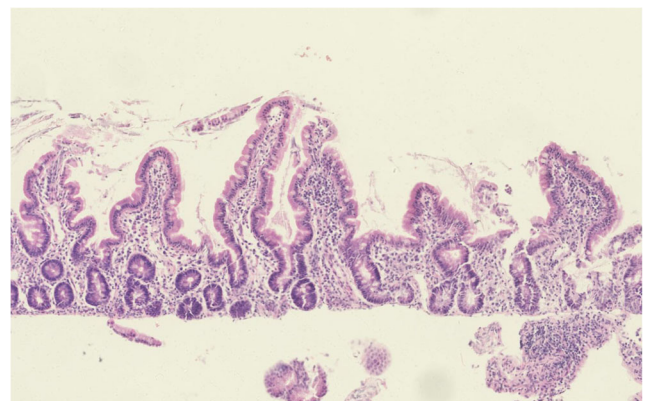
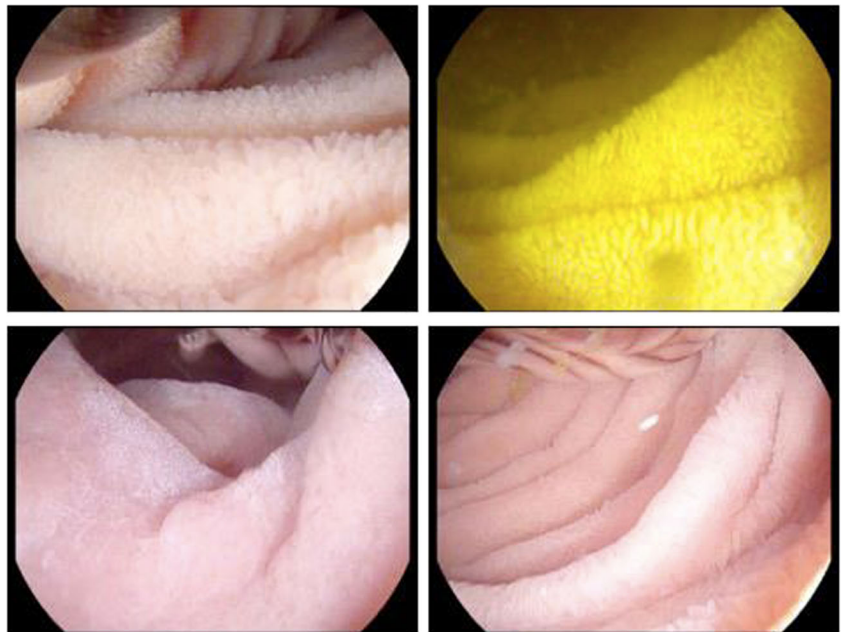


Fig. 1 Features of enteropathy in a biopsy from a child with severe acute malnutrition. There is an increased inflammatory cell infiltrate in the lamina propria and villus blunting

Fig. 2 High-definition endoscopic images of small intestinal mucosa in EE, demonstrating increasingly severe enteropathic changes. *Clockwise from top left:* predominant leaves, predominant ridges, predominant convolutions, subtotal villous atrophy



findings in 2017: the WASH-benefits trial (ISRCTNs: NCT01704105 and NCT01590095) and the SHINE trial (ISRCTN 14393738). These trials will test the faecal organisms hypotheses and, to a lesser extent, the nutrient deficiency hypotheses. Several micronutrient trials have failed to demonstrate benefit on EE [23], so if there is a nutrient deficiency underlying it, it has not yet been identified.

The complex reciprocal relationship between diet and mucosal inflammation has only recently been appreciated and remains poorly understood. This is particularly true of EE, where microbiological studies are only just beginning to be conducted. Bangladeshi children and adults living in an urban slum environment, where EE is highly prevalent, have significantly different microbiomes compared to healthy affluent US children [24]. In particular, Bangladeshi children and adults had enhanced levels of *Prevotella*, *Butyrivibrio* and *Oscillospira* and depleted in *Bacteroides* relative to US children; furthermore, the Bangladeshi microbiome was more variable over time when assessed on a monthly basis for up to 6 months [24]. Bangladeshi subjects had greatly reduced Bacteroidetes and greatly increased Firmicutes phyla, compared to US children. These children and adults remained healthy and diarrhoea- and helminth-free during the course of the study. Non-pathogenic microbes are frequently isolated from stool samples in individuals with EE. In one study in urban Zambia, for example, *Citrobacter rodentium* was over-represented [12]. This bacterial species, although not known to be pathogenic in humans, is pro-inflammatory and induces ulcerative colitis in murine models and in cell culture systems. Populations where EE and stunting are prevalent tend to have a diet low in animal fat and protein and high in starch, fibre and plant polysaccharides. These dietary differences result in

significant differences in the microbiome [25, 26•]. Comparing the faecal microbiome in children from rural Burkina Faso to Italy by 16S sequencing, for example, demonstrates a significant enrichment in Bacteroidetes and depletion in Firmicutes in Burkina Faso children [25]. This is of interest as pattern of phyla abundance is implicated in the pathogenesis of inflammatory bowel disease.

Animal models [27••, 28••] suggest that both infection and nutrient deficiency cooperate to produce enteropathy, but it is not yet clear that these truly reflect the human condition.

Pathophysiology

The intestinal epithelium and its associated structures provide a physical barrier against the teeming luminal environment, while at the same time allowing adequate uptake and absorption of ingested nutrients and water [29, 30]. Impairment or dysregulation of barrier function results in both opportunity for the translocation of microbes and microbial products into the host [31] and loss of nutrients and water into the gut lumen. Barrier dysfunction may result from one or more of physical, microbiological or immunological insults [30]. EE is characterised by an impaired physical barrier between the intestinal lumen and the mucosal and submucosal vasculature, which is normally maintained by the epithelial barrier. This results in increased intestinal permeability, which results in loss of plasma constituents into the bowel lumen, and microbe and microbial product translocation. The normal physiological intestinal barrier comprises four interlinked components: the mucus barrier, the epithelium, the adaptive and innate contributions from the mucosal immune system [32, 33] and the microbiome. Intestinal mucus is composed of a variety of

glycans secreted by epithelial goblet cells [34]. The mucus barrier provides a physical, biochemical and anti-microbial barrier to chemical, physical and microbiological insults. Secondly, it traps potentially harmful bacteria away from the intestinal epithelium. Furthermore, physiological mucus can promote the establishment and growth of beneficial/anti-inflammatory bacterial taxa (and conversely inhibits the growth of deleterious species) by providing them with tax-specific nutrients. It is increasingly recognised that mucus composition and production are tightly regulated. Disorders of mucus production or composition predispose to intestinal inflammation and are observed in inflammatory bowel disease, but this has not been studied in EE.

Using confocal laser endomicroscopy, we have been able to identify epithelial lesions in vivo [35•]; prominent among which are microerosions and points of leakage which allow passive translocation of bacteria and bacterial components into the sub-epithelial compartment and transexudation of plasma constituents into the gut lumen (Fig. 3).

Long-Term Sequelae of EE

Current thinking is that EE leads to stunting (failure of linear growth) [17••] and failure to respond to oral vaccines [36]. More speculatively, it has been suggested that other non-communicable diseases may originate in childhood enteropathies.

Tropical Sprue

This is a very different disorder. The manifestations of this now-obscure disorder include persistent diarrhoea and profound weight loss. This is in total contradistinction to

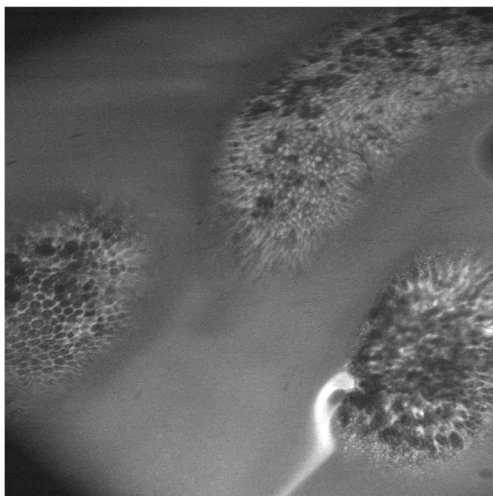


Fig. 3 Confocal laser endomicroscopy of villus structures in environmental enteropathy in a Zambian adult. In contrast to the normal situation, in which fluorescein injected intravenously during the procedure is contained within the mucosa by tight junctions between epithelial cells, fluorescein here is observed leaking from the mucosa

tropical/environmental enteropathy which by definition is completely asymptomatic. Tropical sprue has been reported only rarely from Africa [8], and most of these reports do not exclude other disorders, but was common in South Asia and the Caribbean. Tropical sprue has become rare, which might be explained if older tropical sprue cases were previously due to infections which can now be diagnosed with precision [37]. One of us (PK) has seen a case in East London in an immigrant from Bangladesh. The old definition of tropical sprue includes evidence of malabsorption of fat, vitamin B₁₂ and xylose. This is difficult to establish in an age when clinical chemistry laboratories can no longer measure faecal fat or perform a Schilling test. We propose that in order to diagnose tropical sprue in the twenty-first century, it is necessary that the clinical picture is consistent with sprue (diarrhoea and weight loss), small intestinal biopsies are consistent with sprue (villus blunting, increased crypt depth and lymphocyte infiltration) and there is evidence of small intestinal malabsorption (low serum or red cell folate, a fat-soluble vitamin such as retinol) *in the absence of intestinal infection*.

Malnutrition Enteropathy

Malnutrition underlies almost half of all child deaths globally and therefore contributes enormously to the unacceptably high under-5 mortality rates in these regions [38•]. Chronic undernutrition is usually manifest as stunting (poor linear growth), affects 30–40% of children in Zimbabwe and Zambia [39] and is associated with increased mortality [40•], reduced neurodevelopmental potential and decreased long-term economic productivity [41]. Current thinking is that environmental enteropathy makes a major contribution to chronic undernutrition [17••]. Acute malnutrition is usually manifest as wasting (loss of tissue), the most conspicuous of all nutritional disorders. Severe acute malnutrition (SAM) carries the highest mortality [42], particularly if associated with complications. Children with clinical complications of SAM requiring hospital treatment often fail to respond to treatment [43] and continue to experience high mortality of up to 35% [42, 44]. Even after discharge, children have a poor prognosis, with 42% mortality over the subsequent year [45]. In our experience, it is a subgroup of children with SAM and persistent diarrhoea who pose the most difficult management challenges, although the vast majority of children with SAM have a degree of enteropathy [44, 46]. Indeed, the intimate relationship between malnutrition and a ‘chronic derangement of the alimentary canal’ was described among the British poor in 1868 [47]. A high pathogen burden causes damage to the mucosa which exacerbates nutritional impairment and leads to further susceptibility to infection and impaired epithelial regeneration in a cyclical process first described in Central America in the 1970s [48, 49]. This mucosal damage in SAM we here refer to

as *malnutrition enteropathy*, and it is associated with very dramatic elevations of inflammatory molecules in the blood. The sequence of events, however, is not understood. Clinical experience among physicians who treat malnutrition suggests that children with moderate acute malnutrition (MAM) often progress to SAM, but it is not clear if it is nutrient deprivation per se which drives this or if it is infectious or inflammatory processes which drive progression. SAM may be complicated by oedema ('kwashiorkor'), and we have some evidence that this is associated with glycosylation defects [50].

It may be instructive to contrast two radically different extreme malnutrition disorders. In victims of the Nazi genocides of the 1940s, extreme malnutrition and intestinal atrophy were characterised by universal and often fatal diarrhoea [51, 52], and one Hungarian physician postulated that extreme malnutrition 'rendered the intestines extraordinarily susceptible to infection' [53]. Many physicians working in the appalling conditions of the concentrations camps expressed the view that malnutrition diarrhoea is not infectious in aetiology [51, 54]. There are data from animal models which suggest that pure starvation can induce a hypersecretory state in the small intestine [55–57]. In contrast, extreme malnutrition in patients with anorexia nervosa is not associated with diarrhoea [58] despite what must inevitably be a very advanced state of intestinal atrophy. For obvious reasons, it is difficult to study intestinal structure and function in the circumstances in which extreme malnutrition occurs, so our understanding of enteropathy in severe malnutrition is rudimentary and much work is needed to understand how to reverse the enteropathy.

Contrasting Tropical with Other Enteropathies

The spectrum of enteropathies is increasing, though a detailed description is beyond the scope of this review. Coeliac disease is prevalent all over the globe, though our experience is that it is uncommon in Zambia where we have most experience. Autoimmune enteropathy is rare everywhere and characterised by autoantibodies. NSAID-induced enteropathy is well described [59]. Recently, an olmesartan-related enteropathy has been described [60], and the genetic basis for an enteropathy related to defective prostaglandin transport has been reported [61]. Although a number of enteropathies look superficially similar to EE, there are recognisable differences. Where there are sufficient data to comment, these enteropathies are contrasted in Table 1. There are marked differences in responses to treatment: children with kwashiorkor and marasmus—both forms of severe acute malnutrition—respond to nutritional treatment, and we assume that this includes the enteropathy of malnutrition. Tropical sprue responds to tetracycline and folic acid. However, the other enteropathies do not respond to either.

Table 1 Similarities and differences between various small bowel enteropathies

Condition	Distribution	Mucosal inflammation	Barrier defect	Glycosylation defect	Systemic inflammation	Diarrhoea	Malabsorption	Weight loss	Response to antibiotics	Response to nutritional therapy	Mortality
Environmental enteropathy	Proximal	+	+	?	+	-	Subclinical only	-	-	-	-
Kwashiorkor	Not defined	++	++	++	++	+/-	+	++	+	+	++
Marasmus	Not defined	++	++	-	++	+/-	+	++	+	+	++
Coeliac disease	Proximal	+	+	?	-	+	+	+	+	-	Rare
GVHD	Variable	+	+	?	-	+	Probably	+	-	-	++
Tropical sprue	Global, often distal	+	+	?	?	++	++	++	+	+	Rare
Autoimmune enteropathy	Global	++	?	?	?	++	++	+	-	-	++
Olmesartan enteropathy	Global	++	?	?	?	+	+	+	-	-	-

Kwashiorkor is a term used to describe severe acute malnutrition with oedema, and marasmus to describe severe acute malnutrition without oedema
GvHD graft-versus-host disease

Conclusions

There are several enteropathies which can occur in individuals living in tropical regions, but only tropical sprue is exclusive to tropical populations. Tropical sprue is likely to be purely infectious, but environmental enteropathy is probably due to a combination of infectious and nutritional derangements. Whether malnutrition enteropathy is a distinct disorder due to severe nutritional depletion, or merely the severe end of a spectrum of enteropathies due to interactions between infection and nutrient depletion, is not clear at this time. Any other enteropathic disorder may be seen in a patient in a tropical region, just as they may be in any population centre. More work is needed to determine how best to heal the mucosal defect in children with environmental enteropathy or severe acute malnutrition, as it is the children who bear the most severe consequences of these disorders in the tropics.

Compliance with Ethical Standards

Conflict of Interest Paul Kelly and John Louis-August declare no conflict of interest.

Human and Animal Rights and Informed Consent This article does not contain any studies with human or animal subjects performed by any of the authors.

Open Access This article is distributed under the terms of the Creative Commons Attribution 4.0 International License (<http://creativecommons.org/licenses/by/4.0/>), which permits unrestricted use, distribution, and reproduction in any medium, provided you give appropriate credit to the original author(s) and the source, provide a link to the Creative Commons license, and indicate if changes were made.

References

Papers of particular interest, published recently, have been highlighted as:

- Of importance
- Of major importance

1. Lindenbaum J, Harmon JW, Gerson CD. Subclinical malabsorption in developing countries. *Am J Clin Nutr.* 1972;25:1056–61.
2. Keusch GT, Plaut AG, Troncale FJ. Subclinical malabsorption in Thailand. II. Intestinal absorption in American military and Peace Corps personnel. *Am J Clin Nutr.* 1972;25:1067–73.
3. Lindenbaum J, Kent TH, Sprinz H. Malabsorption and jejunitis in American Peace Corps volunteers in Pakistan. *Ann Intern Med.* 1966;65:1201–9.
4. Lindenbaum J. Small intestine dysfunction in Pakistanis and Americans resident in Pakistan. *Am J Clin Nutr.* 1968;21:1023–9.
5. Lindenbaum J, Gerson CD, Kent TH. Recovery of small-intestinal structure and function after residence in the tropics. I. Studies in Peace Corps volunteers. *Ann Intern Med.* 1971;74:218–22.
6. Gerson CD, Kent TH, Saha JR, Siddiqi N, Lindenbaum J. Recovery of small-intestinal structure and function after residence in the

- tropics. II. Studies in Indians and Pakistanis living in new York City. *Ann Intern Med.* 1971;75:41–8.
7. Wood GM, Gearty JC, Cooper BT. Small bowel morphology in British Indian and Afro-Caribbean subjects: evidence of tropical enteropathy. *Gut.* 1991;32:256–9.
8. Cook GC. *Tropical gastroenterology.* Oxford: Oxford University Press; 1980.
9. Menzies I, Zuckerman MJ, Nukajam WS, Somasundaram SG, Murphy B, Jenkins AP, Crane RS, Gregory GG. Geography of intestinal permeability and absorption. *Gut.* 1999;44:483–9.
10. Brunser O, Araya M, Espinoza J, Figueroa G, Pacheco I, Lois I. Chronic environmental enteropathy in a temperate climate. *Hum Nutr Clin Nutr.* 1987;41:251–61.
11. Prendergast A, Kelly P. Enteropathies in the developing world: neglected effects on global health. *AmJTrop Med Hyg.* 2012;86:756–63.
12. Kelly P, Menzies I, Crane R, Zulu I, Nickols C, Feakins R, Mwansa J, Mudenda V, Katubulushi M, Greenwald S, Farthing MJG. Responses of small intestinal architecture and function over time to environmental factors in a tropical population. *AmJTrop Med Hyg.* 2004;70:412–9.
13. Campbell DI, Elia M, Lunn PG. Growth faltering in rural Gambian infants is associated with impaired small intestinal barrier function, leading to endotoxemia and systemic inflammation. *J Nutr.* 2003;133:1332–8.
14. Manary MJ, Abrams SA, Griffin IJ, Quimper MM, Shulman RJ, Hamzo MG, Chen Z, Maleta K, Manary MJ. Perturbed zinc homeostasis in rural 3–5-y-old Malawian children is associated with abnormalities in intestinal permeability attributed to tropical enteropathy. *Pediatr Res.* 2010;67:671–5.
15. Brown KH, Khatun M, Ahmed G. Relationship of the xylose absorption status of children in Bangladesh to their absorption of macronutrients from local diets. *Am J Clin Nutr.* 1981;34:1540–7.
16. Lunn PG, Northrop-Clewes CA, Downes RM. Intestinal permeability, mucosal injury, and growth faltering in Gambian infants. *Lancet.* 1991;338:907–10.
17. Prendergast AJ, Rukobo S, Chasekwa B, Mutasa K, Ntozini R, Mbuya MN, Jones A, Moulton LH, Stoltzfus RJ, Humphrey JH. Stunting is characterized by chronic inflammation in Zimbabwean infants. *PLoS One.* 2014;9:e86928. **Evidence supporting a pathophysiological link between severity of enteropathy, systemic inflammation, and growth inhibition in infants with EE.**
18. Krebs NE, Hambidge KM. Zinc metabolism and homeostasis: the application of tracer techniques to human zinc physiology. *Biometals Int J Role Met Ions Biol Biochem Med.* 2001;14:397–412.
19. Owino V, Ahmed T, Freemark M, Kelly P, Loy A, Manary M, Loechl C. Environmental enteric dysfunction and growth failure/stunting in global child health. *Pediatrics* 2016; e20160641. doi:10.1542/peds.2016-0641.
20. Guerrant RL, DeBoer MD, Moore SR, Scharf RJ, Lima AA. The impoverished gut—a triple burden of diarrhoea, stunting and chronic disease. *Nat Rev Gastroenterol Hepatol.* 2013;10:220–9. doi:10.1038/nrgastro.2012.239.
21. Humphrey JH. Child undernutrition, tropical enteropathy, toilets and handwashing. *Lancet.* 2009;374:1032–5.
22. Smith LE, Prendergast AJ, Turner PC, Mbuya MN, Mutasa K, Kembo G, Stoltzfus RJ. The potential role of mycotoxins as a contributor to stunting in the SHINE trial. *Clin Infect Dis.* 2015;61(Suppl 7):S733–7. doi:10.1093/cid/civ849.
23. Wang AZ, Shulman RJ, Crocker AH, Thakwalakwa C, Maleta KM, Devaraj S, Manary MJ, Trehan I. A combined intervention of zinc, multiple micronutrients, and albendazole does not ameliorate environmental enteric dysfunction or stunting in rural Malawian children in a double-blind randomized controlled trial. *J Nutr.* 2017;147:97–103. doi:10.3945/jn.116.237735.

24. Lin A, Bik EM, Costello EK, Dethlefsen L, Haque R, Relman DA, Singh U. Distinct distal gut microbiome diversity and composition in healthy children from Bangladesh and the United States. *PLoS One*. 2013;8:e53838.
25. De Filippo C, Cavalieri D, Di Paola M, Ramazzotti M, Poullet JB, Massart S, Collini S, Pieraccini G, Lionetti P. Impact of diet in shaping gut microbiota revealed by a comparative study in children from Europe and rural Africa. *Proc Natl Acad Sci U S A*. 2010;107:14691–6.
26. Yatsunenko T, Rey FE, Manary MJ, Trehan I, Dominguez-Bello MG, Contreras M, Magris M, Hidalgo G, Baldassano RN, Anokhin AP, Heath AC, Warner B, Reeder J, Kuczynski J, Caporaso JG, Lozupone CA, Lauber C, Clemente JC, Knights D, Knight R, Gordon JI. Human gut microbiome viewed across age and geography. *Nature*. 2012;486:222–7. **Ground-breaking study utilising deep sequencing of faecal microbiota to demonstrate how microbial communities differ by age and country, with interesting observations of implications for energy harvest.**
27. Liu J, Bolick DT, Kolling GL, Fu Z, Guerrant RL. Protein malnutrition impairs intestinal epithelial cell turnover, a potential mechanism of increased cryptosporidiosis in a murine model. *Infect Immun*. 2016;84:3542–9. **Experimental demonstration of the effect of dietary protein restriction on intestinal barrier function in the face of an intestinal pathogen, therefore supporting a role for diet in the aetiology of EE.**
28. Brown EM, Wlodarska M, Willing BP, Vonaesch P, Han J, Reynolds LA, Arrieta MC, Uhrig M, Scholz R, Partida O, Borchers CH, Sansonetti PJ, Finlay BB. Diet and specific microbial exposure trigger features of environmental enteropathy in a novel murine model. *Nat Commun*. 2015;6:7806. doi:10.1038/ncomms8806. **An animal model which demonstrates many of the features observed in EE, and suggests that both the microbiota and diet are important in the aetiology of EE.**
29. Rescigno M. The intestinal epithelial barrier in the control of homeostasis and immunity. *Trends Immunol*. 2011;32:256–64.
30. Turner JR. Intestinal mucosal barrier function in health and disease. *Nat Rev Immunol*. 2009;9:799–809.
31. Brenchley JM, Douek DC. Microbial translocation across the GI tract. *Annu Rev Immunol*. 2012;30:149–73.
32. Bevins CL, Salzman NH. Paneth cells, antimicrobial peptides and maintenance of intestinal homeostasis. *Nat Rev Microbiol*. 2011;9:356–68.
33. Brandtzaeg P. Secretory IgA: designed for anti-microbial defense. *Front Immunol*. 2013;4:222. doi:10.3389/fimmu.2013.00222.
34. Johansson MEV, Hansson GC. Immunological aspects of intestinal mucus and mucins. *Nat Rev Immunol*. 2016;16:639–49.
35. Kelly P, Besa E, Zyambo K, Louis-Auguste J, Lees J, Banda T, Soko R, Banda R, Amadi B, Watson A. Endomicroscopic and transcriptomic analysis of impaired barrier function and malabsorption in environmental enteropathy. *PLoS Negl Trop Dis*. 2016;10:e0004600. doi:10.1371/journal.pntd.0004600. **This study used the novel technique of confocal endomicroscopy to demonstrate small bowel dysfunction in real time and in vivo in EE, providing new insights in pathophysiology.**
36. Naylor C, Lu M, Haque R, Mondal D, Buonomo E, Nayak U, Mychaleckyj JC, Kirkpatrick B, Colgate R, Carmolli M, Dickson D, van der Klis F, Weldon W, Steven Oberste M, Ma JZ, Petri WA. Environmental enteropathy, oral vaccine failure and growth faltering in infants in Bangladesh. *EBioMedicine*. 2015;2:1759–66. doi:10.1016/j.ebiom.2015.09.036.
37. Cook GC. ‘Tropical sprue’: some early investigators favoured an infective cause, but was a coccidian protozoan involved? *Gut*. 1997;40:428–9.
38. Black RE, Victora CG, Walker SP, Bhutta ZA, Christian P, de Onis M, Ezzati M, Grantham-McGregor S, Katz J, Martorell R, Uauy R. Maternal and child undernutrition and overweight in low-income and middle-income countries. *Lancet*. 2013;382:427–51. doi:10.1016/S0140-6736(13)60937-X. **Updated comprehensive epidemiological survey demonstrating, among other things, the deleterious intergenerational effects of stunting and the very limited benefits of currently available interventions.**
39. Zambia Demographic and Health Survey 2013–14. Rockville, Maryland, USA: Central Statistical Office, Ministry of Health, and ICF International.
40. Olofin I, McDonald CM, Ezzati M, Flaxman S, Black RE, Fawzi WW, Caulfield LE, Danaei G. Associations of suboptimal growth with all-cause and cause-specific mortality in children under five years: a pooled analysis of ten prospective studies. *PLoS One*. 2013;8:e64636. **Further strong epidemiological evidence for the deleterious effect of stunting (as well as wasting) on childhood mortality, mediated particularly through respiratory and diarrhoeal disease.**
41. Victora CG, Adair L, Fall C, Hallal PC, Martorell R, Richter L, Sachdev HS. Maternal and child undernutrition: consequences for adult health and human capital. *Lancet*. 2008;371:340–57. doi:10.1016/S0140-6736(07)61692-4.
42. Lenters LM, Wazny K, Webb P, Ahmed T, Bhutta ZA. Treatment of severe and moderate acute malnutrition in low- and middle-income settings: a systematic review, meta-analysis and Delphi process. *BMC Public Health*. 2013;13(Suppl 3):S23. doi:10.1186/1471-2458-13-S3-S23.
43. Isanaka S, Langendorf C, Berthé F, Gnegne S, Li N, Ousmane N, Harouna S, Hassane H, Schaefer M, Adehossi E, Grais RF. Routine amoxicillin for uncomplicated severe acute malnutrition in children. *N Engl J Med*. 2016;374:444–53. doi:10.1056/NEJMoa1507024.
44. Amadi BC, Kelly P, Mwiya M, Mulwazi E, Sianongo S, Changwe F, Thomson M, Hachungula J, Watuka A, Walker-Smith JA, Chintu C. Intestinal and systemic infection, HIV and mortality in Zambian children with persistent diarrhoea and malnutrition. *J Ped Gastroenterol Nutr*. 2001;32:550–4.
45. Kerac M, Bunn J, Chagaluka G, Bahwere P, Tomkins A, Collins S, Seal A. Follow-up of post-discharge growth and mortality after treatment for severe acute malnutrition (FuSAM study): a prospective cohort study. *PLoS One*. 2014;9:e96030. doi:10.1371/journal.pone.0096030.
46. Trehan I, Kelly P, Shaikh N, Manary MJ. New insights into environmental enteric dysfunction. *Arch Dis Child*. 2016;101:741–4. doi:10.1136/archdischild-2015-309534.
47. Smith E. On the wasting diseases of infants and children. London: John Walton; 1868.
48. Scrimshaw NS, et al. *Monogr Ser World Health Organ*. 1968;57:3–329.
49. Mata LJ. *The Children of Santa Maria Cauqué: A Prospective Field Study of Health and Growth (International nutrition policy series)* MIT Press: 1978.
50. Amadi B, Fagbemi A, Kelly P, Mwiya M, Torrente F, Salvestrini C, Day RM, Golden MH, Eklund E, Freeze HH, Murch SH. Reduced production of sulfated glycosaminoglycans occurs in Zambian children with kwashiorkor but not marasmus. *Am J Clin Nutr*. 2009;89:592–600.
51. Winick M. *Hunger disease: studies by the Jewish physicians in the Warsaw ghetto*. New York: Wiley; 1979.
52. Lipscombe FM. Medical aspects of Belsen concentration camp. *Lancet*. 1945;ii:313–5.
53. Helweg-Larsen P, Hoffmeyer H, Kieler J, Thaysen EH, Thaysen JH, Thygesen P, Wulff MH. Famine disease in German concentration camps: complications and sequels. *Acta Med Scand*. 1952;144(supplement 244):1–460.
54. Adelsberger L. Medical observations in Auschwitz concentration camp. *Lancet*. 1946;i:317–9.
55. Young A, Levin RJ. Diarrhoea of famine and malnutrition: investigations using a rat model. 1. Jejunal hypersecretion induced by starvation. *Gut*. 1990;31:43–53.

56. Young A, Levin RJ. Diarrhoea of famine and malnutrition—investigations using a rat model. 2—ileal hypersecretion induced by starvation. *Gut*. 1990;31:162–9.
57. Young A, Levin RJ. Intestinal hypersecretion of the refed starved rat: a model for alimentary diarrhoea. *Gut*. 1992;33:1050–6.
58. Fichter MM. Mortality in eating disorders—results of a large prospective clinical longitudinal study. *Int J Eat Disord*. 2016;49:391–401.
59. Bjarnason I, Hayllar J, MacPherson AJ, Russell AS. Side effects of nonsteroidal anti-inflammatory drugs on the small and large intestine in humans. *Gastroenterology*. 1993;104:1832–47.
60. Burbure N, Lebwohl B, Arguelles-Grande C, Green PH, Bhagat G, Lagana S. Olmesartan-associated sprue-like enteropathy: a systematic review with emphasis on histopathology. *Hum Pathol*. 2016;50:127–34.
61. Umeno J, Hisamatsu T, Esaki M, Hirano A, Kubokura N, Asano K, et al. A hereditary enteropathy caused by mutations in the *SLCO2A1* Gene, encoding a prostaglandin transporter. *PLoS Genet*. 2015;11:e1005581. doi:10.1371/journal.pgen.1005581.