

Received: 2010.03.15  
Accepted: 2011.02.17

## The intraoperative assessment of the effectiveness of computed tomography in the detection of the residual mass of the retroperitoneal space in patients with nonseminoma testicular tumors after chemotherapy

Janusz Jaszczyński<sup>1</sup>, Piotr Chłosta<sup>2</sup>, Piotr Faron<sup>1</sup>, Andrzej Strach<sup>1</sup>, Piotr Jakubik<sup>1</sup>, Wacław Wilk<sup>3</sup>, Elżbieta Łuczyńska<sup>4</sup>, Joanna Anioł<sup>4</sup>, Piotr Skotnicki<sup>1</sup>, Jerzy Jakubowicz<sup>1</sup>, Andrzej Stelmach<sup>1</sup>

<sup>1</sup> Surgical Oncology Clinic, Maria Skłodowska-Curie Memorial Cancer Center and Institute of Oncology, Cracow, Poland

<sup>2</sup> Urology Department, Świętokrzyskie Oncology Center in Kielce, Kielce, Poland

<sup>3</sup> Department of Pathology, Maria Skłodowska-Curie Memorial Cancer Center and Institute of Oncology, Cracow, Poland

<sup>4</sup> Department of Diagnostic Imaging, Maria Skłodowska-Curie Memorial Cancer Center and Institute of Oncology, Cracow, Poland

**Author's address:** Joanna Anioł, Department of Diagnostic Imaging, Maria Skłodowska-Curie Memorial Cancer Center and Institute of Oncology, Garncarska 11 Str., 31-115 Cracow, Poland, e-mail: j.aniol@interia.pl

### Summary

**Background:**

The incidence of testicular tumors in Poland accounts for 2.4 new cases per 100.000 men a year. When investigating the incidence with regard to age, we may notice three age ranges with the highest incidence rate: babyhood, 25–40 years of age, and age of about 60 years.

A routine examination in patients with testicular cancer after the first course of chemotherapy is computed tomography of the retroperitoneal space which aims to exclude the presence of residual masses and to assess the effectiveness of the treatment.

**Aim of the study:**

The assessment of the effectiveness of computed tomography in the intraoperative investigation of patients with nonseminoma testicular tumors after chemotherapy.

**Material/Method:**

This detailed retrospective analysis included 182 men with nonseminoma testicular tumor treated at the Center of Oncology in Cracow, between the years 1990–1999. Men with tumors in stage from IA to IIC made up 79.68% of the patients. Twenty patients after chemotherapy, with residual masses in the retroperitoneal cavity revealed in computed tomography, underwent retroperitoneal lymphadenectomy. The investigation was carried out with GE CT spiral scanner before and after intravenous contrast administration.

**Conclusions:**

Computed tomography is a method of a satisfactory sensitivity in the assessment of residual masses in the retroperitoneal cavity in postchemotherapy patients, as concerns the location of the tumor, its size, number of foci, and the fact whether it can be operated on or not. Together with tumor markers, it allows for a precise qualification to retroperitoneal lymphadenectomy of residual masses in postchemotherapy patients.

**Key words:**

computed tomography • testicular cancer • retroperitoneal lymphadenectomy

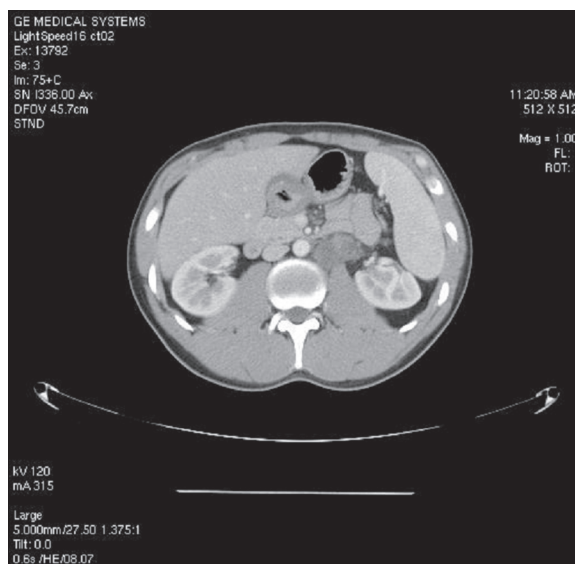
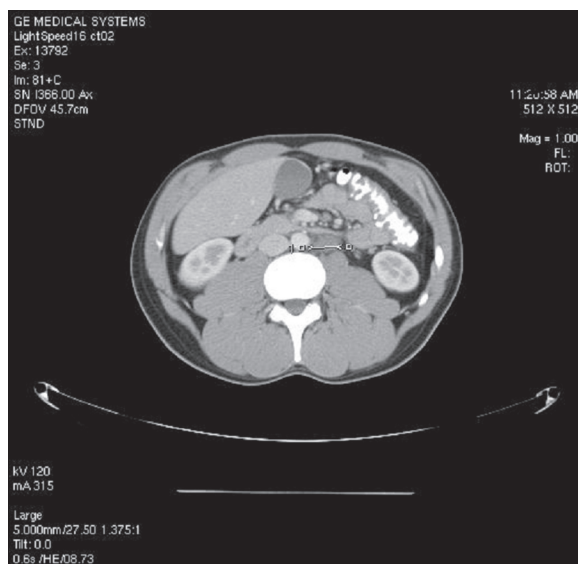
**PDF file:**

<http://www.polradiol.com/fulltxt.php?ICID=881816>

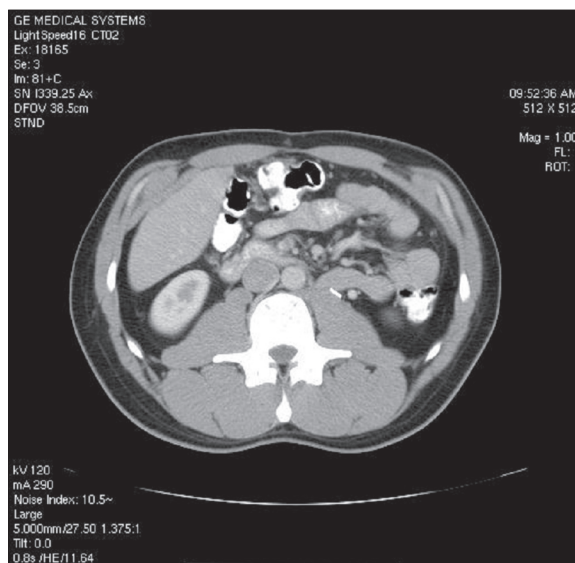
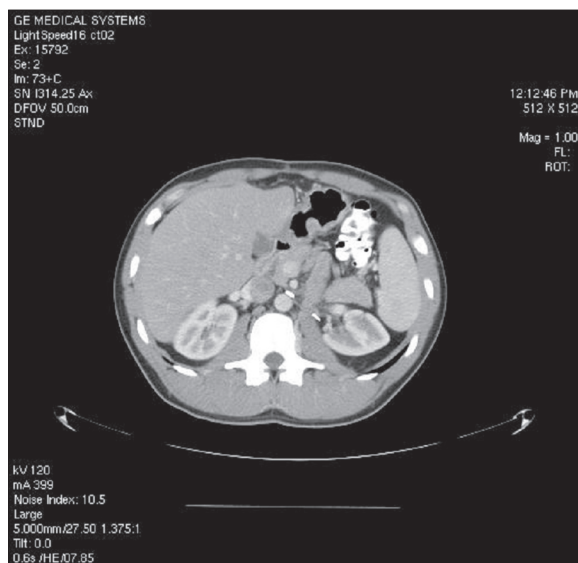
### Background

Organ tumor may develop at any age. There are many different hypotheses on its etiology or risk factors. Researchers are constantly aiming to establish and define them for particular

types of tumors but the needs within this respect increase every. It is well known that tumor development is a resultant of many factors, such as: lifestyle, substance overuse, genetic, environmental, and occupational factors, infectious conditions, and many others. The increasingly more precise



**Figures 1,2.** Abdominal tomography scan after i.v. contrast administration. Enlarged lymph nodes in the left periaortic space located typically – from the level of the left renal vessels to the level of abdominal aorta bifurcation.



**Figures 3,4.** A 24-year-old man with tumor of the right testicle. Pathological results after orchiectomy – teratoma partim immaturum. Abdominal tomography after i.v. contrast administration. Status post dissection of large retroperitoneal lymph nodes. Metallic elements at resection site. Pathological result: teratoma partim immaturum.

description of the natural history of tumors, their morphology, diagnostic methods of early and late stages of the disease, as well as treatment methods is included in the reports of interdisciplinary teams of researchers and practitioners. New algorithms of management are being constantly developed for particular diseases, for which the key issue is to identify the prognostic and risk factors. Their determination allows for treatment optimization at different stages of the disease. The incidence of testicular cancers in Poland amounts to 2.4 new cases per 100 000 men a year [1,2]. When analyzing the incidence with regard to age, we may notice three age ranges with the highest incidence rate: babyhood, 25–40 years of age, and age of about 60 years. It should be underscored that in the age group of 20–35 years, this tumor is the most frequent one in men. Mean age of patients with nonseminoma testicular tumors is 25 years. The highest incidence

is observed in the Scandinavian countries, Switzerland, Germany, and New Zealand, and the lowest one in Africa and Asia. The remaining European countries and the United States present a mean incidence rate [3,4].

#### Aim of the work

Intraoperative analysis of the effectiveness of computed tomography in visualization of the residual mass in the retroperitoneal space in patients with nonseminoma testicular tumors after chemotherapy.

#### Material and Methods

This detailed, retrospective analysis included 182 men with nonseminoma testicular tumor treated at the Center of

**Table 1.** Accordance between CT scan results and intraoperation findings in the retroperitoneal space in postchemotherapy patients.

Characteristics	Accordance of the description and intraoperative findings	%
Lesion size	16	80
Location	16	80
Number of foci	17	85

Source: own calculations.

Oncology in Cracow, in the years 1990–1999. Their mean age amounted to 28.9 years. The clinical stage of the tumor in the study group was based on TNM classification of UICC, from 1997, and the American Joint Committee on Cancer classification. Men with tumors staged from IA to IIC constituted 79.68% of the patients. In 82.22%, the tumor was classified as T1-pT2; 71.98% included patients without metastases in distant organs – M0. Histopathological diagnosis was based on WHO classification criteria [5]. A mixed nonseminoma testicular tumor was found in 69.06% of the patients. A routine examination after the first course of chemotherapy in patients with testicular tumors is the computed tomography of the retroperitoneal space, aiming to evaluate the effectiveness of the treatment and to exclude the presence of residual masses of this area. From among patients with confirmed residual masses, twenty men were qualified to retroperitoneal lymphadenectomy after their lesions were defined as appropriate for surgery (Figures 1–4).

## Results

Each of 20 laparotomies resulted in the resection of the residual masses with the use of retroperitoneal lymphadenectomy. In the above mentioned group of patients, the effectiveness of CT as an assessment method (radiologist + surgeon) of the residual masses in the retroperitoneal space amounts to 100% as regards their appropriateness for surgery. Moreover, we analyzed the accuracy of the descriptions of the residual masses found on CT, in comparison to the evaluation by the surgical team, included in the

surgical protocol, concerning the size and location of the lesion, as well as the number of foci (Table 1).

In the studied material, the sensitivity of this diagnostic method in the evaluation of the tumor size and location was 80%. Its sensitivity for detection of all foci of the disease was 85%. The effectiveness of CT as a method of evaluation of the residual retroperitoneal masses and their appropriateness for surgery was 100%.

## Discussion

Computed tomography has so far been the best, commonly available method of imaging of the retroperitoneal space, used for identification of metastases to lymph nodes [6]. It has a few advantages: a relatively high precision, no technical or time-related limitations in the evaluation of body cavities, such as the ones in MRI, and a relatively low price. In combination, these features cannot be overbalanced by any other method. However, it should not be forgotten that, as any other imaging method, this option is unable to distinguish between fibrosis, necrotic tissues, teratoma, or other living cancer cells [7,8]. In the recent reports, the accuracy of CT in the evaluation of the retroperitoneal space has been assessed at 70–80% [4,9]. In the work of 1994 on patients in the first clinical stage, the accuracy of this method in postoperative evaluation amounted to 66%. In 33% of the cases, the stage was underestimated (false negative), including 6% of patients in whom stage IIB was found [10]. In low-stage tumors, the CT can produce a lot of false positive results which lead to invasive procedures [11]. In higher clinical stages of the nonseminoma testicular tumor and positive lymph nodes of the retroperitoneal space, chest CT should be performed, as a plain X-ray omits many focal lesions in this location [3,9].

## Conclusions

Computed tomography is a method of a satisfactory sensitivity in the evaluation of the residual masses of the retroperitoneal space after chemotherapy as regards the number of foci, their appropriateness for surgery, location, and size.

In combination with tumor markers, it allows for a precise qualification to retroperitoneal lymphadenectomy of the residual masses after chemotherapy.

## References:

- Zatoński W, Tyczyński J: Nowotwory złośliwe w Polsce w 1996 roku, Centrum Onkologii w Warszawie, 1996
- Zieliński J: Nowotwory jądra, Urologia. Tom II (Urologia Kliniczna), PZWL, 1993; 21B: 471–87
- Richie JP: Neoplasms of the testis, in Walsh PC et al. (eds). Campbell's Urology. 7<sup>th</sup> ed. Philadelphia, Saunders, 1997: 2411–52
- Albers P, Albrecht W, Algaba F et al: Guidelines on Testicular Cancer. Eur Urol, 2008; 53(3): 478–96, 497–513
- Ehle JN, Sauter G, Epstein JI: Pathology WHO histological classification of testis tumours, In: & Genetics. Tumours of the urinary system and male genital organs. Lyons: IARC Press, 2004; 218: 250–62
- Calestroupat JP, Sanches-Salas R, Cathelineau X et al: Postchemotherapy laparoscopic retroperitoneal lymph node dissection in nonseminomatous germ-cell tumor. J. Endourol, 2009; 23(4): 645–50
- Stompor PC, Jochelson MS, Garnick MB, Richie JP: Abdominal masses following chemotherapy for nonseminomatous testicular cancer, correlation of CT and histology. Am J Roentgenol, 1985; 145: 743
- Sanchez-Martin FM: Surgery of retroperitoneal residual mass. Arch Esp Urol, 2000; 53(6): 535–46
- Moul JW: Proper staging techniques in testicular cancer patients. Tech Urol, 1995; 1(3): 126–32
- Fernandez EB, Moul JW, Foley JP et al: Retroperitoneal imaging with third and fourth generation computed axial tomography in clinical stage I nonseminomatous germ cell tumors. Urology, 1994; 44(4): 548–52
- Krege S, Rubben H: Lymphadenectomy for testicular cancer. Diagnostic and prognostic significance as well as therapeutic benefit. Urologe A, 2005; 44(6): 652–56