

Received: 2015.02.10
Accepted: 2015.03.23
Published: 2015.07.17

Repair of Concomitant Incisional and Parastomal Hernias Using a Hybrid Technique: A Series of 32 Patients

Authors' Contribution:
Study Design A
Data Collection B
Statistical Analysis C
Data Interpretation D
Manuscript Preparation E
Literature Search F
Funds Collection G

ACEG **Xinyong Zhu**
BCD **Wen Tian**
BCF **Jiye Li**
CDE **Pengjun Sun**
DEF **Lijuan Pei**
EF **Shijie Wang**

Department of General Surgery, The First Affiliated Hospital of Chinese PLA General Hospital, Beijing, P.R. China

Corresponding Author: Xinyong Zhu, e-mail: zhuxy304@126.com
Source of support: None

Background: Concomitant incisional and parastomal hernias is a challenging condition. We used a hybrid technique of sublay and onlay to treat patients with this condition.





Material/Methods: The clinical data of 32 consecutive patients treated from February 2008 to April 2014 for concomitant incisional and parastomal hernias were retrospectively reviewed. The mean diameter was 9 (range 4–13) cm of the incisional hernias, and 6 (range 4.5–8) cm of the parastomal hernias.

Results: The mean operative time was 247 (range 220–290) min. The mean hospital stay was 20 (range 14–27) days. All surgical wounds healed by primary intention. Seven patients had postoperative seroma and were well managed with puncture and compression. All 32 patients were followed up for a mean of 48 (range 5–68) months. Four patients recurred with parastomal hernias and were treated with secondary surgery. No further recurrence occurred until the last follow-up.

Conclusions: This hybrid technique of sublay and onlay is only suitable for the repair of complex incisional and parastomal hernias.

MeSH Keywords: **Abdominal Wall • Inlays • Neoplasm Recurrence, Local • Surgical Mesh**

Full-text PDF: <http://www.medscimonit.com/abstract/index/idArt/893838>

 1597  —  2  14



Background

Parastomal hernia may decrease the intra-abdominal pressure and lower the risk of other types of abdominal hernia. However, with extended patient survival, incisional hernia may occur with coexistent parastomal hernia. The repair of postoperative hernia is still a clinical challenge, although several minimally invasive methods are available [1–6]. Concomitant incisional and parastomal hernias can significantly impair the quality of life of patients, with symptoms ranging from mild discomfort to life-threatening surgical emergencies. Simultaneous repair of both an incisional hernia and a parastomal hernia is a surgical challenge. There is a paucity of reports on surgical approaches for repair of concomitant hernias [7,8]. Currently used surgical techniques in the repair of abdominal defects include only, sublay, and intraperitoneal onlay mesh [9–11]. Here, we report our experience of using a hybrid technique of sublay and onlay in repairing concomitant incisional and parastomal hernias.

Material and Methods

Patient information

This retrospective study included 32 patients treated from February 2008 to April 2014 for concomitant incisional and parastomal hernias at our hospital. There were 19 males and 13 females with a mean age of 49 (range 41–72) years. The mean disease course of the parastomal hernia was 8 (range 5–11 years). Previous secondary surgery was performed for the incisional hernia in 5 patients and for the parastomal hernia in 6 patients. The mean diameter was 9 (range 4–13) cm of the incisional hernias, and 6 (range 4.5–8) cm of the parastomal hernias (Figure 1). All patients had bowel prolapses.

Surgical technique

All patients received standard preoperative bowel preparation and prophylactic antibiotics. After general anesthesia, the stoma and parastomal skin were disinfected. The stoma was sealed to prevent contamination. Through a midline incision,

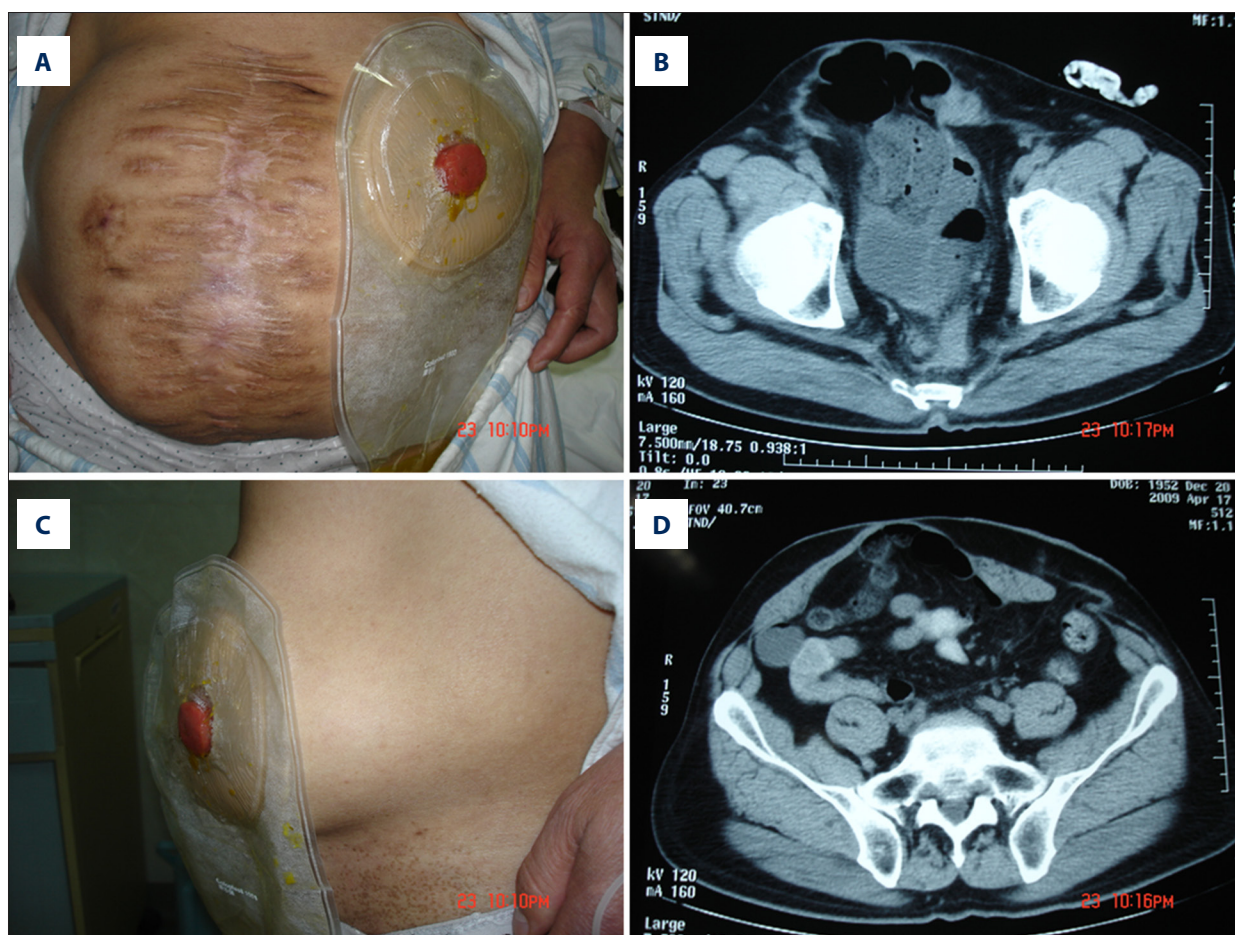


Figure 1. (A) Preoperative view of an incisional hernia. (B) Computed tomography showing an incisional hernia. (C) Preoperative view of a parastomal hernia. (D) Computed tomography showing a parastomal hernia.

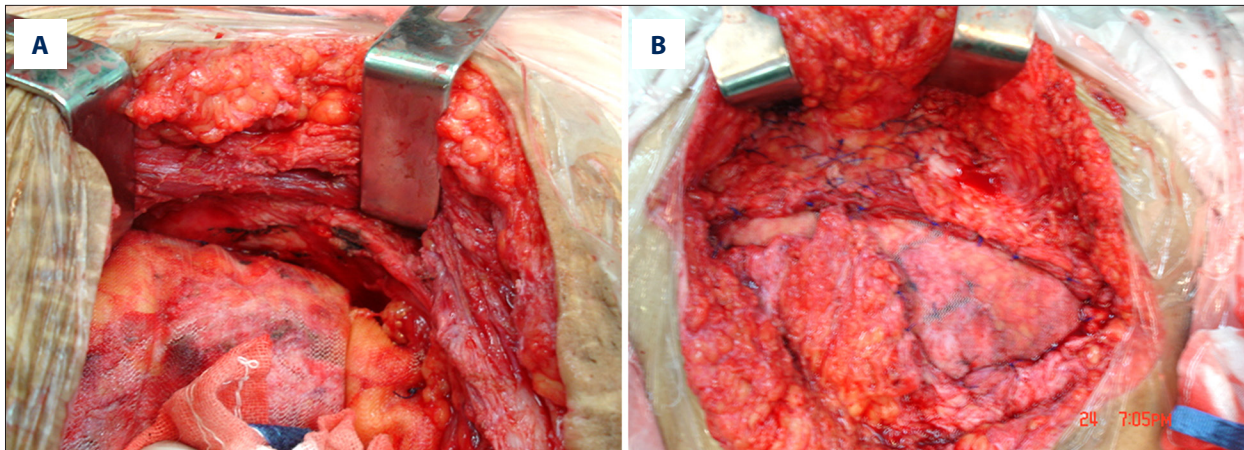


Figure 2. (A) Repair of an incisional hernia using the sublay technique. (B) Repair of a parastomal hernia using the onlay technique.

the skin, subcutaneous tissue, and the hernia sac were incised. The adhesions of the sac to the bowels and omentum were released. Dissection was performed from the retrorectus space to the linea semilunaris. On the ipsilateral side of the stoma, dissection was stopped medially to the stoma. Then the retrorectus space was established. The peritoneum was sutured with absorbable suture to reestablish the continuity. Then the prefascial space was dissected to expose the margin of the parastomal hernia. The parastomal hernia margin was closed using 1-0 Prolene suture.

The incisional hernia was repaired with the sublay technique (Figure 2A). A polypropylene mesh was trimmed according to the size of the retrorectus space. Generally, the retrorectus space is 5-cm larger than the hernia margin. The mesh was placed before the peritoneum and fixed onto the peritoneum (outer rim) using 3-0 absorbable suture. The fascia was closed using tension-free suture to reduce the scope of muscular defects. The mesh was fixed onto the hernia margin (inner rim), and fixed onto the fascial margin using 3-0 Prolene suture.

The parastomal hernia was repaired with the onlay technique (Figure 2B). When closing the parastomal hernia, the space between the stoma and the bowel should fit one finger to avoid affecting the patency and blood circulation of the stoma. The defects of the stoma and the peritoneum were closed using 3-0 absorbable suture. Enough prefascial space was dissected with the bowel as the center, with 5-cm over-sizing of the stoma. A mesh was designed with a 2.5-cm hole in the center and a slit for the bowel to move through. The mesh was fixed by suturing its inner and outer rims onto the fascia using 2-0 Prolene suture. Drains were placed bilaterally to the incisional hernia and laterally to the stoma. Abdominal compression was applied for three months.

Results

All surgeries were performed in 32 patients uneventfully. The mean operative time was 247 (range 220–290) min. Gastric tube was removed within a mean of 4 (range 3–6) days. Drainage tube was removed within a mean of 10 (range 7–14) days. The mean hospital stay was 20 (range 14–27) days. All surgical wounds healed with primary intention. All patients were followed up for a mean of 48 (range 5–68) months. Five patients had postoperative seromas and were well managed with puncture and compression. Eight patients had excessive drainage and were treated with abdominal compression and delayed drainage for 14 days. Three patients had abdominal compartment syndrome with symptoms of dyspnea and decreased blood oxygen saturation. These patients were treated with mechanical ventilation for 2 to 3 days. Four patients had stomal stenosis and were treated with anal dilation. Other complications included chronic pain in the surgical area, foreign body sensation in the abdominal wall, and slow pouching. Four patients recurred with parastomal hernias at postoperative 10 months, 12 months, 15 months, and 18 months and were well managed with secondary surgery.

Discussion

Hernias of the abdominal wall are usually not reversible. With the increase in intraabdominal pressure, the hernia margin and content are also increasing, thus decreasing the change of a second hernia at another site of the abdominal wall. However, extended patient survival can increase the risk for a second hernia. The incidence of concomitant incisional and parastomal hernias is very low. There are few clinical reports on the simultaneous repair of two abdominal hernias [7,8].

The aims of abdominal hernia surgery include repair of the abdominal defects, enforcement of the abdominal wall, and

prophylaxis of recurrence. The primary repair of incisional and parastomal hernias has unacceptably high recurrence rate [12,13]. Mesh repair can significantly decrease the abdominal tension and complication rate, and has been the first choice for the repair of abdominal hernias. When repairing concomitant incisional and parastomal hernias, the surgeons are facing large defects and the challenges of prevention of recurrence. In our experiences of using sublay and onlay for the repair of concomitant incisional and parastomal hernias, this hybrid technique had achieved good clinical outcome.

Rosen et al. reported the simultaneous repair of large midline incisional and parastomal hernias using a single mesh [8]. We have used two meshes separately for the repair of incisional and parastomal hernias as a sublay and onlay, respectively. It is still under debate about the optimal position for the mesh placement in the repair of abdominal hernias. When repairing concomitant incisional and parastomal hernias, the mesh can be placed as an onlay (above the fascia) or as an underlay. The underlay position can be placed intraperitoneally, preperitoneally, or behind the rectus muscle anterior to the posterior rectus fascia, or as a sandwich. Each of these positions has their own advantages and disadvantages. Very low long-term recurrence rates have been achieved by using Stoppa's technique for repairing complex hernias with the retrorectus mesh positioning [14].

In concomitant hernias, the incisional hernia usually occurs early and develops faster, and therefore has larger defects. Due to its position at the median line or very near to the median line, the incisional hernia is faced with higher intraabdominal pressure. When repairing the incisional hernia with the sublay technique, we have summarized the following surgical techniques. The previous scars on the surface of incisional hernia should be resected, and the sutures should be removed. The adhesions of the hernia sac should be released. Along the posterior rectus sheath, the fascial space was dissected with 3–5 cm larger than the hernia margin. Very large sacs were trimmed and then the peritoneum was sutured to reestablish its integrity. The bowel was not exposed and contacted by the mesh. The preperitoneal space was dissected with at least 5 cm larger than the hernia margin. The mesh was fixed onto the peritoneum with 000 absorbable sutures. The fascial defects were closed as much as possible. The mesh was also fixed onto the hernia margin with 00 Prolene suture to avoid disposition or bulging of the mesh.

References:

1. Chowbey PK, Sharma A, Khullar R et al: Laparoscopic ventral hernia repair. *J Laparoendosc Adv Surg Tech A*, 2000; 10(2): 79–84
2. Cocozza E, Berselli M, Latham L et al: Laparoscopic repair of ventral hernia in a laparoscopic experienced surgical center: low recurrence rate, morbidity, and chronic pain are achievable. *Surg Laparosc Endosc Percutan Tech*, 2014; 24(2): 168–72
3. Lambrecht JR, Skauby M, Trondsen E et al: Laparoscopic repair of incisional hernia in solid organ-transplanted patients: the method of choice? *Transpl Int*, 2014; 27(7): 712–20
4. Moazzez A, Mason RJ, Darehzereshki A et al: Totally laparoscopic abdominal wall reconstruction: lessons learned and results of a short-term follow-up. *Hernia*, 2013; 17(5): 633–38

When repairing the parastomal hernia with the onlay technique, it is important to adequately dissect the hernia sac, stoma, and the bowel. The bulged bowel was reduced back into the abdominal cavity. Excessive sac was resected and no subcutaneous bowel was left to prevent recurrence caused by defecation. The fascial defects were closed to provide additional enforcement. The mesh was placed before the fascia and was prone to detachment and recurrence, which was caused by the impact of suddenly increased intraabdominal pressure. Without fascia as the first barrier at the defects, the recurrence rate can be very high. In our patients, the defect area was closed using 1-0 Prolene suture for better enforcement and tension. The mesh was effectively fixed onto the fascia at the inner and outer rims of mesh using 2-0 Prolene suture.

The parastomal hernia has some distinct features that are different from the incisional hernia. The repair of parastomal hernia should consider the functions of the stoma. The space between the bowel and the stoma should be closed to avoid recurrence. The inner diameter of the stomal bowel should be 2–3 cm. Smaller inner diameter of the bowl may compress the bowel, and even cause fistula if the bowel contacts the mesh. Larger inner diameter of the bowel may lead to occurrence of new hernia of the intestine. Intraoperative manipulation should be gentle to avoid damages to bowels, nerves, and vessels. Damage to the vessels beneath the abdominal wall may cause muscular atrophy and weakness, leading to hernia recurrence. Damage to the vessels of the bowel may cause intestinal necrosis. Excessive manipulation of the bowel may contamination of the surgical area by the bowel contents. Excessive dissection should be avoided intraoperatively. Careful hemostasis should be maintained during the surgery.

Conclusions

In conclusion, this hybrid technique of sublay and onlay is effective in simultaneous repair of concomitant incisional and parastomal hernias.

Conflict of Interest

The authors declare no conflict of interest.

5. Kreis BE, de Mol van Otterloo AJ, Kreis RW: Open abdomen management: a review of its history and a proposed management algorithm. *Med Sci Monit*, 2013; 19: 524–33
6. Moreno-Egea A, Martinez JA, Girela E et al: Anatomical and surgical study of totally extraperitoneal laparoscopic hernioplasty. *Med Sci Monit*, 2005; 11(3): CR127–31
7. Egun A, Hill J, MacLennan I et al: Preperitoneal approach to parastomal hernia with coexistent large incisional hernia. *Colorectal Dis*, 2002; 4(2): 132–34
8. Rosen MJ, Reynolds HL, Champagne B et al: A novel approach for the simultaneous repair of large midline incisional and parastomal hernias with biological mesh and retrorectus reconstruction. *Am J Surg*, 2010; 199(3): 416–20; discussion 420–21
9. Hogg ME, King PM, Keenan RA: A modified lateral approach to parastomal hernia repair. *Surgeon*, 2009; 7(1): 56–58
10. Berger D: Prevention of parastomal hernias by prophylactic use of a specially designed intraperitoneal onlay mesh (Dynamesh IPST). *Hernia*, 2008; 12(3): 243–46
11. Longman RJ, Thomson WH: Mesh repair of parastomal hernias – a safety modification. *Colorectal Dis*, 2005; 7(3): 292–94
12. Petersson P, Montgomery A, Petersson U: Wound dehiscence: outcome comparison for sutured and mesh reconstructed patients. *Hernia*, 2014; 18(5): 681–89
13. Carne PW, Robertson GM, Frizelle FA: Parastomal hernia. *Br J Surg*, 2003; 90(7): 784–93
14. Stoppa RE: The treatment of complicated groin and incisional hernias. *World J Surg*, 1989; 13(5): 545–54