

# Acute pancreatitis and development of pancreatic pseudo cyst after extra corporeal shock wave lithotripsy to a left renal calculus: A rare case with review of literature

Prasad Mylarappa, Tarun Javali, Prathvi, D. Ramesh

Department of Urology, MS Ramaiah Medical College and Hospital, Bangalore, Karnataka, India

## ABSTRACT

Extracorporeal shock wave lithotripsy (SWL) is considered the standard of care for the treatment of small upper ureteric and renal calculi. A few centers have extended its use to the treatment of bile duct calculi and pancreatic calculi. The complication rates with SWL are low, resulting in its wide spread acceptance and usage. However, some of the serious complications reported in 1% of patients include acute pancreatitis, perirenal hematoma, urosepsis, venous thrombosis, biliary obstruction, bowel perforation, lung injury, rupture of aortic aneurysm and intracranial hemorrhage. To our knowledge, only six cases of acute pancreatitis or necrotizing pancreatitis following SWL have been documented in the literature. Herein, we report a rare case of acute pancreatitis and formation of a pseudo cyst following SWL for left renal pelvic calculus.

**Key words:** Extracorporeal shock wave lithotripsy, pancreatitis, pseudocyst of pancreas

## INTRODUCTION

Extracorporeal shock wave lithotripsy (SWL) is one of the most common urological procedures performed today and it is believed that shock waves used are safe for soft-tissues or organs. Its effectiveness, ease of use and non-invasive nature has made it to be the procedure of choice for small renal and upper ureteric calculi.<sup>[1]</sup> At the same time, a number of side-effects and complications are being increasingly recognized with its wide spread use.<sup>[2]</sup> We treated a young patient with SWL for left renal pelvic calculus who developed acute pancreatitis with pseudo cyst formation. This case is rare as only two similar cases have been reported in the literature.

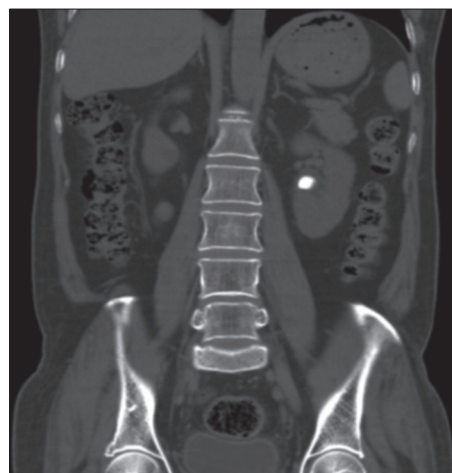
**For correspondence:** Dr. D. Ramesh, Department of Urology, MS Ramaiah Medical College and Hospital, Bangalore - 560 054, Karnataka, India.  
E-mail: arunacr1@gmail.com

### Access this article online

Quick Response Code:	Website: www.indianjurol.com
	DOI: 10.4103/0970-1591.124219

## CASE REPORT

A 21-year-old gentleman was referred to us with the history of intermittent left flank pain of 2 weeks duration. He had no previous history of biliary lithiasis, alcohol consumption or abdominal surgeries. Computed tomography (CT) Kidneys, Ureter, Bladder showed a left renal pelvic calculus of 10 mm × 8 mm without any hydronephrosis [Figure 1]. No other abnormality was detected on the CT scan. His blood chemistry and urine analysis were normal. SWL (Dornier Compact Delta, Germany) was performed at 15 kv with 60



**Figure 1:** Non contrast computed tomography Kidneys, Ureter, Bladder (coronal section) showing left renal pelvic calculus

shocks per minute for a total of 2700 shock waves, using fluoroscopic guidance.

Approximately 24 h after SWL, he developed severe pain in the epigastrium and peri-umbilical regions with persistent vomiting. On physical examination, he had tachycardia and was tachypnoeic. Blood pressure was 130/80 mmHg. His abdomen was distended and mild guarding in the epigastrium and periumbilical region was present. On biochemical evaluation, he had an increase in white blood cells count ( $17 \times 10^3 \mu/L$ ), renal and liver function tests were within normal limits. X-ray abdomen and X-ray chest were normal. Ultrasound showed minimal peri-pancreatic fluid collection. Rest of the abdomen was normal. Serum amylase was 1165  $\mu/L$  (normal range: 30-110  $\mu/L$ ) and serum lipase was 8625  $\mu/L$  (normal range 15-322). CT scan of abdomen done 48 h after the onset of pain showed features of acute pancreatitis with inflammatory exudate in the peri-pancreatic space, sub-hepatic space and pelvis and minimal left pleural effusion [Figures 2 and 3]. There was no evidence of pancreatic necrosis in the contrast enhanced CT scan. Blood and urine culture reports revealed no growth.

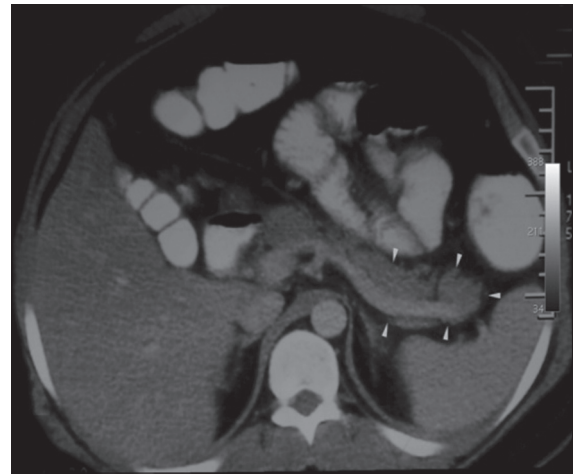
He was treated conservatively with nasogastric tube insertion, bowel rest, parenteral nutrition, intravenous antibiotics and intravenous somatostatin. His pancreatic enzymes returned to normal within 5 days and follow-up CT scan performed 2 months after the acute episode showed the resolution of features of acute pancreatitis with the formation of pseudo cyst in the body and tail of pancreas measuring 12 cm  $\times$  8 cm  $\times$  8 cm [Figure 4]. No residual fragment of renal calculus was found in the follow up CT scan. Later he underwent surgery for persistent pseudocyst of pancreas.

## DISCUSSION

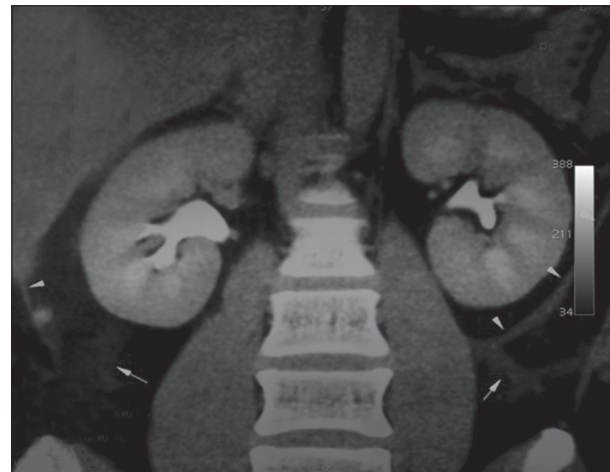
SWL is generally accepted as an effective, non-invasive treatment for a wide range of upper urinary tract stones.<sup>[3]</sup> The popularity of SWL increased since its introduction to clinical use in the 1980's. Adjacent organ injury is reported to occur in less than 1% of patients.<sup>[2,4]</sup>

Serious complication for SWL include pulmonary contusion, cardiac arrhythmia, new onset diabetes mellitus, gastric erosions, aortic aneurysmal rupture, portal and iliac vein thrombosis, biliary obstruction, colonic and splenic injury, bowel perforation and severe acute pancreatitis.<sup>[5-8]</sup>

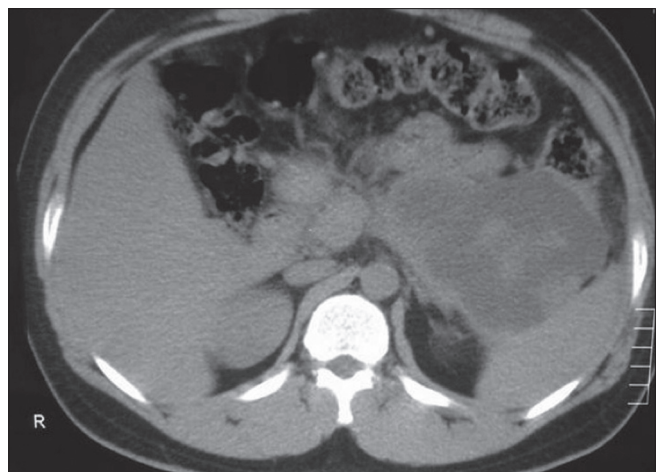
Few isolated reports of acute pancreatitis following SWL exist in literature, but the exact mechanism of pancreatitis is not known. Out of six cases of acute pancreatitis/necrotizing pancreatitis following SWL reported in literature, four cases were following SWL to a right renal calculus, one case following lithotripsy to bilateral renal calculi and one case following lithotripsy to left renal calculus. Our case was unique as the patient developed acute pancreatitis



**Figure 2:** Arrow heads showing a bulky tail of pancreas. There was no evidence of pancreatic necrosis. There is loss of fat plane between pancreas and surrounding tissues



**Figure 3:** Arrow heads showing thickened pararenal fascia and arrows showing retroperitoneal edema fluid



**Figure 4:** Follow-up computed tomography scan performed after 2 months showed pancreatic pseudocyst involving body and tail of pancreas

and formation of pseudocyst following SWL to left renal calculus.

SWL is known to cause pancreatic injury because pancreatic enzymes are elevated following the procedure.<sup>[2]</sup> Shock waves can cause small hematoma and microvascular damage to the pancreas.<sup>[7]</sup> SWL might cause biliary pancreatitis due to inadvertent fragmentation of gall stones or common bile duct stones causing pancreatic duct obstruction.<sup>[9]</sup> The sequence of development of acute pancreatitis following SWL, in the absence of any of the predisposing factors such as gall stone, alcohol, hypercalcemia and prior abdomen surgery, supports a causal relationship in our patient. Abe *et al.* suggested post procedure adhesions between the pancreas and surrounding tissue as a cause for mechanical injury resulting in pancreatitis following SWL.<sup>[5]</sup> Another hypothesis is that infected urine leak from the renal pelvis can cause pancreatitis.<sup>[5]</sup> In our case, the result of urine analysis and urine culture sensitivity was normal.

Cellular damage caused by cavitation and attending shear forces, which are produced by the shock waves as they pass through the surrounding tissue support cause of pancreatic injury following SWL.<sup>[6]</sup> Shock-wave induced soft-tissue injury has been reported as a direct effect of the sonic pulsation or as a result of the process of cavitation, in which rapid expansion and collapse of tiny air bubble induced by the shock wave injure the adjacent tissue.<sup>[10]</sup> This is the most plausible theory to explain how adjacent organ injury might develop during SWL. Gulum<sup>[11]</sup> found a positive correlation between the number of shock waves and raise in pancreatic enzymes following ESWL to right kidney but not in the left kidney. Hassan<sup>[6]</sup> *et al.* also proposed that the delivered number and intensity of shock waves could be a possible etiological factor as their affected patient received a greater number of shocks than routinely used. However, in our case, only one setting of 2,700 shocks was given and the intensity level was standard.

Acute pancreatitis following SWL generally responds well to conservative treatment unless complicated by extensive necrosis and formation of extensive fluid collection around the pancreas. Our patient showed good improvement after conservative treatment with bowel rest, gastric decompression, intravenous fluids, intravenous antibiotics, proton pump inhibitors and somatostatin. Pseudocyst formation, which appeared following pancreatitis and persisted, was treated by surgery.

## CONCLUSION

Although SWL has been established as a safe and effective

modality of treatment, serious complications can occur with significant adjacent organ injury. Hence, one should be aware of such rare complications as prompt diagnosis and essential treatment can prevent significant morbidity and death.

## REFERENCES

1. Newmark JR, Wong M, Lingeman JE. Complications. In: Smith AD, editor. *Smith's Textbook of Endourology*. St. Louis: Quality Medical Publishing; 1996. p. 681-93.
2. Conlin MJ. Complications of extracorporeal shock wave lithotripsy. In: Taneja SS, Smith RB, Ehrlich RM, editors. *Complications of Urologic Surgery*. Philadelphia: WB Saunders; 2001. p. 155-64.
3. Rassweiler JJ, Köhrmann KU, Seemann O, Tschada R, Alken PM. Clinical comparison of ESWL. In: Coe FL, Favus MJ, Pak CY, Parks JH, Preminger GM, editors. *Kidney Stones: Medical and Surgical Management*. Philadelphia: Lippincott-Raven Publishers; 1996. p. 571-605.
4. Zhong P, Preminger GM. Physics of shock-wave lithotripsy. In: Coe FL, Favus MJ, Pak CY, Parks JH, Preminger GM, editors. *Kidney Stones: Medical and Surgical Management*. Philadelphia: Lippincott-Raven Publishers; 1996. p. 529-48.
5. Abe H, Nisimura T, Osawa S, Miura T, Oka F. Acute pancreatitis caused by extracorporeal shock wave lithotripsy for bilateral renal pelvic calculi. *Int J Urol* 2000;7:65-8.
6. Hassan I, Zietlow SP. Acute pancreatitis after extracorporeal shock wave lithotripsy for a renal calculus. *Urology* 2002;60:1111.
7. Lazarides MK, Drista H, Arvanitis DP, Dayantas JN. Aortic aneurysm rupture after extracorporeal shock wave lithotripsy. *Surgery* 1997;122:112-3.
8. Geh JL, Curley P, Mayfield MP, Price JJ. Small bowel perforation after extracorporeal shock wave lithotripsy. *Br J Urol* 1997;79:648-9.
9. Hung SY, Chen HM, Jan YY, Chen MF. Common bile duct and pancreatic injury after extracorporeal shock wave lithotripsy for renal stone. *Hepatogastroenterology* 2000;47:1162-3.
10. Ell C, Kerzel W, Heyder N, Rödl W, Langer H, Mischke U, *et al.* Tissue reactions under piezoelectric shockwave application for the fragmentation of biliary calculi. *Gut* 1989;30:680-5.
11. Gulum M, Yeni E, Savas M, Celik H, Ciftci H. Do the applied shock wave numbers and the application side-affect pancreatic exocrine functions in patients who have undergone extracorporeal shock wave lithotripsy for upper urinary tract calculi? *Turk J Med Sci* 2012;42:591-6.

**How to cite this article:** Mylarappa P, Javali T, P, Ramesh D. Acute pancreatitis and development of pancreatic pseudo cyst after extra corporeal shock wave lithotripsy to a left renal calculus: A rare case with review of literature. *Indian J Urol* 2014;30:110-2.

**Source of Support:** Nil, **Conflict of Interest:** None declared.