



Since January 2020 Elsevier has created a COVID-19 resource centre with free information in English and Mandarin on the novel coronavirus COVID-19. The COVID-19 resource centre is hosted on Elsevier Connect, the company's public news and information website.

Elsevier hereby grants permission to make all its COVID-19-related research that is available on the COVID-19 resource centre - including this research content - immediately available in PubMed Central and other publicly funded repositories, such as the WHO COVID database with rights for unrestricted research re-use and analyses in any form or by any means with acknowledgement of the original source. These permissions are granted for free by Elsevier for as long as the COVID-19 resource centre remains active.

Abstract:

We present a 6-month-old boy with failure to thrive who was referred to the emergency department by his primary care doctor for leukocytosis and was found to be hypoxic with diffuse infiltrates on chest radiograph. Our patient was admitted and eventually diagnosed with *Pneumocystis jirovecii* pneumonia secondary to hyper immunoglobulin M syndrome. Even though *P jirovecii* pneumonia is an uncommon cause of hypoxia in infants, this case illustrates the need for pediatric emergency physicians to be cognizant of this rare but life threatening cause of hypoxia.

Keywords:

hypoxia; hyper immunoglobulin M syndrome; *Pneumocystis jirovecii* pneumonia

Presented during the American Academy of Pediatrics (AAP) Section on Emergency Medicine Emergi-Quiz Case Competition held at the AAP National Convention and Exhibition, San Diego, CA, October 2014. Reprint requests and correspondence: Ji Won Kim, MD, Yale University School of Medicine, 100 York Street - Suite 1F, New Haven, CT 06511.

JiWon.Kim.jk969@yale.edu

1522-8401

© 2015 Elsevier Inc. All rights reserved.

From White Count to White Out

Ji Won Kim, MD

A 6-month-old male infant with failure to thrive was referred by his pediatrician to a tertiary care pediatric emergency department (ED) for further evaluation of leukocytosis. He was seen 3 days prior for a well child check where a complete blood count drawn revealed a white blood cell count of 35 000/ μ L.

Upon arrival to the ED, the infant was noted to be in mild respiratory distress. He had a rectal temperature of 37.3°C, a heart rate of 176 beats per minute, and a respiratory rate of 48 breaths per minute. Oxygen saturation measured by pulse oximetry was 53% on room air.

On physical exam, he was active and vigorous. He had an open and flat anterior fontanelle, moist mucous membranes, and a clear oropharynx. He was tachycardic, but his cardiovascular exam did not reveal any murmurs. His lungs were clear to auscultation bilaterally without any wheezes, crackles, or rhonchi, and he was in mild respiratory distress with tachypnea. His abdomen was soft, nontender and nondistended with no organomegaly. His skin was warm and well perfused, and his neurological examination was normal.

Upon arrival to the ED, the patient was immediately placed on a nonrebreather oxygen mask with flow of 10 L/min, with an immediate improvement in oxygen saturation, which rose to the high 90s. Intravenous (IV) lines were placed and laboratory studies were sent. A complete blood count revealed a white blood cell count of 48,100/ μ L (15% neutrophils, 71% lymphocytes, 5% monocytes, 3% eosinophils), hemoglobin of 13.8 g/dL, hematocrit of 43%, and a platelet count of 528,000/ μ L. A chest radiograph was obtained and is shown in the [Figure](#). An electrocardiogram obtained in the ED showed sinus tachycardia and was interpreted as being otherwise normal.

After initial stabilization, further history was obtained. The patient was a full term baby born via normal spontaneous vaginal

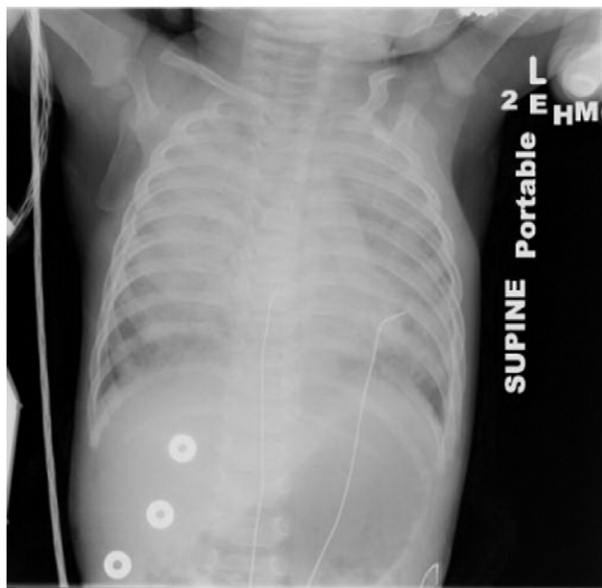


Figure. Chest radiograph obtained in the ED demonstrating bilateral infiltrates.

delivery. He was born to a 22-year-old mother with negative serologies and negative for HIV with no concerns during her pregnancy. Past medical history was significant for respiratory syncytial virus bronchiolitis at 4 months of age, which did not require hospitalization. He had recently been found to have failure to thrive by his pediatrician. The patient did not have any past surgical history, home medications, or allergies. The family history was notable for a great grandfather with seizure disorder but was otherwise unremarkable.

On review of systems per mother, he had exhibited decreased activity for the past 1.5 weeks, with mild coughing and congestion, and no increased work of breathing. He otherwise had normal oral intake and urine output. His mother denied the presence of fevers, emesis, or diarrhea.

The social history revealed that the child lives in a 2-bedroom condominium with his mother, 8-year-old uncle, and maternal grandmother. He does not attend daycare. His home had a recent basement flooding. There are no pets in the home. He had a brief contact with the maternal grandmother's boyfriend, who was recently incarcerated.

In the ED, after obtaining cultures, he was given IV ceftriaxone and admitted to the inpatient pediatric unit on 2 L/min of oxygen via nasal cannula. On the inpatient unit, he had intermittent episodes of increasing tachypnea and grunting; azithromycin was added to his antimicrobial regimen. Within 12 hours of admission, he was transferred

to the pediatric intensive care unit for worsening respiratory distress.

DIFFERENTIAL DIAGNOSIS

Hypoxia in an infant has many potential causes. These include common etiologies such as viral bronchiolitis, pneumonia, and airway obstruction. Rare causes, such as pneumonia from atypical agents from an undiagnosed immunodeficiency, congenital heart disease, methemoglobinemia, and pulmonary malformations, should be entertained as possible components of the differential diagnosis in the ED. In this child, the differential diagnosis narrows significantly to a pulmonary etiology in a patient who had infiltrates on chest radiograph and whose respiratory distress and hypoxia responded readily to supplemental oxygen, making the diagnosis of congenital heart disease unlikely.

Viral bronchiolitis is one of the most common causes of hypoxia and respiratory distress in infants, especially in the fall and winter. Bronchiolitis is a lower airway disease mostly affecting the bronchioles, causing acute inflammation, edema, increased mucus production, and bronchospasm. Viral bronchiolitis typically presents with upper respiratory symptoms followed by lower respiratory infection resulting in wheezing and rales in children younger than two years of age. Common pathogens of viral bronchiolitis include respiratory syncytial virus, rhinovirus, parainfluenza virus, human metapneumovirus, influenza, adenovirus, and coronavirus. Findings on a chest radiograph are almost always nonspecific but may include hyperinflation, peribronchial thickening, and patchy atelectasis. Bronchiolitis is therefore a clinical diagnosis; quality improvement guidelines typically discourage the routine use of imaging. The causative agent may be confirmed by antigen detection or immunofluorescence of respiratory secretions, and treatment is mainly supportive.¹

Pneumonia is another common cause of hypoxia and respiratory distress in children and can be the result of both bacterial and viral infections. Patients often present with cough and fever, and may also present with tachypnea, hypoxia, or respiratory distress. Physical exam may reveal crackles, decreased breath sounds over areas of consolidation, rhonchi, or wheezing. Though viral pneumonia is more common in infants, bacterial pathogens such as *Streptococcus pneumoniae*, *Staphylococcus aureus*, and *Streptococcus pyogenes* may also cause pneumonia in infants, with *Streptococcus pneumoniae* being the most common pathogen. Chest radiograph typically reveals a focal area of consolidation. In older school-

aged children, *Mycoplasma pneumoniae* and *Chlamydia pneumoniae* are also common pathogens. Aspiration pneumonia should also be considered in patients at risk, particularly in children with a seizure disorder, gastroesophageal reflux disease, depressed mental status, neurologic disease, or dysphagia. Aspiration pneumonia can be caused by anaerobic oral flora including anaerobic *Streptococci*, *Fusobacterium spp*, *Bacteroides spp*, and *Prevotella melanizingenica* and need to be appropriately covered with antibiotics that are effective against anaerobic bacteria.

Organizing pneumonia, also known as bronchiolitis obliterans organizing pneumonia, also presents with cough, dyspnea, and hypoxia. A variety of illnesses including pulmonary infections, inhalation of toxic fumes, rheumatologic diseases, bone marrow or heart and lung transplantation causes inflammation and fibrosis in the bronchioles, which leads to concentric luminal narrowing. Physical examination typically reveals fine crackles on auscultation. Chest radiograph may reveal scattered, bilateral alveolar opacities and ground glass opacification, non-segmental consolidations, or nodules. However, due to nonspecific findings on standard chest imaging, high-resolution computed tomography is usually performed prior to lung biopsy to establish the diagnosis. Treatment is with glucocorticoids.²

Tuberculosis, caused by *Mycobacterium tuberculosis*, is another reason for hypoxia in infants. According to the Centers for Disease Control and Prevention, at least half a million children develop tuberculosis annually worldwide. Risk for tuberculosis increases with being foreign born, close contact with a person with tuberculosis, homelessness, using injection drugs, living in a correctional facility or nursing home, or working in the hospital. Pulmonary tuberculosis presents with chronic cough, fever, and failure to thrive. Diagnosis is made with history of recent close contact, positive tuberculin skin test, and chest radiograph findings, which may demonstrate lymphadenopathy, infiltrate, consolidations, or cavitations. Sputum microscopy is the gold standard for definitive diagnosis, but difficult to obtain in children. Treatment for active tuberculosis disease consists of isoniazid, rifampin, ethambutol, and pyrazinamide for a total of 6 to 9 months.³

Bordetella pertussis, also known as “whooping cough”, is a contagious respiratory disease that is vaccine preventable. Pertussis typically presents with cold-like symptoms in the catarrhal phase for 1-2 weeks followed by the paroxysmal phase, which is characterized by coughing fits and gasping or whooping that can last from 1 to 10 weeks. Finally, patients enter the convalescent phase that lasts 2-3 weeks. However, infants with pertussis may present

atypically. They may present with feeding difficulty, tachypnea, apnea, post-tussive emesis, and cough, which may or may not be followed by the classic “whoop”. Chest radiographs may show perihilar infiltrates, peribronchial cuffing, or may appear to be normal. Diagnosis is made clinically but may be confirmed with culture or polymerase chain reaction (PCR) tests. Pertussis is treated with azithromycin, clarithromycin, or erythromycin.

Congenital pulmonary airway malformation (CPAM) is a rare congenital malformation of the lower airways, with an incidence ranging from 1 to 4 per 35,000 live births. CPAM is caused by branching morphogenesis abnormalities in the lung resulting in cystic and adenomatous lesions in the tracheal, bronchial, bronchiolar, or alveolar tissue. If not discovered during prenatal ultrasound, most patients present in the neonatal period with respiratory distress, recurrent pneumonia, and cyanosis. Chest radiograph may appear normal and the diagnosis may be missed. Chest computed tomography may show small and large air or fluid filled cysts. Treatment of symptomatic CPAM is surgical resection.⁴

Methemoglobinemia is another cause of cyanosis and can be congenital or acquired. In congenital methemoglobinemia, there is a deficiency in the hemoglobin structure or abnormalities in key enzymes that reduce naturally occurring methemoglobin. Type II congenital methemoglobinemia is a more severe form in which all cells are affected, and patients may present with cyanosis, mental retardation, developmental delay, and failure to thrive. Acquired methemoglobinemia can be due to stress or exogenous causes including environmental and drug exposures. Patients can present with cyanosis, dyspnea, lethargy, or irritability, which can lead to respiratory depression, altered mental status, shock, seizures, and death. Methemoglobinemia is characterized by cyanosis in the setting of normal oxygen saturation and the blood of affected patients has been described as dark red, chocolate, or brown in color. Routine pulse oximetry should not be used to diagnosis methemoglobinemia as it is inaccurate and co-oximetry should be used instead. Treatment is with IV methylene blue.

The age of onset for this patient should also prompt physicians to consider primary or acquired immunodeficiency. Given the mother's negative HIV status, primary immunodeficiency resulting in an opportunistic infection is high on the differential. In addition to common respiratory pathogens, immunocompromised children are at risk for other opportunistic pathogens as well, including *Aspergillus*, *Pneumocystis jirovecii*, *Cytomegalovirus*, and Epstein-Barr virus.

CASE PROGRESSION AND DIAGNOSIS

Upon admission to the pediatric intensive care unit, the patient was placed on noninvasive positive pressure ventilation for worsening respiratory distress. Direct fluorescence antibody testing of respiratory secretions for respiratory viruses and pertussis PCR were negative. Laboratory tests revealed an immunoglobulin (Ig) M level of 503 mg/dL (reference, 21-171 mg/dL), IgG of 109 mg/dL (124-925 mg/dL), and IgA of 14 mg/dL (8-114 mg/dL). Flow cytometry of peripheral blood was normal. His tetanus antibody titer was <0.1 IU/mL (>0.15 IU/mL). The diagnosis hyper IgM syndrome was confirmed by CD40 ligand (CD40L) genetic testing. He underwent a bronchoscopy and bronchoalveolar lavage that confirmed *Pneumocystis jirovecii* pneumonia (PCP). He was started on IV trimethoprim-sulfamethoxazole.

The patient continued to require increasing respiratory support for profound hypoxia. He was placed on an oscillator and subsequently placed on extracorporeal membrane oxygenation for 3 weeks. He was eventually extubated and discharged home. For his Hyper IgM syndrome, he is receiving multiple IV immunoglobulin infusions. He continues to be followed by allergy/immunology and hematology/oncology subspecialists as an outpatient and is being prepared for hematopoietic stem cell transplant.

DISCUSSION

There are numerous primary immunodeficiencies and Hyper IgM syndrome is one type of a primary cellular immunodeficiency. Hyper IgM syndrome results from defective enzymes that usually facilitate class-switch recombinations of immunoglobulins. CD40L allows T lymphocytes to induce B lymphocytes to undergo class switching from IgM to IgG, IgA, and IgE, and therefore, these defects result in increased levels of IgM and consequently decreased IgG, IgA, and IgE.⁵ It is most commonly inherited as an X-linked trait due to mutations in the CD40L gene. Female carriers are usually clinically healthy. Hyper IgM syndrome is rare with the estimated frequency of 2 in 1 000 000 male patients.

PCP is thought to be a fungus that is one of the most frequent and serious opportunistic infections in immunocompromised patients including those with primary immune deficiency, HIV, or patients on chemotherapy or other immunosuppressant. PCP rarely occurs in patients without immunodeficiency.

Clinical Presentation

Patients typically present with recurrent upper and lower respiratory tract infections, diarrhea

associated with failure to thrive, and opportunistic infections. They may also present with liver diseases such as sclerosing cholangitis secondary to opportunistic infections, such as cryptosporidium or cytomegalovirus. Over 75% of patients present within the first year of life with symptoms of immunodeficiency and over 90% present within the first 4 years of life.^{6,7}

PCP is one of the opportunistic infections with which patients with Hyper IgM syndrome may present. Fever, tachypnea, and hypoxia are the most common symptoms of PCP.⁸ Onset of symptoms may be nonspecific and include poor feeding, diarrhea, weight loss, and dyspnea. Of note, lung examination may be normal despite hypoxia and significant pneumonia, as was seen in our patient.

Diagnostic Testing


In a male with an opportunistic infection and low IgG and high IgM levels, the diagnosis of Hyper IgM syndrome is almost certain. This can be confirmed by genetic testing in newborns and infants and also can be confirmed by in vitro demonstration of impaired expression of CD40L on the surface of CD4+ T cells. Anti-CD40L monoclonal antibodies may also be helpful. Mutation analysis provides the final confirmation of Hyper IgM syndrome.

The chest radiograph in PCP is characterized by diffuse bilateral perihilar interstitial infiltrates though it may be normal in the early stages.⁹ Although induced sputum analysis may be effective in isolating PCP in older children or adults, bronchoscopy with bronchoalveolar lavage is the diagnostic test of choice. This may be positive for up to 72 hours after PCP treatment is initiated with sensitivity ranging from 55 to 97%. Therefore, treatment should not be withheld prior to definitive diagnosis if there is clinical suspicion.

Treatment and Outcome

Treatment of Hyper IgM syndrome with routine IV immunoglobulin therapy decreases the number of infectious episodes.¹⁰ Patients should also receive prophylaxis against PCP with trimethoprim-sulfamethoxazole as well as good hygiene to prevent infections with cryptosporidium. Hematopoietic stem cell transplant is the only curative treatment.⁶ Median survival after hematopoietic stem cell transplant is less than 25 years. The most common causes of mortality include PCP, liver disease from cryptosporidium, and carcinomas of the liver and gastrointestinal tracts.¹⁰ Trimethoprim-sulfamethoxazole is the treatment of choice for PCP. Mortality rate of PCP in immunocompromised patients ranges from 5 to 40% if treated and approaches 100% if untreated.^{11,12}

SUMMARY

Although primary immunodeficiencies such as Hyper IgM syndrome are rare, it is important to recognize rare but life-threatening presentations of opportunistic infections in patients with previously undiagnosed primary immunodeficiency. It is also important to consider primary or acquired immunodeficiency when patients present with failure to thrive as well as severe infection at the nadir of maternal antibodies, usually around 6 months of age. When immunodeficiency is suspected, clinicians should consider prompt treatment for likely opportunistic infections. 

REFERENCES

1. American Academy of Pediatrics Subcommittee on Diagnosis and Management of Bronchiolitis. Diagnosis and management of bronchiolitis. *Pediatrics* 2006;118:1774–93.
2. Al-Ghanem S, Al-Jahdali H, Bamefleh H, et al. Bronchiolitis obliterans organizing pneumonia: pathogenesis, clinical features, imaging and therapy review. *Ann Thorac Med* 2008;3:67–75.
3. Stop TB Partnership, Childhood TB Subgroup, World Health Organization. Guidance for national tuberculosis programmes on the management of tuberculosis in children. Chapter 1: introduction and diagnosis of tuberculosis in children. *Int J Tuberc Lung Dis* 2006;10:1091–7.
4. Shanti CM, Klein MD. Cystic lung disease. *Semin Pediatr Surg* 2008;17:2–8.
5. Davies EG, Thrasher AJ. Update on the hyper immunoglobulin M syndromes. *Br J Haematol* 2010;149:167–80.
6. Johnson J, Filipovich AH, Zhang K. X-linked hyper IgM syndrome. In: Pagon RA, Adam MP, Ardinger HH, et al, editors. *GeneReviews(R)*. Seattle, WA: University of Washington; 1993.
7. Winkelstein JA, Marino MC, Ochs H, et al. The X-linked hyper-IgM syndrome: clinical and immunologic features of 79 patients. *Medicine (Baltimore)* 2003;82:373–84.
8. Miller ML, Algayed IA, Yogev R, et al. Atypical *Pneumocystis carinii* pneumonia in a child with hyper-IgM syndrome. *Pediatr Pathol Lab Med* 1998;18:71–8.
9. Milledge J, Kakakios K, Gillis J, et al. *Pneumocystis carinii* pneumonia as a presenting feature of X-linked hyper-IgM syndrome. *J Paediatr Child Health* 2003;39:704–6.
10. Levy J, Espanol-Boren T, Thomas C, et al. Clinical spectrum of X-linked hyper-IgM syndrome. *J Pediatr* 1997;131:47–54.
11. Hughes WT, Feldman S, Sanyal SK. Treatment of *Pneumocystis carinii* pneumonitis with trimethoprim-sulfamethoxazole. *Can Med Assoc J* 1975;112:47–50.
12. Benson CA, Kaplan JE, Masur H, et al. Treating opportunistic infections among HIV-infected adults and adolescents: recommendations from CDC, the National Institutes of Health, and the HIV Medicine Association/Infectious Diseases Society of America. *MMWR Recomm Rep* 2004;53:1–112.