

Disappearance of the blood supply to a giant uterine myoma due to childbirth

A CARE-compliant article

Lu-Jing Li, MD^a, Xuan-Kun Liang, BA^a, Xian-Xiang Wang, MD^a, Dan Zeng, MD^b, Zuo-Feng Xu, MD, PhD^{a,*}

Abstract

Rationale: Giant uterine myomas may be life-threatening due to pressure effects on the lungs and other contiguous organs.

Patient concerns: A 32-year-old pregnant Asian woman was admitted to our hospital early in her pregnancy with a pre-pregnancy history of multiple uterine myomas.

Diagnosis: She was diagnosed with multiple giant uterine myomas in pregnancy.

Interventions: No intervention was performed on the woman.

Outcomes: A reduction in tumor size and disappearance of tumor blood supply were seen on conventional and contrast-enhanced ultrasounds (CEUS) on postpartum day 34. Mass volume gradually decreased and no blood flow signals were seen on CEUS during postpartum follow-up.

Lessons: Childbirth can block the blood supply of giant uterine myomas and reduce mass size. In such cases, childbirth may be considered therapeutic.

Abbreviations: CEUS = contrast-enhanced ultrasound, US = conventional ultrasound.

Keywords: contrast-enhanced ultrasound, management, parturition, uterine giant myoma

1. Introduction

Uterine myomas are benign tumors arising from uterine smooth muscle cells and extracellular matrix, occurring in 2.3–10.7% of women in pregnancy.^[1,2] The incidence has a tendency of going up recently because of delaying in childbearing. Myomas in pregnant women are usually asymptomatic and found incidentally at clinical or ultrasound examination; however, when symptomatic, they present a variety of symptoms such as abortion, preterm delivery, abruptio placentae, intrauterine growth retardation, dystocia, and postpartum hemorrhage.^[3–6] The major complications are mainly related to the location of the myoma, and whether it is in contact with the placenta. Furthermore, women are at increased risk of bleeding and postoperative morbidity because of the increased vascularity of the uterus during pregnancy, especially with a giant uterine

myoma. A giant uterine myoma exceeds 11.4kg in weight.^[7] Its clinical presentation includes vague abdominal and back pain with abnormal vaginal bleeding. Giant uterine myomas may be life-threatening due to pressure effects on the lungs and other contiguous organs. For these reasons, controversy persists among treatment options of myoma during pregnancy.^[8] However, there have never been relevant reports about the decreasing of mass volume and of blood flow signals without any interventions after delivery. We mainly put forward a different opinion about the management of myomas for women in pregnancy.

We report the rare case of a woman with multiple uterine myomas whose largest tumor, which had gradually grown from 7.5 to 15.3 cm during her pregnancy, lost its blood supply and shrunk after delivery. We describe the color Doppler features of her uterine myomas before and during pregnancy and features on contrast-enhanced ultrasound (CEUS) after delivery.

2. Patient information

A 32-year-old woman was admitted to our hospital early in her pregnancy (at about 10 gestational weeks) with a pre-pregnancy history of multiple uterine myomas. A conventional ultrasound (US) report from another hospital 6 months pre-pregnancy described several spherical, non-homogeneous, low-echo, intramural uterine tumors with regular morphologies and distinct boundaries, with the largest measuring 7.5 cm × 7.3 cm × 6.9 cm (188.9 mL) in size.

3. Clinical findings

Physical examination revealed a hard, round, slightly mobile, midline mass palpable in the right lower abdominal quadrant. Liver function, tumor marker, biochemical, and routine blood tests were normal. US examination in our hospital indicated that

Editor: N/A.

The authors report no conflicts of interest.

^a Department of Medical Ultrasonics, The Seventh Affiliated Hospital of Sun Yat-sen University, Shenzhen, ^b Department of Medical Ultrasonics, The First Affiliated Hospital of Sun Yat-sen University, Guangzhou, Guangdong Province, China.

* Correspondence: Zuo-Feng Xu, Department of Ultrasound, The Seventh Affiliated Hospital of Sun Yat-sen University, Shenzhen, Guangdong, China (e-mail: lainxuan@aliyun).

Copyright © 2019 the Author(s). Published by Wolters Kluwer Health, Inc. This is an open access article distributed under the terms of the Creative Commons Attribution-Non Commercial-No Derivatives License 4.0 (CCBY-NC-ND), where it is permissible to download and share the work provided it is properly cited. The work cannot be changed in any way or used commercially without permission from the journal.

Medicine (2019) 98:28(e16056)

Received: 10 October 2018 / Received in final form: 23 April 2019 / Accepted: 17 May 2019

<http://dx.doi.org/10.1097/MD.00000000000016056>

the largest myoma had grown to 11.5 cm × 10.3 cm × 11.0 cm (651.5 mL), and several circular blood flow signals were found in and around it. A normal, healthy baby was seen in the uterine cavity and two normal ovaries were present as well.

4. Diagnostic assessment and therapeutic intervention

Four conventional US examinations were performed during the pregnancy. The largest tumor's maximum size was 15.1 cm × 10.3 cm × 12.1 cm (953.4 mL), and rich blood flow signals were detected in and around the tumor (Fig. 1). All related liver function, tumor marker, biochemical, and routine blood tests, and peripheral blood chromosomal examinations were normal. The fetus showed normal development.

At 37 gestational weeks, a healthy male baby was born by forceps-assisted delivery. Although the whole labor only lasted about 30 minutes, the mother lost more than 800 mL of blood. After delivery, mother and baby were safely transferred to the obstetric ward. Postpartum lochia was prolonged at 74 days, and the patient had slight anemia until it resolved. At 34 days postpartum, conventional US showed the largest uterine myoma had shrunk to approximately 11.5 cm × 9.2 cm × 11.0 cm (581.9 mL), and there were no blood flow signals within or around the myoma on color Doppler US. CEUSs were successively performed to evaluate the real microcirculation of the

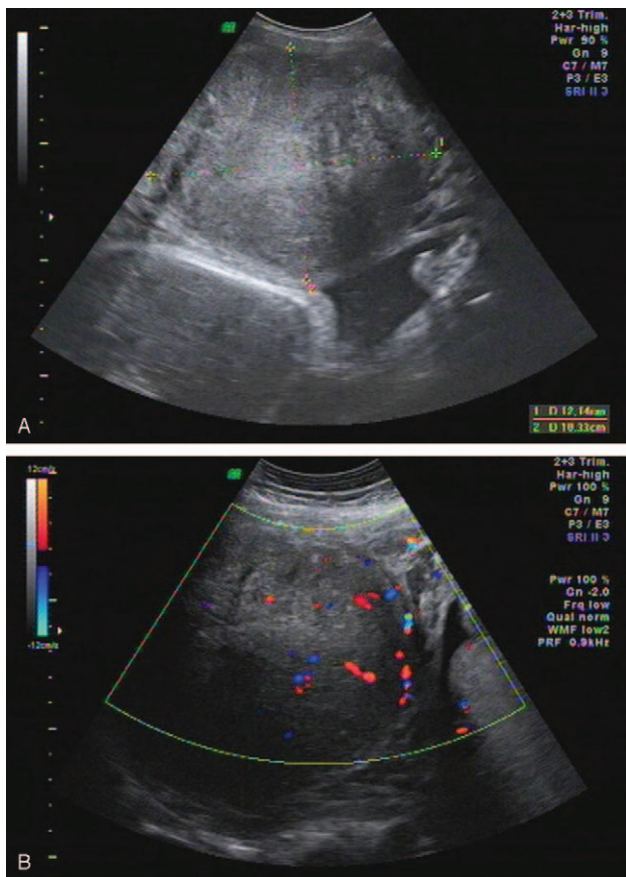


Figure 1. Conventional US was shown at 18+4 weeks. The maximum size of the tumor was 15.1 cm × 10.3 cm × 12.1 cm (953.4 mL) (A). Color Doppler US shows the circle blood flow signal within and around the uterine myoma (B).

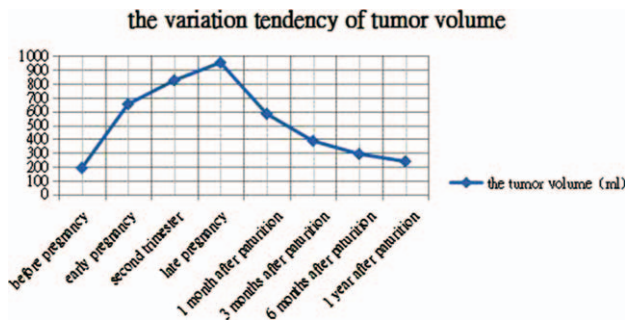


Figure 2. CEUS on postpartum day 34: the uterine myoma is consecutively non-enhanced.

largest tumor and showed non-enhancement of the whole tumor on all phases, like after ablation, and no microbubbles (Fig. 2); whereas, the other small myomas all showed homogeneous enhancement and hypervascularity. Blood tests showed slight anemia, with a red blood count of $3.95 \times 10^9/L$ ($4.3 \times 10^9/L$ – $5.8 \times 10^9/L$) and a hemoglobin level of 103 g/L (130 g/L–175 g/L).

5. Follow-up and outcomes

Traditional US and CEUS were repeated at three months, 6 months, and 1 year postpartum. All post-delivery CEUS scans showed non-enhancement, and the largest tumor's volume gradually decreased over time (Fig. 3).

Informed written consent was obtained from the patient for publication of this case report and accompanying images. Our hospital's Institutional Ethics Committee approved the case report. The authors have no commercial associations that might pose a conflict of interest.

6. Discussion

Treatment options for uterine myomas in pregnant women include expectant management, medical therapy, surgical treatment, uterine artery embolization, focused ultrasound treatment, and thermal ablation treatment. Although some studies have shown that myomectomy before or during cesarean delivery can be safely performed,^[9–11] the cases were in small numbers and there is very little information concerning the efficacy and safety of treatment performed in pregnancy. Furthermore, giant myomas are associated with an increased risk of premature delivery and blood loss at delivery. Therefore, the controversial issue is whether or not to myomectomy should be performed on the giant myomas. There has been an increasing demand for non-hysterectomy options to treat symptomatic uterine myomas. Patients' reasons for requesting conservative procedures include the desire to maintain childbearing potential, the wish to avoid major surgery, and the belief that the uterus plays a sexual role.^[12]

We described the case of a giant uterine myoma that increased dramatically in volume from 188.9 to 953.6 mL during pregnancy and then gradually shrunk and lost all blood supply following childbirth. This phenomenon has not previously been reported, but may be the result of rapidly reduced postpartum estrogen and progesterone levels. Estrogen and progesterone have been found to affect leiomyoma growth possibly through the regulating growth factors and their signaling pathways.^[13]

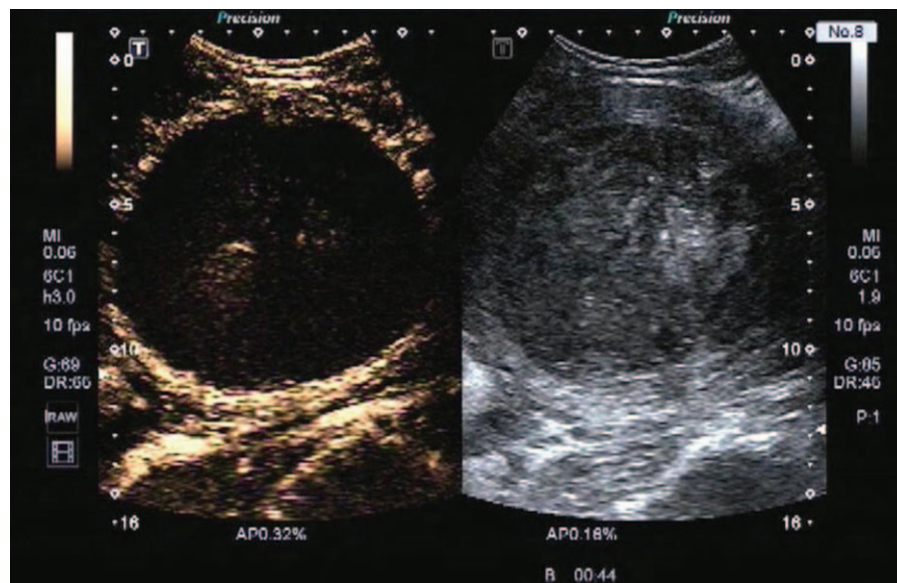


Figure 3. The variation tendency of the volume of the largest tumor was shown.

In our report, the mean increase in volume during pregnancy is much higher than the mean increase of 12% as reported in the literature.^[14] The reason may be that the volume of the myoma in our case is so giant that the vascularity of the uterus is abundant during pregnancy.

Conventional B-mode US provides information on uterine myoma location, size, and anatomical relations to surrounding organs. Color Doppler US clearly displays the distribution of large vessels within and around uterine myomas. CEUS agents enter the capillary microcirculation and show the perfusion level of target organs with a sensitivity, specificity, and spatial resolution comparable to enhanced CT and MRI studies,^[15] and can be regarded as giving index assessments of remnant lesions.^[16] Although CEUS was not performed before or during pregnancy, conventional US showed several large vessels in and around the huge myoma. To better evaluate the tumor microcirculation, CEUS was employed in the postpartum period and, besides the obvious tumor shrinkage, amazingly, the tumor showed complete non-enhancement on all phases. Furthermore, tumor shrinkage and non-vascularity were sustained for more than 1 year after delivery and may persist into the future.

In conclusion, childbirth can reduce giant uterine myoma volume and even completely block the blood supply. In that childbirth can be therapeutic for the mother, the baby could be considered the mother's angel.

Author contributions

Conceptualization: Dan Zeng.

Data curation: Xuan-Kun Liang, Zuo-Feng Xu.

Visualization: Lu-Jing Li, Xian-Xiang Wang, Dan Zeng.

Writing – original draft: Lu-Jing Li.

Writing – review & editing: Xuan-Kun Liang, Zuo-Feng Xu.

References

- [1] Qidwai GI, Caughey AB, Jacoby AF. Obstetric outcomes in women with sonographically identified uterine leiomyomata. *Obstet Gynecol* 2006;107(2 Pt 1):376–82.
- [2] Laughlin SK, Baird DD, Savitz DA, et al. Prevalence of uterine leiomyomas in the first trimester of pregnancy: an ultrasound-screening study. *Obstet Gynecol* 2009;113:630–5.
- [3] Zaima A, Ash A. Fibroid in pregnancy: characteristics, complications, and management. *Postgrad Med J* 2011;87:819–28.
- [4] Ouyang DW, Economy KE, Norwitz ER. Obstetric complications of fibroids. *Obstet Gynecol Clin N Am* 2006;33:153–69.
- [5] Benson CB, Chow JS, Chang-Lee W, et al. Outcome of pregnancies in women with uterine leiomyomas identified by sonography in the first trimester. *J Clin Ultrasound* 2001;29:261–4.
- [6] Noor S, Fawwad A, Sultana R, et al. Pregnancy with fibroids and its obstetric complication. *J Ayub Med Coll Abbottabad* 2009;21:37–40.
- [7] Jonas HS, Masterson BJ. Giant uterine tumors: case report and review of the literature. *Obstet Gynecol* 1977;50:2s–4s.
- [8] Lolis DE, Kalantaridou SN, Makrydimas G, et al. Successful myomectomy during pregnancy. *Hum Reprod* 2003;18:1699–702.
- [9] Mu YL, Wang S, Hao J, et al. Successful pregnancies with uterine leiomyomas and myomectomy at the time of caesarean section. *Postgrad Med J* 2011;87:601–4.
- [10] Three cases of laparoscopic myomectomy performed during pregnancy for pedunculated uterine myomas.
- [11] Lozza V, Pieralli A, Corioni S, et al. Multiple laparotomic myomectomy during pregnancy: a case report. *Arch Gynecol Obstet* 2011;284:613–6.
- [12] Bergamini V, Ghezzi F, Cromi A, et al. Laparoscopic radiofrequency thermal ablation: a new approach to symptomatic uterine myomas. *Am J Obstet Gynecol* 2005;192:768–73.
- [13] Yu L, Moore AB, Dixon D. Receptor tyrosine kinases and their hormonal regulation in uterine leiomyoma. *Semin Reprod Med* 2010;28:250–9.
- [14] Cook H, Ezzali M, Segars JH, et al. The impact of uterine leiomyomas on reproductive outcomes. *Minerva Ginecol* 2010;62:225–36.
- [15] Li R, Guo YL, Hua X, et al. Characterization of focal liver lesions: comparison of pulse-inversion harmonic contrast-enhanced sonography with contrast-enhanced CT. *J Clin Ultrasound* 2007;35:109–17.
- [16] Zhou XD, Ren XL, Zhang J, et al. Therapeutic response assessment of high intensity focused ultrasound therapy for uterine fibroid: utility of contrast-enhanced ultrasonography. *Eur J Radiol* 2007;62:289–94.