

RESEARCH ARTICLE

Open Access



Clinical and radiographic outcomes of a trabecular titanium™ acetabular component in hip arthroplasty: results at minimum 5 years follow-up

Loris Perticarini*, Giacomo Zanon, Stefano Marco Paolo Rossi and Francesco M. Benazzo

Abstract

Background: Aim of this prospective study was to evaluate mid-term clinical and radiographic outcomes in total hip arthroplasty using an acetabular cup made of an innovative biomaterial, Trabecular Titanium™, whose highly porous structure and mechanical properties have been designed to mimic those of the natural bone, thus promoting a more physiological load transfer and a more durable fixation.

Methods: Between September 2007 and November 2009, 134 total hip replacements and eight revisions were carried out using DELTA-TT primary cups (Lima Corporate, Villanova di San Daniele del Friuli, Italy) in 133 consecutive patients. Mean age was 57.5 ± 14.7 SD (18–92) years. Diagnosis was primarily hip osteoarthritis in 85 (63 %) cases, developmental dysplasia of the hip (DDH) in 24 (18 %) and hip avascular necrosis (AVN) in 10 (7 %). All the revision procedures were due to aseptic loosening of the original implant. Approval of the Institutional Review Board of the IRCCS Policlinico San Matteo in Pavia was obtained for this study.

Results: Mean follow-up was 72.7 ± 7.9 SD (60–86) months. Average Harris Hip Score (HHS) significantly increased from 44.2 ± 5.4 SD (35–52) preoperatively to 95.9 ± 3.5 SD (88–100) at the last follow-up. No major post-operative complications were observed. 99.3 % of the acetabular components were radiographically stable at the last follow-up, without any radiolucent lines, sclerotic areas or periprosthetic osteolysis. Kaplan-Meier survival rate was 99.3 % at 5 years (95 % confidence interval).

Conclusions: This first account on the mid-term clinical performance of the DELTA-TT cup shows primary and secondary stability, thus representing an optimal solution for patients with high demands or affected by severe hip conditions.

Background

Total hip arthroplasty (THA) is currently one of the most widely performed procedures in orthopaedic practice, proving remarkably successful in providing pain relief and restoring joint function. THA has been continuously evolving in the past years in terms of prosthetic designs and materials, surgical techniques, treatment and prevention of complications and patient postoperative management. Although major improvements have been recorded with regard to clinical outcomes and survivorship, acetabular

component loosening remains among the most common causes of failure and revision [1–4]. Patient age, poor bone quality and conditions, such as osteonecrosis and dysplasia, have been observed to influence negatively long-term clinical results [5–8].

Prerequisites to achieve durable cementless cup fixation are close contact with viable native bone, primary mechanical stability and secondary bone integration. Press-fit techniques, bone-implant apposition, pore size and material properties play a major role in promoting bone ingrowth and long-term fixation [2–4]. Trabecular Titanium™ is a highly porous cellular solid structure, designed with multi-planar hexagonal interconnected cells to mimic the trabecular morphology of the natural

* Correspondence: loris.perticarini@gmail.com
Clinica Ortopedica e Traumatologica, Università degli Studi di Pavia,
Fondazione IRCCS Policlinico San Matteo, Pavia, Viale Camillo Golgi 19, 27100
Pavia, Italy

bone [9, 10]. The continuity between the porous and solid parts has been specifically developed to overcome the limitations of the traditional porous coatings. In fact, the absence of an interface between the trabecular structure and the bulk material provides greater structural solidity and thus higher resistance to detachment and corrosion [11]. Trabecular Titanium™ has also shown osteoinductive and osteoconductive properties in various in vitro and animal studies, where it has demonstrated to stimulate vascularisation as well as osteoblast proliferation and differentiation [12–15].

Aim of this prospective study was to evaluate mid-term clinical and radiographic outcomes of a Trabecular Titanium™ cup (Fig. 1) in difficult THA cases, such as patients with high demands, subjects affected by severe hip conditions (*i.e.* osteonecrosis, dysplasia) or with extremely poor bone quality.

Methods

Patient population

Between September 2007 and November 2009, 134 hip replacements and eight revisions were carried out using DELTA-TT primary acetabular cups in 133 consecutive patients, 59 (44 %) men, 74 (56 %) women.

The acetabular component was implanted at the right side in 76 cases and at the left side in 66 cases in this prospective case series. Three women underwent a bilateral single-stage procedure, while two women and four men were operated on the other side averagely 11 months after the first surgery. The mean age of patients was 57.5 ± 14.7 SD (18–92) years (Table 1).


The patients were selected from a population requiring total hip arthroplasty (THA) according to the following eligibility criteria: males and females, with a BMI ≤ 40 kg/m², presenting pain, limp and severe functional impairment. The patients needed to be assessed as difficult THA cases

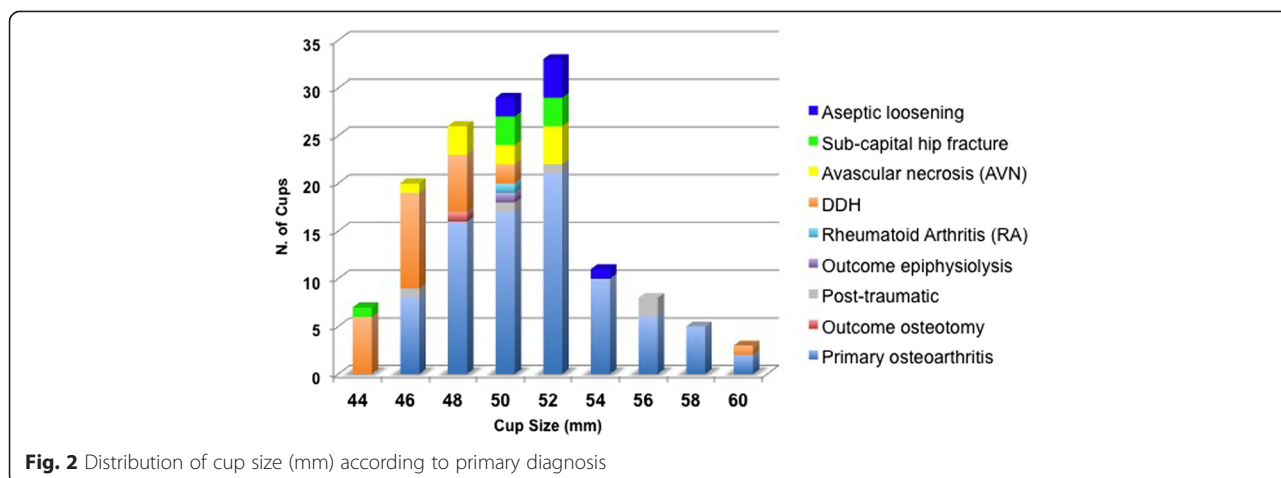
in order to be included in this series, such as subjects affected by severe hip conditions (*i.e.* osteonecrosis, dysplasia), patients with high demands or extremely poor bone quality according to the patient's age and X-ray evaluation, or patients requiring hip revision surgery but presenting limited bone deficiency (*i.e.* Paprosky I or IIA). The following pathologies were regarded as contraindications for inclusion in this investigation: severe and impairing vascular diseases, neurosensory deficits, neuromuscular diseases, tumours, active or suspicious infections, severe kidney failure, Paget's disease. Underlying pathology was hip osteoarthritis (OA) in 85 (63 %) cases, developmental dysplasia of the hip (DDH) in 24 (18 %), hip avascular necrosis (AVN) in 10 (7 %), sub-capital hip fractures in 7 (5 %), post-traumatic arthritis in 5 (4 %) (1 case of lag screw cut-out of femoral nail), sequelae of femoral varus osteotomy in hip dysplasia in 1 (1 %), deformity following epiphysiolysis of the femoral head in 1 hip (1 %), and rheumatoid arthritis in 1 (1 %). All the revision procedures were due to aseptic loosening of the original implant, and the patients presented bone defects classified as Paprosky Type I or IIA.

Approval of the Institutional Review Board of the IRCCS Policlinico San Matteo in Pavia was obtained for this study, and all subjects provided informed consent prior to participation.

Acetabular and femoral components

Uncemented DELTA-TT cups (Lima Corporate, Villanova di San Daniele del Friuli, Italy) were used in all cases (Fig. 1). Their extremely rough surface is specifically designed to enhance the mechanical grip and ensure maximum stability, while promoting an effective bone integration. The shell of this cup is manufactured in titanium alloy (Ti₆Al₄V) via Electron Beam Melting [9, 10]. This one-step production process guarantees structural continuity between the inner





loosening occurred in a Crowe 4 DDH patient 9 months after surgery, due to the high dislodging forces of the lengthened abductor muscles (no femoral shortening was performed). This patient underwent a revision with another DELTA-TT cup, with excellent results at 5-year follow-up (Figs. 4, 5).

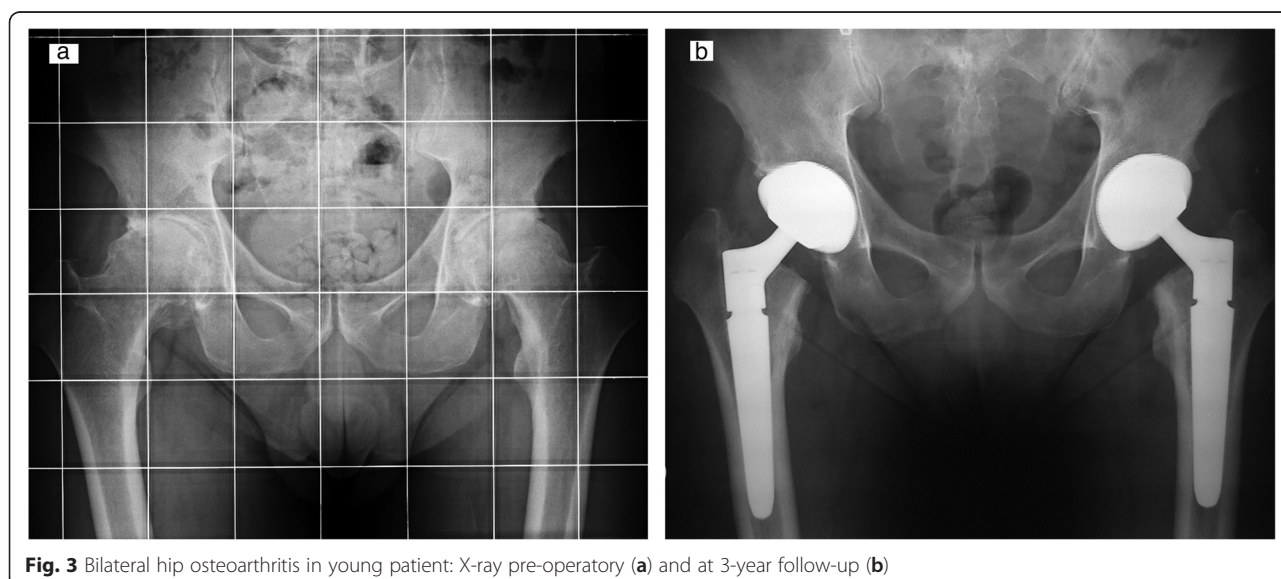
Two patients underwent a stem revision for thigh pain, respectively 11 and 42 months after surgery, with complete resolution of symptoms.

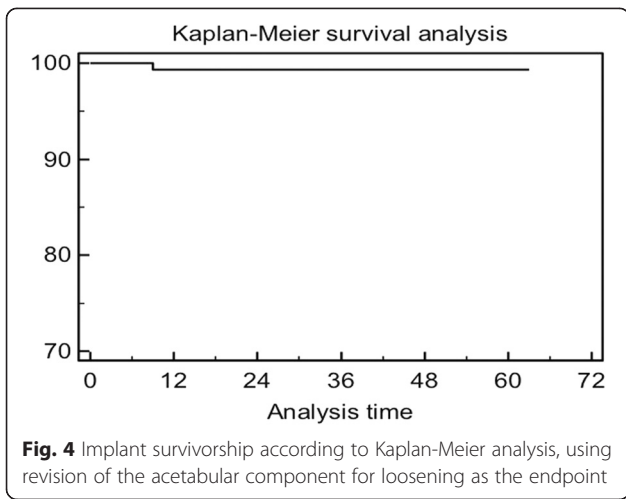
Discussion

Multiples studies report short- to mid-term clinical outcomes with a large variety of cementless acetabular cups [1–4, 19–22]. Early results with Trabecular Metal (TM, Zimmer) cups reported excellent stability and bone apposition, both in primary and revision cases, at a mean follow-up of 28 months; only one patient out of 62 resulted unsatisfied due to persistent thigh pain

[19]. Kamada et al. [20] assessed the long-term clinical and radiographic outcomes of Trabecular Metal cups on 45 cases of hip dysplasia. At a mean follow-up of 9.8 years (range 7–10 years), all cups resulted radiographically stable, with a mean JOA hip score improving from 48 to 92 points. Naziri et al. [21] reported no radiolucencies or cup migration on 252 patients using a highly porous titanium cup at a minimum follow-up of 3 years. Naudie et al. [22] performed a radiostereometric analysis on an acetabular shell with an enhanced porous ingrowth surface, describing minimal cup micromotions at short-term follow-up. Nonetheless, most of the current acetabular coatings and highly porous cup designs have shown to present inherent limitations, such as low volumetric porosity, relatively high modulus of elasticity and low frictional properties [1–4, 19–22].

This study reports a first account on the mid-term clinical performance of the DELTA-TT cup, with a





survivorship of 99.3 % at 5 years. Excellent short- and mid-term radiographic and clinical results were observed, with a significant increase in patients' quality of life and joint functional status, both in primary and revision cases.

No differences were observed in terms of clinical outcomes according to age or different primary diagnoses, such as osteonecrosis and dysplasia. Age distribution in the patient population deliberately encompassed subjects with high demands as well as elderly, in order to be able to observe and capitalize on all the features of this acetabular system, such as its high grip and osseointegration potential.

All cups showed excellent primary stability and good osseointegration, even in patients with poor bone quality. The tight "scratch-fit" of this cup has exhibited a superior initial fixation, while reducing the risk of micromotions. Trabecular Titanium™ is in fact characterized by an extremely high friction coefficient thanks to its macro-porous structure which fosters the mechanical interlocking at the bone-implant interface.

99.3 % of the acetabular components resulted radiographic stable, without radiolucent lines or periprosthetic osteolysis. DELTA-TT cups have been designed to promote a more physiological load transfer, hence minimizing the potential for stress shielding and bone resorption. In virtue of its highly porous hexagonal cell structure, Trabecular Titanium™ displays in fact an elastic modulus (1.1 GPA) [9] largely inferior to the other materials used

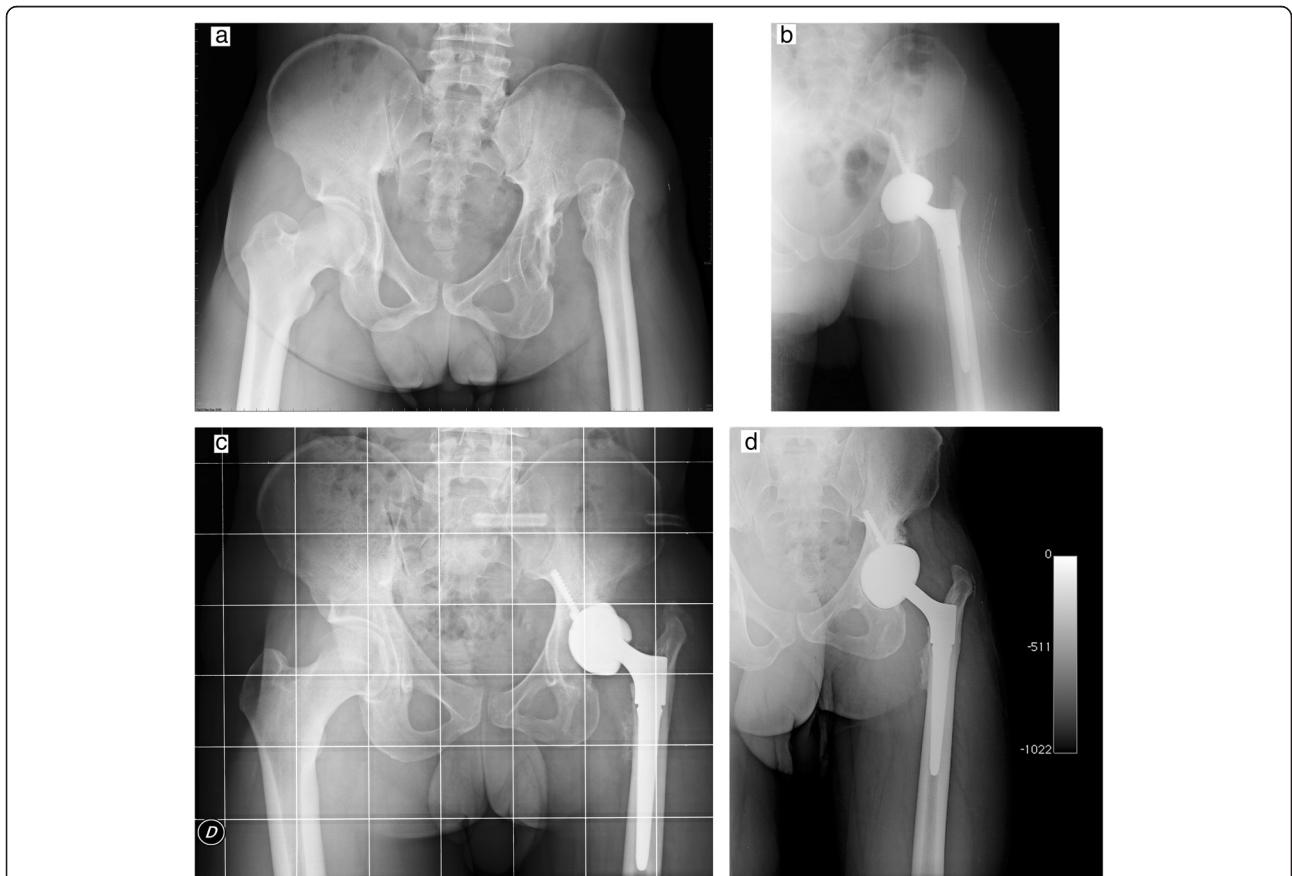


Fig. 5 Case of cup loosening: **a** pre-operative X-ray (DDH Crowe 4), **b** post-operative radiograph, **c** loosening of the cup, **d** X-ray at 4-year follow-up, after revision with primary DELTA-TT cup

in the orthopaedic field, but comparable to the one of the trabecular bone.

Ceramic-on-ceramic bearings and large diameter heads were mostly used during the course of this investigation to increase ROM and minimize wear, in order to reduce the incidence of potential revision at long-term.

Conclusions

In our experience, these clinical results obtained with a patient population characterized by a wide range of age suggest that DELTA-TT cups can provide an optimal prosthetic solution both in high-demand patients, with ceramic-on-ceramic bearings, as well as in elderly patients, with poor bone quality, using preferentially ceramic-on-polyethylene. Further studies are necessary to assess long-term survivorship.

Abbreviations

AVN: avascular necrosis; BMI: body mass index; DDH: developmental dysplasia of the hip; HHS: Harris Hip Score; OA: osteoarthritis; SEM: scanning electron microscopy; TT: Trabecular Titanium.

Competing interests

One of the authors is a consultant of Lima Corporate as a Scientific Advisor. None of the other authors have competing interests.

Authors' contributions

LP participated in the design of the study and performed the collection, analysis and interpretation of data. FB was the Principal Investigator, the senior surgeon and was responsible of the design and conduct of the study; he coordinated the study and helped to draft the manuscript. GZ performed the statistical analysis. SMPR has been involved in drafting the manuscript. All authors read and approved the final manuscript.

Acknowledgements

We thank the foundation Mario Boni for the scientific support given to the paper.

Received: 22 April 2015 Accepted: 19 November 2015

Published online: 03 December 2015

References

1. Australian Orthopaedic Association National Joint Replacement Registry (AOA NJRR). Hip and Knee Arthroplasty Annual Report 2012 [Internet]. [cited 2012 December 27]. Available from: <https://aoanjrr.dmac.adelaide.edu.au/annual-reports-2012>.
2. Russell RD, Estrera KA, Pivec R, Mont MA, Huo MH. What's new in total hip arthroplasty. *J Bone Joint Surg Am*. 2013;95(18):1719–25.
3. Howard JL, Kremers HM, Loechler YA, Schleck CD, Harnsen WS, Berry DJ, et al. Comparative survival of uncemented acetabular components following primary total hip arthroplasty. *J Bone Joint Surg Am*. 2011;93(17):1597–604.
4. Banerjee S, Issa K, Kapadia BH, Pivec R, Khanuja HS, Mont MA. Highly-porous metal option for primary cementless acetabular fixation. What is the evidence? *Hip Int*. Epub 2013 Sep.
5. Duffy GP, Prpa B, Rowland CM, Berry DJ. Primary uncemented Harris-Galante acetabular components in patients 50 years old or younger: results at 10 to 12 years. *Clin Orthop Relat Res*. 2004;427:157–61.
6. Mont MA, Maar DC, Krackow KA, Jacobs MA, Jones LC, Hungerford DS. Total hip replacement without cement for non-inflammatory osteoarthritis in patients who are less than forty-five years old. *J Bone Joint Surg Am*. 1993; 75:740–51.
7. Engesaeter LB, Furnes O, Havelin LI. Developmental dysplasia of the hip - good results of later total hip arthroplasty: 7135 primary total hip arthroplasties after developmental dysplasia of the hip compared with 59774 total hip arthroplasties in idiopathic coxarthrosis followed for 0 to 15 years in the Norwegian Arthroplasty Register. *J Arthroplasty*. 2008;23:235–40.

8. Boyle MJ, Frampton CM, Crawford HA. Early results of total hip arthroplasty in patients with developmental dysplasia of the hip compared with patients with osteoarthritis. *J Arthroplasty*. 2012;27:386–90.
9. Marin E, Fusi S, Pressacco M, Paussa L, Fedrizzi L. Characterization of cellular solids in Ti6Al4V for orthopaedic implant applications: Trabecular Titanium™. *J Mech Behav Biomed Mater*. 2010;3(5):373–81.
10. Marin E, Pressacco M, Fusi S, Lanzutti A, Turchet S, Fedrizzi L. Characterization of grade 2 commercially pure Trabecular Titanium structures. *Mater Sci Eng C Mater Biol Appl*. 2013;33(5):2648–56.
11. Dalla Pria P, Pressacco M, Veronesi E. Nuove frontiere nell'osteointegrazione: il Trabecular Titanium™. *Sphera Med J*. 2008;7:46–50 (in Italian).
12. Asti A, Gastaldi G, Dorati R, Saino E, Conti B, Visai L, Benazzo F. Stem cells grown in osteogenic medium on PLGA, PLGA/HA, and titanium scaffolds for surgical applications. *Bioinorg Chem Appl*. 2010;(2010):831031.
13. Sollazzo V, Massari L, Pezzetti F, Girardi A, Farinella F, Lorusso V, et al. Genetic effects of trabecular titanium on MG-63 cell line: a genetic profiling evaluation. *ISRN Mater Sci*. 2011;392763:1–6.
14. Gastaldi G, Asti A, Scaffino MF, Visai L, Saino E, Cometa AM, et al. Human adipose-derived stem cells (hASCs) proliferate and differentiate in osteoblast-like cells on trabecular titanium scaffolds. *J Biomed Mater Res A*. 2010;94(3):790–9.
15. Devine D, Arens D, Burelli S, Bloch HR, Boure L. In vivo evaluation of the osteointegration of new highly-porous Trabecular Titanium™. *J Bone Joint Surg (Br)*. 2012;94-B(Suppl XXXVII):201.
16. Harris WH. Traumatic Arthritis of the hip after dislocation and acetabular fractures: treatment by mold arthroplasty. An end-result study using a new method of result evaluation. *J Bone Joint Surg Am*. 1969;51:737–55.
17. DeLee JG, Charnley J. Radiological demarcation of cemented sockets in total hip replacement. *Clin Orthop Relat Res*. 1976;121:20–32.
18. Moore MS, McAuley JP, Young AM, Engh Sr CA. Radiographic signs of osseointegration in porous-coated acetabular components. *Clin Orthop Relat Res*. 2006;444:176–83.
19. Simon JP, Bellemans J. Clinical and radiological evaluation of modular trabecular metal acetabular cups. Short-term results in 64 hips. *Acta Orthop Belg*. 2009;75:623–30.
20. Kamada T, Mashima N, Nakashima Y, Imai H, Takeba J, Miura H. Mid-term clinical and radiographic outcomes of porous tantalum modular acetabular components for hip dysplasia. *J Arthroplasty*. 2015;30(4):607–10.
21. Naziri Q, Issa K, Pivec R, Harwin SF, Delanois RE, Mont MA. Excellent results of primary THA using a highly porous titanium cup. *Orthopedics*. 2013;36(4):e390–4.
22. Naudie DD, Somerville L, Korczak A, Yuan X, McCalden RW, Holdsworth D, et al. A randomized trial comparing acetabular component fixation of two porous ingrowth surfaces using RSA. *J Arthroplasty*. 2013;28(8 Suppl):48–52.

Submit your next manuscript to BioMed Central and we will help you at every step:

- We accept pre-submission inquiries
- Our selector tool helps you to find the most relevant journal
- We provide round the clock customer support
- Convenient online submission
- Thorough peer review
- Inclusion in PubMed and all major indexing services
- Maximum visibility for your research

Submit your manuscript at
www.biomedcentral.com/submit

