

Supratentorial Tanycytic Ependymoma in an Adult Male: Case Report and Review of Literature

Giselle Lopez^a Roger E. McLendon^b Katherine B. Peters^c

^aDepartment of Pathology, UCSF Medical Center, San Francisco, Calif., and Departments of ^bPathology and ^cSurgery, Duke University Medical Center, Durham, N.C., USA

Key Words

Tanycytic ependymoma · Supratentorial tanycytic ependymoma · Adult

Abstract

Ependymomas, tumors of the ependymal cells, are very rare and usually present in the pediatric population. Furthermore, there are even rarer variants of ependymomas that can include cellular, papillary, clear cell, and tanycytic subtypes. We present a case of a supratentorial tanycytic ependymoma in an adult male and review the literature in regard to this rare primary central nervous system neoplasm.

© 2015 S. Karger AG, Basel

Introduction

Ependymomas are rare forms of primary brain tumors, accounting for 3–7% of all brain tumors [1, 2]. Ependymomas, composed of neoplastic ependymal cells, are thought to arise from the ependymal cells in the ventricular system. The majority occur infratentorially in the pediatric population, while a smaller fraction occurs in adults, usually in the spinal cord [1]. Rare variants of ependymomas have been described and can include cellular, papillary, clear-cell, and tanycytic variants. Tanycytic ependymomas are particularly rare and typically occur in the spinal cord as an intramedullary mass. First described by Friede and Pollak [3] in 1978, tanycytic ependymoma represents a WHO grade II ependymoma with characterized pathology described as containing bipolar cells with absent mitosis and low-to-moderate cellularity. Here we report a case of a supratentorial intraparenchymal tanycytic ependymoma.

Case Report

The patient is a 58-year-old male with a history of hypertension and type II diabetes mellitus who presented to an outside hospital after developing chin and right arm tremors, followed by a seizure. The seizure was complicated by a fall and urinary incontinence; the seizure resolved on its own. A CT completed at an outside hospital revealed a large, complex cystic mass in the frontal lobe and left hemispheric subarachnoid hemorrhage. The patient was administered levetiracetam and transferred to a specialty hospital for further evaluation. MRI analysis revealed a 5.6 × 8 × 5 cm complex cystic lesion in the left frontoparietal lobe, with a mass effect on the left lateral ventricle (fig. 1). This lesion included several nodular T2 bright and T1 isointense solid components. There was some enhancement in the cystic components that was also visualized on T1 imaging with gadolinium. Surgery was performed, and a left frontoparietal brain lesion, which was initially suspected to be a low-grade glioma, was removed. However, the tumor was surprising in its grayness and more firm than it would be expected for a low-grade glioma. The surgery was repeated 3 days later for microdissection and tissue harvesting. During his hospital stay, the patient developed waxing and waning expressive aphasia, with the development of global aphasia, a right facial droop, and right-sided weakness. A CT demonstrated hemorrhage in the resection cavity, effacement of the left superior frontoparietal sulci suggestive of cerebral edema, and a slight increase in left to right midline shift from 1.3 to 1.5 cm. This required surgery on postoperative day 6 for removal. However, it was unclear if the aphasia stemmed from the clot or cerebral edema following the surgery. On the day following evacuation of the hematoma, the patient's symptoms improved. The patient's symptoms included residual slurred speech, which improved over the subsequent month. At his last visit, 18 months following surgery, he continued to do well with no evidence of clinical or radiographic recurrence.

Pathological analysis revealed brain tissue infiltrated by well-differentiated piloid cells with low-to-moderate cellularity (fig. 2). There was no microvascular proliferation or necrosis identified. Analysis of immunohistochemical staining revealed glial fibrillary acidic protein-positivity solely in reactive astrocytes. The proliferative index of the tumor was low, with only 2% of cells positive for Ki67 staining. Immunohistochemistry was also negative for mutant isocitrate dehydrogenase 1 (IDH1^{R132H}). Immunohistochemistry against epithelial membrane antigen revealed a 'dot-like' positivity. A histological analysis revealed a tanycytic ependymoma (WHO Grade II).

Discussion

This case report shows the diagnosis and current clinical outcome of a male adult patient with a supratentorial tanycytic ependymoma, WHO grade II. This rare variant of ependymoma commonly occurs in the spinal cord. In a review of the literature, we identified only 6 cases of ectopic supratentorial tanycytic ependymomas (table 1) [4–9]. All patients were male, and their ages ranged from 2 to 59 years. Four cases were identified after the onset of seizures, one after the onset of headaches, and one was incidental. Locations varied among the cases, including both cortical and subcortical locations as well as right and left hemispheres. Tumors were frontal, temporoparietal, temporo-occipital, parietal, and parieto-occipital. In this series of patients, surgery was the primary treatment modality with no utilization of further radiotherapy or chemotherapy. The wide age ranges of the patients and the presence of the tumors throughout the hemispheres underscore the importance of considering ependymomas in the diagnosis of tumors occurring throughout the brain. This is espe-

cially crucial with regards to tanycytic ependymomas, which can be easily mistaken for pilocytic astrocytomas or fibroblastic meningiomas. This can occur due to the bipolar nature of the tumor cells on pathology along with low-to-moderate cellularity. Nonetheless, a number of nonconventional ependymoma variants can also mimic other tumors within the brain. Clear-cell ependymomas may appear histologically similar to oligodendrogliomas [10]. Papillary ependymomas may demonstrate features similar to those of choroid plexus tumors, while myxopapillary ependymomas may mimic chordomas [10]. In undiagnosed tumors that lack the typical staining pattern for more common intraparenchymal tumors, alternative diagnoses, including variants of ependymoma, must be considered.

In conclusion, this case report represents the rare presentation of a tanycytic ependymoma in the supratentorial region in an adult male patient. Proper pathological diagnosis of the rare variant of ependymoma is warranted as it can impact prognosis and treatment.

Disclosure Statement

The authors have no competing interests to disclose.

References

- 1 Gilbert MR, Ruda R, Soffietti R: Ependymomas in adults. *Curr Neurol Neurosci Rep* 2010;10:240–247.
- 2 Ng HK: Ependymoma, subependymoma and myxopapillary ependymoma (chapter 14); in McLendon R, Rosenblum MK, Bigner DD (eds): *Russell and Rubinstein's Pathology of Tumors of the Nervous System*. London, CRC Press, 2006, pp 201–221.
- 3 Friede RL, Pollak A: The cytogenetic basis for classifying ependymomas. *J Neuropathol Exp Neurol* 1978;37:103–118.
- 4 Ito T, Ozaki Y, Nakamura H, Tanaka S, Nagashima K: A case of tanycytic ependymoma arising from the cerebral hemisphere. *Brain Tumor Pathol* 2006;23:91–95.
- 5 Kambe A, Kurosaki M, Watanabe T, Nakazato Y: Pediatric supratentorial cortical tanycytic ependymoma associated with absence seizures. *Clin Neuropathol* 2014;33:308–310.
- 6 Langford LA, Barre GM: Tanycytic ependymoma. *Ultrastruct Pathol* 1997;21:135–142.
- 7 Reis F, Schwingel R, de Morais FC, de Souza Queiroz L: Supratentorial tanycytic ependymoma: an uncommon fibrillary ependymoma variant. *Arq Neuropsiquiatr* 2011;69:723.
- 8 Richards AL, Rosenfeld JV, Gonzales MF, Ashley D, Mc Lean C: Supratentorial tanycytic ependymoma. *J Clin Neurosci* 2004;11:928–930.
- 9 Rigante L, Novello M, Massimi L, Caldarelli M: A cortical cystic epileptogenic lesion: tanycytic ependymoma. *Acta Neurol Belg* 2013;113:523–525.
- 10 Louis DN, Ohgaki H, Wiestler OD, Cavenee WK, Burger PC, Jouvet A, Scheithauer BW, Kleihues P: The 2007 WHO classification of tumours of the central nervous system. *Acta Neuropathol* 2007;114:97–109.

Table 1. Cases of supratentorial tanycytic ependymomas

Reference	Sex	Age, years	Location	Clinical presentation	Treatment
Lopez et al. [current case]	Male	58	Left frontoparietal lobe	Seizures	Surgical resection
Reis et al. [7]	Male	6	Right subcortical parieto-occipital lobe	Focal seizures and headache	Not presented
Ito et al. [4]	Male	59	Right temporo-occipital paratrigonal	Incidental	Surgical resection
Richards et al. [8]	Male	16	Left frontal lobe	Seizures	Surgical resection
Rigante et al. [9]	Male	14	Right temporoparietal lobe	Seizures	Surgical resection
Kambe et al. [5]	Male	2	Right superior parietal lobe	Absence seizures	Surgical resection
Langford et al. [6]	Male	13	Left parietal lobe	Headaches	Not presented

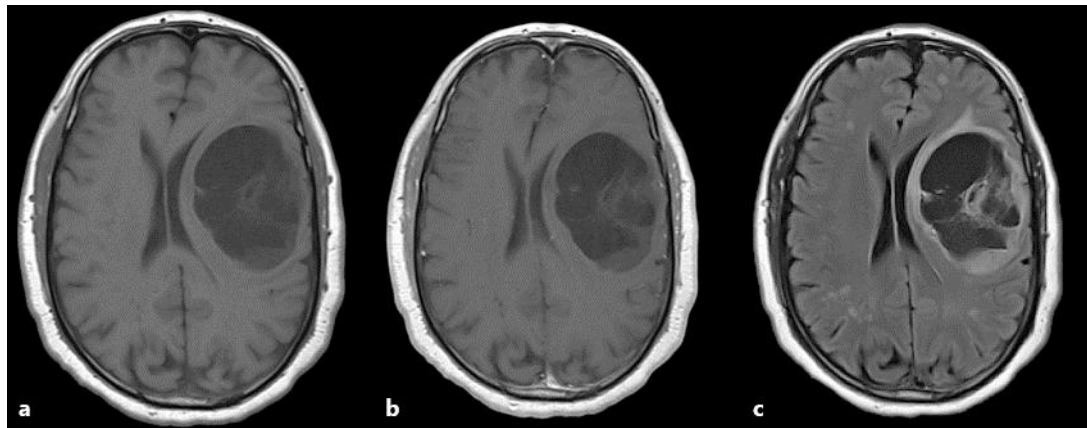


Fig. 1. Brain MRI with and without gadolinium images at diagnosis. **a** T1 without contrast, **b** T1 with contrast, **c** FLAIR.

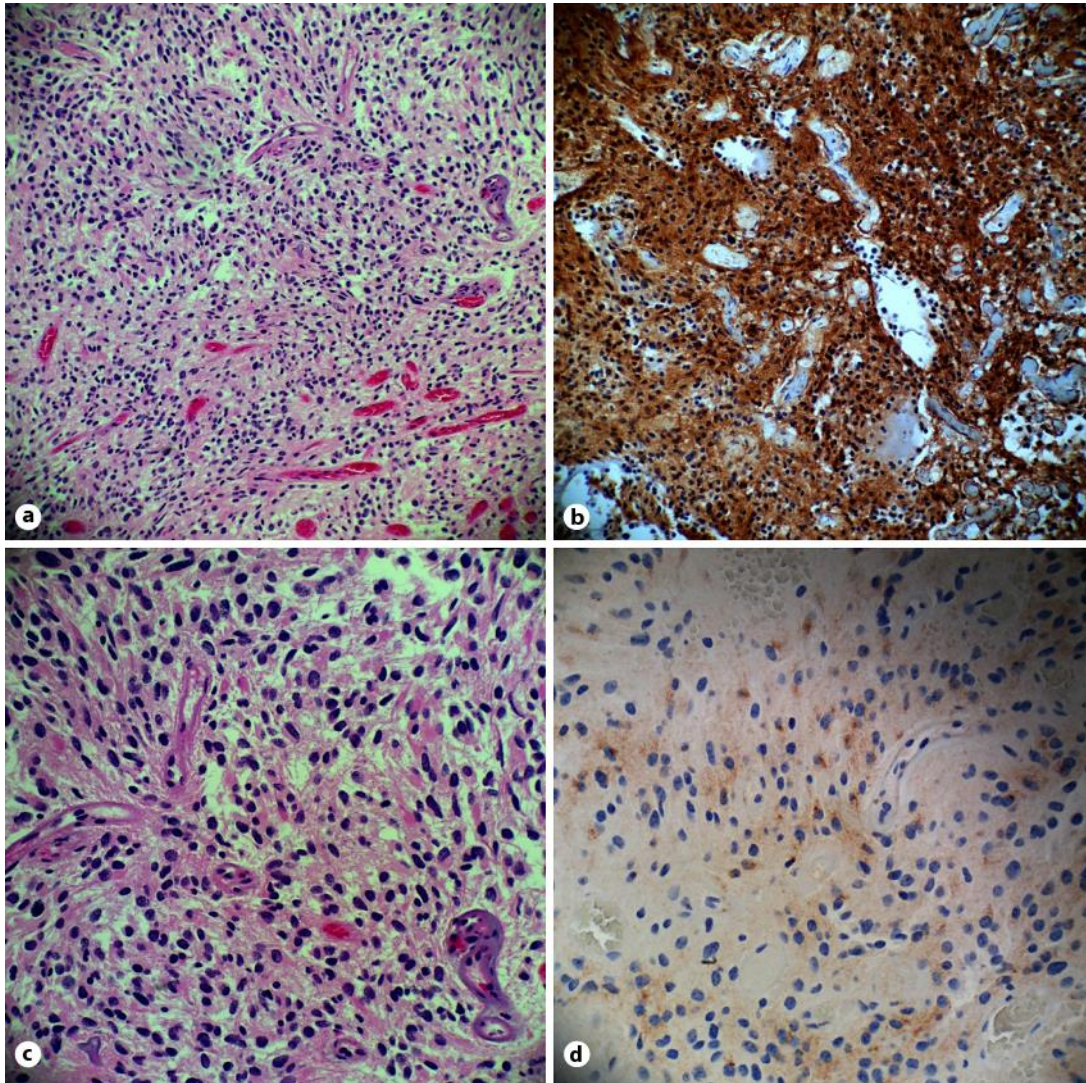


Fig. 2. Pathology images staining patterns. **a** HE. $\times 20$. **b** Glial fibrillary acidic protein. $\times 20$. **c** HE. $\times 40$. **d** Epithelial membrane antigen. $\times 40$.