

## Post-Surgical Unilateral Left Pulmonary Edema after Mitral Valve Replacement – A Diagnostic Challenge

### Abstract

Unilateral left pulmonary edema due to inadvertent surgical occlusion of left superior and inferior pulmonary veins is not only an exceedingly rare complication of mitral valve surgeries but also a diagnostic challenge in the postoperative recovery unit. Described here is a case of a 38-year-old male who developed progressively worsening unilateral left pulmonary edema after mitral valve replacement on postoperative day-1. The diagnosis was mostly by the exclusion of multiple possible differentials and was confirmed during reexploration surgery.

**Keywords:** *Mitral stenosis, mitral valve replacement, pulmonary vein occlusion, unilateral left pulmonary edema*

**Saipriya Tharimena,  
A V R Naidu**

*Department of Cardiac  
Anaesthesia, Apollo Hospitals,  
Secunderabad, Hyderabad,  
Telangana, India*

### Introduction

Postoperative unilateral left pulmonary edema (UPE) is an exceedingly rare complication of mitral valve surgery, which finds only a rare mention in literature.<sup>[7]</sup> Of the cases reported of UPE, most involved the right lung. We here report a case of unilateral left pulmonary edema after mitral valve replacement due to inadvertent stitches involving left pulmonary veins, thereby causing occlusion, thrombus formation at the site, and unilateral left pulmonary edema due to grossly elevated pulmonary venous pressure gradients.

### Case

A 38-year-old male presented with dyspnea of New York Heart Association (NYHA) grade-III, for 2 months, which had progressively worsened to grade-IV, associated with palpitations. No history of (H/o) chest pain or syncope, or diaphoresis. He is a known case of chronic rheumatic heart disease with mitral stenosis (MS) initially diagnosed in 1996 for which balloon mitral valvotomy (BMV) was done. Inj. Penidure was started and continued until he had a relapse of symptoms in 2008, was rediagnosed with severe MS, and BMV was performed for a second time. The patient was initiated on treatment with anticoagulants, which he

discontinued after 2 years. The patient was apparently asymptomatic until relapse of symptoms 2 months ago.

During the current admission 2D echocardiography was done, which showed severe calcified MS with mitral valve area (MVA) of 0.7 cm<sup>2</sup>, the gradient of 41/22 (peak/mean) with moderate mitral regurgitation (MR), severe tricuspid regurgitation (TR), and severe pulmonary hypertension (PAH) (right ventricle systolic pressure 93 mmHg) with fair left ventricular (LV) function.

The patient was taken up for mitral valve replacement and tricuspid valve (TV) repair. Two peripheral intravenous lines were secured, premedication was given with midazolam 2 mg intravenous (IV) and fentanyl 2 mcg/kg IV. The right radial artery and right femoral artery were cannulated for pressure monitoring. The patient was induced with propofol 1 mg/kg IV, neuromuscular block was achieved with rocuronium, and the airway was secured with an 8.5 mm cuffed endotracheal tube. The right internal jugular vein was cannulated with a triple lumen central venous catheter. Hemodynamic parameters monitoring was done as a routine for any cardiac surgical operation. After sternotomy full heparinization was done with unfractionated heparin 3 mg/kg IV to achieve a target activated clotting time (ACT) of >480 s. After aortic cannulation, bicaval cannulation

**Submitted:** 21-Nov-2019

**Revised:** 03-Apr-2020

**Accepted:** 26-Apr-2020

**Published:** 19-Oct-2020

### Address for correspondence:

*Dr. Saipriya Tharimena,  
Department of Cardiac  
Anaesthesia, Apollo Hospitals,  
Near Keyes Girls High  
School, Regimental Bazar,  
Secunderabad - 500 003,  
Hyderabad, Telangana, India.  
E-mail: dr.saipriya@gmail.com*

### Access this article online

**Website:** www.annals.in

**DOI:** 10.4103/aca.ACA\_180\_19

### Quick Response Code:



**How to cite this article:** Tharimena S, Naidu AV. Post-Surgical unilateral left pulmonary edema after mitral valve replacement – A diagnostic challenge. *Ann Card Anaesth* 2020;23:508-11.

This is an open access journal, and articles are distributed under the terms of the Creative Commons Attribution-NonCommercial-ShareAlike 4.0 License, which allows others to remix, tweak, and build upon the work non-commercially, as long as appropriate credit is given and the new creations are licensed under the identical terms.

**For reprints contact:** reprints@medknow.com

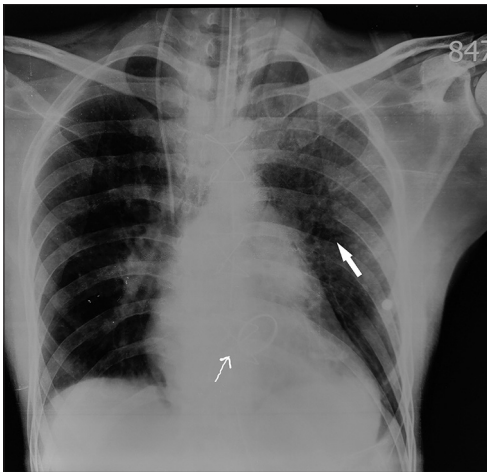


Figure 1: Alveolar Infiltrates seen in the Left lung on POD-1 after MVR Below arrow - Prosthetic Mitral mechanical valve

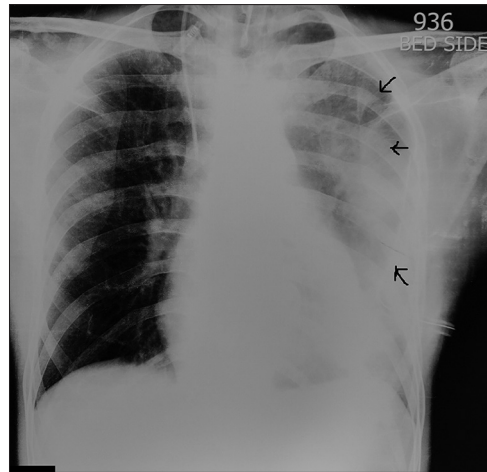


Figure 2: Progressively worsening pulmonary infiltrates involving the entire Left lung on POD-4 after MVR (infiltrates are indicated with arrows)

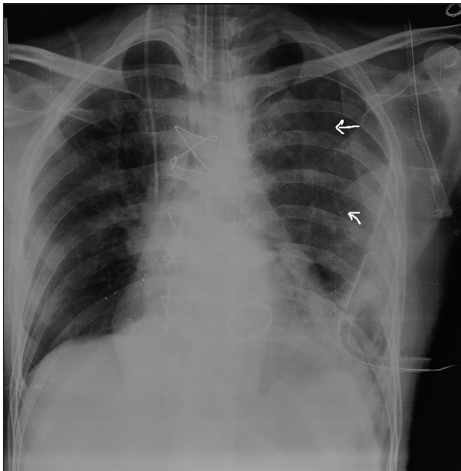


Figure 3: Arrows indicate the resolving pulmonary edema after re-exploration surgery followed by post operative elective Mechanical ventilation with alveolar recruitment

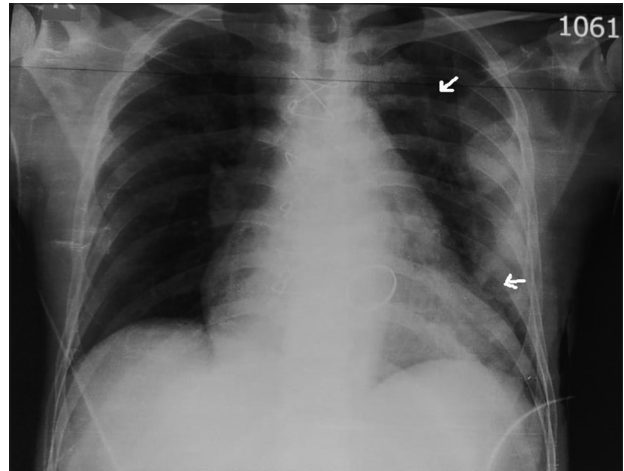


Figure 4: X-ray done on 3<sup>rd</sup> post operative day after redo surgery - Clear Left Lung fields indicating resolved Pulmonary Edema.

was done. Cardiopulmonary bypass was initiated with hyperkalemic cardioplegia to achieve cardiac stand still. Mitral valve replacement was done with 31 mm St. Jude mechanical valve and tricuspid valve (TV) repair was done with 32 mm CE-classic annuloplasty ring. The patient was successfully weaned off the cardio-pulmonary bypass. The effect of heparin was reversed with protamine, hemostasis secured, drains placed, and chest closed in layers. The patient was shifted to recovery with stable hemodynamics, was weaned off ventilator support and extubated after 10 h.

The patient started complaining of dyspnea and cough with frothy sputum 4 h after extubation on the postoperative day (POD)-1, chest X-ray showed alveolar-interstitial infiltrates in the left lung [Figure 1], arterial blood gas (ABG) showed mild respiratory alkalosis, there was no significant decrease in Hb. Oxygen support was given, and IV steroid and bronchodilators were started. Serial chest radiograph (CXR) done on subsequent postoperative days showed worsening of the unilateral left pulmonary edema

[Figure 2]. Clinically patient's condition deteriorated with worsening dyspnea, coarse crepts in all areas of the left lung, atrial fibrillation (AF) with fast ventricular rate, persistent hypotension despite of high inotrope support with dobutamine (15 mcg/kg/min), ABG showing primary respiratory alkalosis with uncompensated metabolic acidosis and hypokalemia, and liver function tests (LFT) showing elevated serum bilirubin (1.6–6.4) and elevated liver enzymes (>12 times normal). Electrocardiogram (ECG) did not show any changes indicative of myocardial infarction. 2D echo was done, which showed a well-functioning prosthetic valve *in situ*, no paravalvular leak, no mitral regurgitation (MR), no pericardial collection or tamponade, and fair left ventricular (LV) function. CXR and ultrasound chest did not show any aneurysm, dissection of the aorta, or pleural effusion. The patient did not have fever, and total differential leukocyte counts were not significantly abnormal (<11,000 cells/cumm) or indicative of pneumonia. A working diagnosis of inadvertent pulmonary vein occlusion or pulmonary vein thrombus was arrived at

after ruling out other differential diagnoses. The decision was made to reexplore the chest for a definitive cause of the condition.

The patient was taken up for reexploration on the 4<sup>th</sup> postoperative day. Bronchial endoscopy showed clear airways with no evidence of (e/o.) clots, crusts, secretions, and obstructions. A median sternotomy was done through old incision after full systemic heparinization, aortic and bicaval cannulation was done, cooled to 32°C, aortic cross-clamp applied, antegrade cold blood cardioplegia given and heart arrested. Reexploration revealed stitches through the left superior and inferior pulmonary veins at their point of entry into the left atrium. Stitches were removed, and an additional drain placed in the left pleura. The patient was rewarmed, heart de-aired, cross-clamp removed, gradually weaned off bypass, serial decannulation was done, hemostasis secured, and chest closed. Patient shifted to recovery on ventilatory and inotrope support with noradrenaline (0.12 mcg/kg/min) and milrinone (0.04 mcg/kg/min).

Postoperatively patient was with stable hemodynamics, electively ventilated for 6 h with intermittent alveolar recruitment maneuvers, adequate bronchial lavage done, inotropes titrated according to condition, and patient was extubated on the same evening after fulfilling criteria and successful trial for extubation. The patient did not have dyspnea. Hemodynamics improved, inotropes were weaned off, CXR [Figures 3 and 4] showed resolving pulmonary edema. The patient was rehabilitated and successfully discharged from the ward after 1 week.

## Discussion

Postcardiac surgery unilateral pulmonary edema is a rare clinical entity requiring a high degree of suspicion to identify at a relatively early stage to reduce morbidity associated with it. The most common cardiogenic cause reported is a severe MR usually acute in origin secondary to acute myocardial infarction with a predilection for right upper lung lobes.<sup>[1,2]</sup> The causes of UPE can be categorized as primarily cardiogenic, which includes more commonly pulmonary vein thrombus, occlusion, unilateral hypoplastic pulmonary artery, congenital or surgical right-to-left shunt (e.g., Blalock–Taussig shunt), intraoperative or postoperative left lateral positioning for prolonged periods, congestive heart failure, ventricular septal rupture post acute myocardial infarction, fluid overload or primarily pulmogenic, which includes unilateral pulmonary embolism, emphysema/bullae, reexpansion pulmonary edema after thoracocentesis for massive pneumothorax or pleural effusion, Swyer-James syndrome, and pneumonia, among others.<sup>[3-5]</sup> It is also seen in the normal lung in patients with unilateral pulmonary disease, such as MacLeod syndrome and unilateral pulmonary artery hypoplasia or agenesis, pulmonary artery compression from aortic dissection or left ventricular pseudo-aneurysm, and pulmonary venous obstruction from mediastinal fibrosis.<sup>[6]</sup>

The diagnostic difficulty with postsurgical UPE is not just due to its relative rarity or similarity in presentation to a number of other cardiogenic and non-cardiogenic conditions, but also due to the need for specific investigations for an accurate diagnosis, such as computed tomography or magnetic resonance (MR) angiography, ventilation-perfusion mismatch studies, transesophageal echocardiography, cardiac catheterization, which may not be feasible to perform due to various socio-economic reasons or ready availability thus making it a diagnosis of exclusion, which may be the one among the many reasons why patients with UPE are at an increased risk of mortality than bilateral pulmonary edema.

A unilateral radiographic infiltrate pattern is more commonly attributed to pneumonia even in the absence of fever and leucocytosis, especially in the postoperative patient as they are already initiated on antibiotic regimens, or as in this patient, it was suspected to be a mucus plug or spasm causing bronchial obstruction, which was ruled out by the absence of airway spasm on auscultation, patent airways on endoscopy, no symptomatic relief with nebulizations and bronchodilators. ECG did not show ST-segment elevation myocardial infarction (STEMI)/non-STEMI (NSTEMI) changes, 2D echo revealed a normally functioning prosthetic mitral valve *in situ* without mitral regurgitation (MR), no aortic dissection, ultrasound chest did not show consolidation of left lung or pleural collection, no aortic dissection, or aneurysm or hypoplastic pulmonary arteries.

This case was diagnosed as unilateral left sided pulmonary edema due to inadvertent pulmonary venous occlusion either due to stitch or thrombus based on clinical and radiological evidences and also negative findings on echocardiography and ultrasonography. The cause was further confirmed during reexploration surgery. In this case, stitches were inadvertently placed into both the left superior and inferior pulmonary veins thus occluding them completely, which caused elevated hydrostatic pressures in the left pulmonary veins, and consequently in the interstitial capillaries, which led to the development of pulmonary edema in the left lung. The right pulmonary veins were not affected, and thus the right lung remained unaffected. After the stitches were removed and the lung was ventilated with alveolar recruitment patient's oxygenation improved, and the infiltrates cleared in the subsequent radiographs.

## Conclusion

Postcardiac surgery unilateral pulmonary edema, though rare, is a possibility that must be considered early in the course of postoperative care, and evaluated aggressively for cardiogenic and pulmonary causes, for the morbidity and mortality associated with it can be greatly reduced with timely diagnosis and treatment.

### Declaration of patient consent

The authors certify that they have obtained all appropriate patient consent forms. In the form, the patient has given consent for the use of images and clinical information to be reported in the journal. The patient understands that the name and initials will not be published and due efforts will be made to conceal the identity, but anonymity cannot be guaranteed.

### Financial support and sponsorship

Nil.

### Conflicts of interest

There are no conflicts of interest.

### References

1. Attias D, Mansencal N, Auvert B, Vieillard-Baron A, Delos A, Lacombe P, *et al.* Prevalence, characteristics, and outcomes of patients presenting with cardiogenic unilateral pulmonary edema. *Circulation* 2010;122:1109-115.
2. Agarwal R, Aggarwal AN, Gupta D. Other causes of unilateral pulmonary edema. *Am J Emerg Med* 2007;25:129-31.
3. Akiyama K, Suetsugu F, Hidai T, Shimamoto K, Takahashi S. Left-sided unilateral pulmonary edema in postinfarction ventricular septal rupture. *Chest* 1994;105:1264-5.
4. Shin JH, Kim SH, Park J, Lim YH, Park HC, Choi SI, *et al.* Unilateral pulmonary edema: A rare initial presentation of cardiogenic shock due to acute myocardial infarction. *J Korean Med Sci* 2012;27:211-4.
5. Handagala R, Ralapanawa U, Jayalath T. Unilateral pulmonary edema: A case report and review of the literature. *J Med Case Rep* 2018;12:219.
6. Nehra D, Liberman M, Vagefi P. Complete pulmonary venous occlusion after radiofrequency ablation for atrial fibrillation. *Ann Thorac Surg* 2009;87:292-5.
7. Apostolakis E, LeivaditisVN, Kallikourdis A, Dedeilias P. Repair of injured right inferior pulmonary vein during mitral valve replacement. *J Cardiothorac Surg* 2009;4:64.