

# Impact of a standardized reporting format on the quality of MRI reports for rectal cancer staging

Neeti A Gupta, Shivani Mahajan, A Sumankumar, Avnish Saklani<sup>1</sup>, Reena Engineer<sup>2</sup>, Akshay D Baheti

Departments of Radio Diagnosis, <sup>1</sup>Colo-rectal Surgery and <sup>2</sup>Radiation Oncology, Tata Memorial Hospital, Mumbai, Maharashtra, India

**Correspondence:** Dr. Akshay D Baheti, Department of Radio Diagnosis, Tata Memorial Hospital, Parel, Mumbai, Maharashtra, India.  
E-mail: akshaybaheti@gmail.com

## Abstract

**Background and Aims:** Besides providing a surgical roadmap, rectal MRI plays a major role in treatment planning. We recently started using a structured template for reporting rectal cancer via MRI. We study the impact of using this template at our hospital in terms of number of essential imaging parameters described in the reports as compared to the pre-template free-text reports. **Methods:** A structured rectal MRI reporting template was created in consensus with members of the colorectal tumour board and was introduced in the department, which included 14 essential parameters to be mentioned in the reports. We conducted a retrospective analysis of rectal MRI reports of 100 cases with histologically proven rectal cancer, comprising 50 consecutive free-text reports before the template was introduced and 50 consecutive structured reports after its introduction, checking for the presence or absence of inclusion of the 14 parameters. An anonymous online feedback survey was conducted as well after the introduction of the template for the members of the colorectal tumour board. **Results:** Overall, the total number of parameters reported increased from a median value of 10 (range 6-13) to 14 (range 12-14). The common unreported parameters prior to template introduction included T staging, presence or absence of restricted diffusion, anterior peritoneal reflection (APR) involvement, and presence or absence of extramural vascular invasion; these were reported in 16%, 22%, 30% and 50% respectively. These improved to 98-100% reporting after template introduction. Maximum improvement was in T staging (16% to 98%) ( $P < 0.0001$ ), restricted diffusion on DWI (from 22% to 100%) ( $P < 0.0001$ ) and APR involvement (from 30% to 100%) ( $P < 0.0001$ ). The most common unreported parameter after template introduction was the "tumoral T2 signal intensity" (unreported in 4% cases). The results of the survey were as follows: 100% felt a decreased need to talk to the radiologist to clarify the report, 81.8% felt an improvement in the quality of reporting as compared to free style reports, and 91% felt that the new template is easier to interpret. **Conclusion:** The introduction of a structured template for rectal cancer significantly improved the quality of rectal MRI reports, along with the satisfaction of referring providers.

**Key words:** Cancer; rectal; reporting; structured; template

## Introduction

The role of MRI is well established in the assessment and local staging of rectal cancer, selection of the appropriate

treatment strategy, and patient prognostication.<sup>[1]</sup> MRI features such as involvement of the circumferential resection

This is an open access journal, and articles are distributed under the terms of the Creative Commons Attribution-NonCommercial-ShareAlike 4.0 License, which allows others to remix, tweak, and build upon the work non-commercially, as long as appropriate credit is given and the new creations are licensed under the identical terms.

**For reprints contact:** reprints@medknow.com

**Cite this article as:** Gupta NA, Mahajan S, Sumankumar A, Saklani A, Engineer R, Baheti AD. Impact of a standardized reporting format on the quality of MRI reports for rectal cancer staging. Indian J Radiol Imaging 2020;30:7-12.

**Received:** 15-Jul-2019  
**Accepted:** 09-Jan-2020

**Revised:** 26-Sep-2019  
**Published:** 30-Mar-2020

### Access this article online

#### Quick Response Code:



**Website:**  
www.ijri.org

**DOI:**  
10.4103/ijri.IJRI\_308\_19

margin (CRM), T staging, and nodal status help decide whether the patient requires pre-operative neo adjuvant chemo radiation or upfront surgery.<sup>[1-3]</sup> Presence or absence of sphincter complex involvement, intersphincteric space involvement and extramural venous invasion (EMVI), amongst other findings, helps in deciding the appropriate surgery and in prognosticating the patient.<sup>[1,3]</sup>

Given the important role that the radiologist has to play in rectal cancer management, it is essential for an MRI report to contain all the relevant details, which will help in guiding appropriate patient management. The use of structured reporting in radiology has been reported to ensure that clinically important findings are more often integrated in the report.<sup>[2]</sup> Structured reporting is especially useful in certain examinations where detailed and specific information is needed to be mentioned in the MRI report in order to make treatment decisions.<sup>[4]</sup> Rectal cancer MRI is one such examination which is reported to benefit from such reporting.<sup>[2]</sup>

Many societies, including the Society of Abdominal Radiology rectal cancer disease-focused panel,<sup>[4]</sup> the European Society of Gastrointestinal and Abdominal Radiology<sup>[5]</sup> and the Korean Society of Abdominal Radiology<sup>[6]</sup> have provided recommendations and templates to be used for reporting baseline and post-treatment rectal MRIs. These recommendations have been made in order to ensure strict quality control in the MRI reports being generated. The proposed templates consist of a list of essential imaging features to be mentioned in every report with the objective of ensuring a practically easy to implement list which is simple and straightforward for the clinicians and surgeons to understand.

We created and implemented a similar structured template for use in rectal cancer reporting in our department in 2017. We studied the impact of using this template at our hospital for the evaluation of rectal cancer in terms of number of essential imaging parameters described in the reports as compared to the pre-template free-text reports.

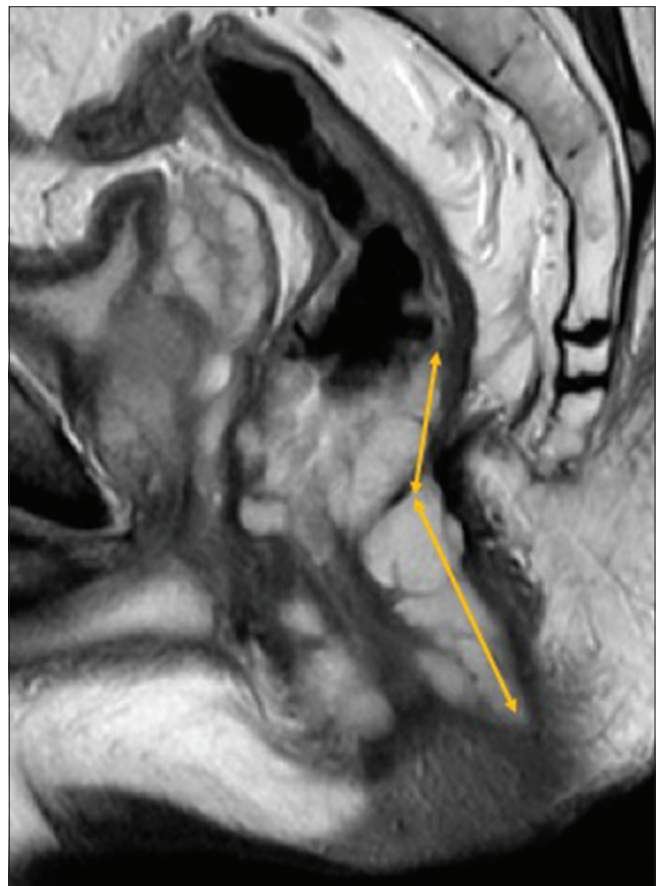## Methods

Being a tertiary care cancer center, all radiologists in our department work in conjunction with various multidisciplinary tumor boards or disease management groups. A structured rectal MRI reporting template was introduced in the department in August 2017 for standardization of rectal MRI reporting. The template was created in consensus with members of the colorectal tumor board, which consists of colorectal surgeons, dedicated gastrointestinal (GI) radiation and medical oncologists, along with subspecialty radiologists and pathologists.

A dedicated talk was conducted for the radiology residents and faculty, following which the template was adopted

across the board. The template included 14 essential parameters like T2 signal intensity of the tumor, presence of restricted diffusion, extramural vascular invasion etc., to be mentioned in rectal MRI reports [Table 1 and Figures 1-6]. All baseline as well as post-treatment rectal MRIs were reported using the template by 'general' (non-GI) onco-radiologists as well as dedicated GI sub-specialty radiologists.

We conducted a retrospective analysis of rectal MRI reports of 100 cases with histologically proven rectal cancer, comprising of 50 consecutive free-text reports before the template was introduced and 50 consecutive structured reports after its introduction. The MRI reports were obtained from the electronic medical record system. Of these, 13 out of 100 patients had both free text and template reports, serving as their own controls. Each report was checked for the presence or absence of inclusion of the 14 essential pre-defined imaging parameters. The actual imaging was not reviewed for the accuracy of findings reported. One year after the introduction of the structured template, an anonymous online feedback survey was conducted for the members of the colorectal tumour board, including senior faculty and fellows on this issue as well. The data was analyzed using the Fischer's Exact Test to evaluate whether there was a significant difference in the

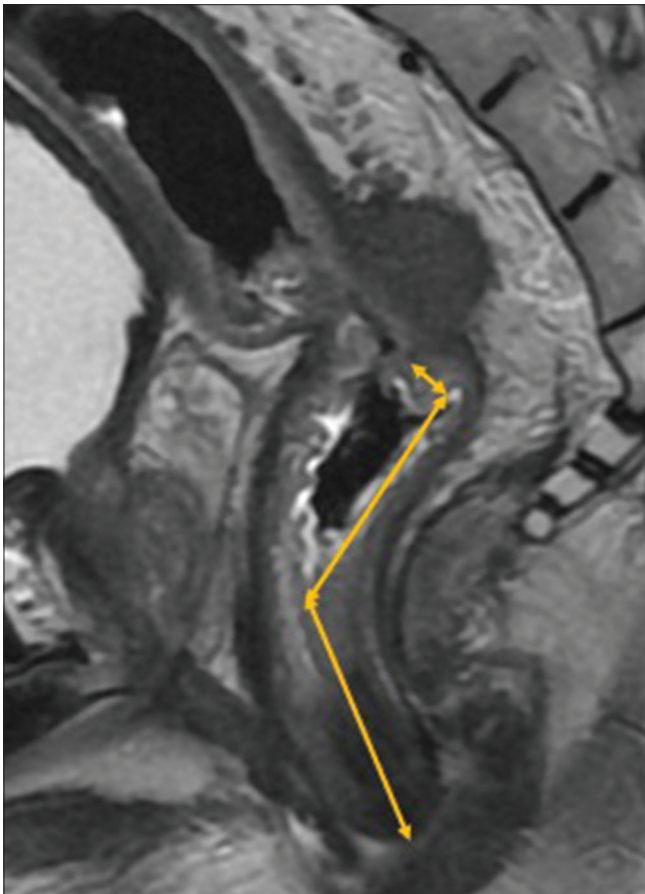

**Figure 1:** Measurement of length of tumor involving the anal canal and lower rectum on sagittal T2-weighted image

**Table 1: MRI parameters covered in the reports before and after implementation of the structured template**

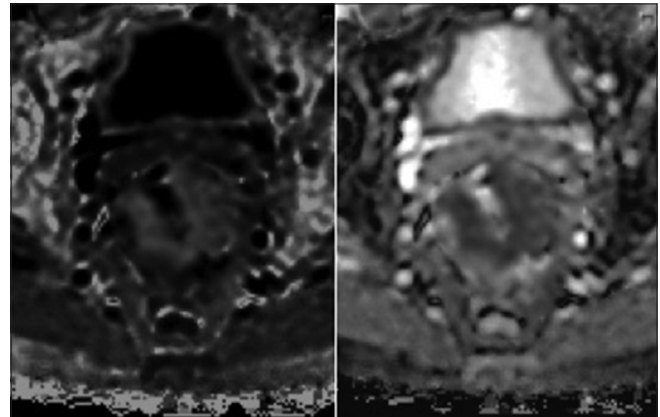
Essential reporting parameters	Reported in percentage of cases (%)		P
	Free text reports	Template reports	
Location of tumor	100	94	
Length of tumor	86	100	0.4
Distance from anal verge	92	100	0.6
Tumoral T2 signal intensity	68	92	0.1
Restricted diffusion	22	100	<0.0001
Depth of extra-serosal extension/Distance from mesorectal fascia	48	98	0.002
Circumferential resection margin status	90	100	0.6
Anterior peritoneal reflection involvement	30	100	<0.0001
Organ involvement	86	100	0.4
Anal sphincter involvement	84	98	0.4
T stage	16	98	<0.0001
Extra mural vascular invasion	50	100	0.003
Mesorectal nodes	96	100	0.8
Extra mesorectal nodes	96	98	0.9
Median parameters reported	10 out of 14	14 out of 14	
Range	6 to 13	12 to 14	
IQR	8-11	14-14	

Median, range and IQR of number of essential imaging parameters reported in free text and template reports



**Figure 2:** Measurement of distance of upper rectal tumor from anal verge on sagittal T2-weighted image

percentage of optimal quality reports before and after implementation of the standardized reporting format, using

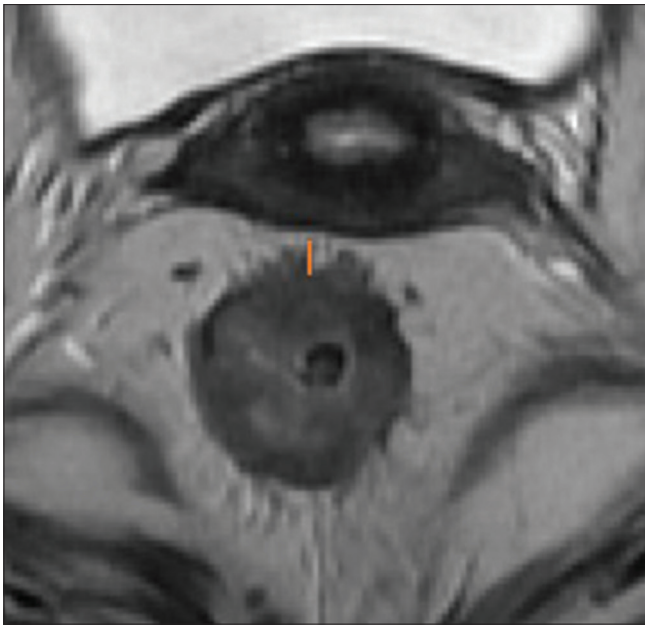


**Figure 3:** Circumferential rectal wall thickening showing diffusion restriction on diffusion weighted imaging

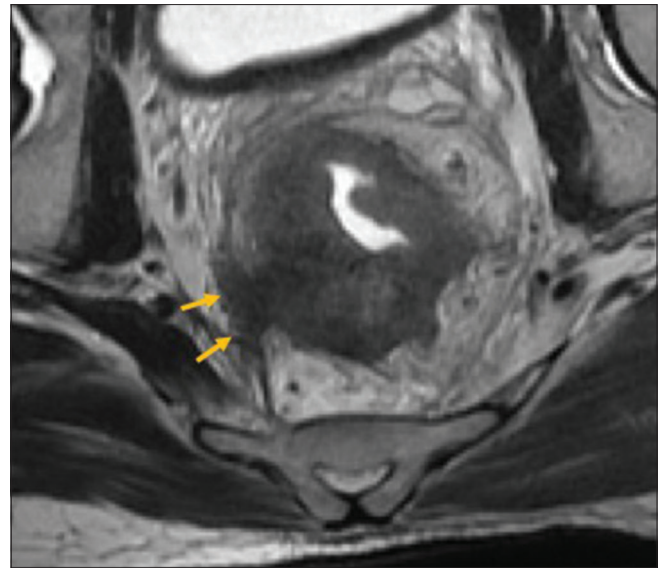
GraphPad QuickCalcs online software. A *P* value of <0.05 was considered to be significant.

## Results

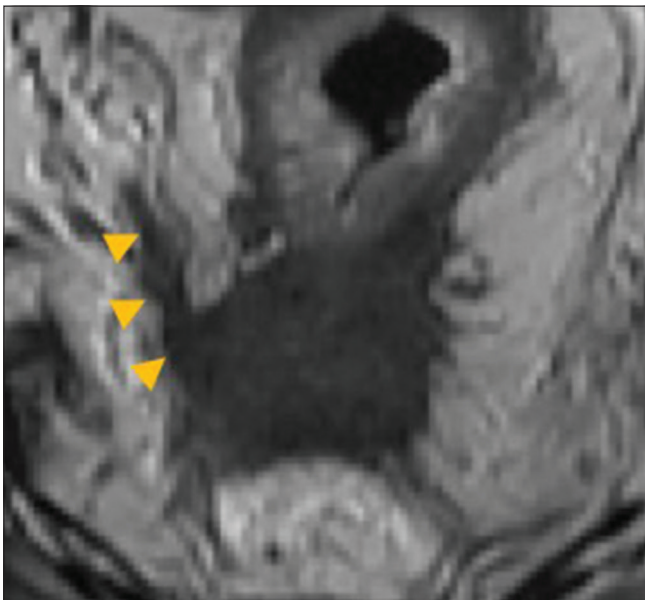
Our study included 100 MRI reports from 87 patients (79% males; mean age: 47 years; range: 19-75). All reports were finalized by dedicated onco-radiology faculty. 50 MRIs were finalized by subspecialty GI onco-radiologists working specifically with the colorectal disease group, while 50 MRIs were finalized by onco-radiologists not working with the colorectal group. Overall, the total number of parameters reported in the MRI reports of these patients increased from a median value of 10 (range 6-13) to 14 (range 12-14) [Table 1 and Figure 7]. Out of the 13 patients who had both free text as well as template reports, the total parameters mentioned in their reports increased from a median value of



**Figure 4:** Depth of extra-serosal extension on axial T2-weighted image (measured by the orange colored line shown in the image)



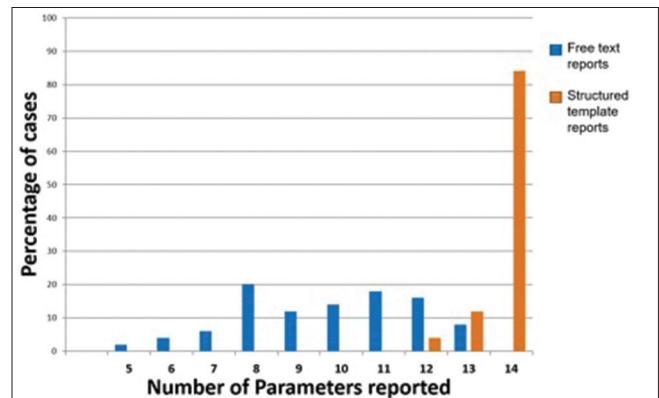
**Figure 5:** Involvement of mesorectal fascia from 8 to 9 o'clock position on axial T2-weighted image as shown by the yellow arrows (Circumferential resection margin status- positive)



**Figure 6:** Oblique coronal T2-weighted image showing extramural vascular invasion as shown by the yellow arrowheads

9 (range 5-12) to 13 (range 12-14). The common unreported parameters prior to template introduction included T staging, presence or absence of restricted diffusion, anterior peritoneal reflection (APR) involvement and the presence or absence of extramural vascular invasion (EMVI). These were reported in 16%, 22%, 30% and 50%, respectively. These improved to 98-100% reporting after template introduction.

Maximum improvement was in T staging (16% to 98%) ( $P < 0.0001$ ), restricted diffusion on DWI (from 22% to 100%) ( $P < 0.0001$ ) and APR involvement



**Figure 7:** Number of quality parameters mentioned in the report before and after the implementation of the template

(from 30% to 100%) ( $P < 0.0001$ ). The most common unreported parameter after template introduction was the “tumoral T2 signal intensity” (unreported in 4% cases).

The number of parameters mentioned increased from a median value of 9 to a median value of 14 amongst general onco-radiologists, and from a median value of 10 to a medial value of 14 amongst the GI onco-radiologists. Our anonymous survey on the rectal MRI structured template generated 11 responses [Table 2 and Figure 8].

All the 11 participants said that there was a decreased need to talk to the radiologist to clarify the report after the new template was introduced. 91% of them said that there was an improvement in the quality of reporting as compared to the previous reports (the average rating on a scale of 1 to 10 improved from a value of 5 to 6 to a value of 8 to 9).

**Table 2: List of questions in our anonymous survey regarding feedback on the rectal MRI structured template****Question**

Have you been exposed to MRI rectum reports both before and after the introduction of the new template?

Do you think the new template is an improvement in the quality of reporting as compared to the previous reports?

Do you think the new template is easier to interpret than the free text report used previously?

Do you feel you a decreased need to talk to the radiologist to clarify the report after the new template has been introduced?

On a scale of 1-10 (10 being the best), how would you rate the quality of MRI reports before the introduction of the template?

On a scale of 1-10 (10 being the best), how would you rate the quality of MRI reports after the introduction of the template?

On a scale of 1-10 (10 being the best), how accurate do you think our current MRI reports are in providing you with all the relevant findings?

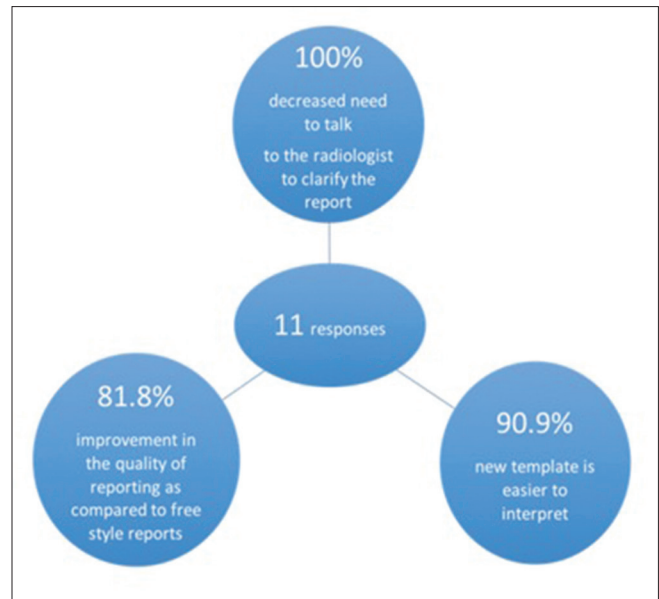Please give suggestions for further improving the MRI rectum template, or any other specific feedback and suggestions for the department.

The detailed responses can be viewed online at the link below: <https://docs.google.com/forms/d/12GlpC0-TeYAz0wkif73ducqd5SeanJkzZPPuHU6rR-A/edit?usp=sharing>.

**Discussion**

Radiologists play a vital role in not just interpreting the imaging findings, but also in communicating the findings to the referring clinicians. For this, it is important for the radiology reports to be accurate and to precisely answer the clinical questions.<sup>[7]</sup> Adoption of structured reporting is the key element in providing optimal quality reports to the referring physicians and hence ultimately contribute to patient care.<sup>[8]</sup> The recent recommendations suggest a transformation from “prose” reports to reports with structured templates.<sup>[8]</sup> Studies have evaluated the impact of structured templates in reporting abdominal scans,<sup>[9]</sup> hepatocellular carcinoma reporting<sup>[10]</sup> as well as prostate imaging.<sup>[11]</sup> These studies showed a better interdisciplinary communication of imaging findings, higher comprehensiveness as well as more consistency across the various reports.<sup>[9-11]</sup> In rectal cancer, accurate reporting of MRI is essential for determining local tumor staging and appropriate management.

Our study shows that the introduction of a structured reporting template resulted in a significant improvement in the reporting of 6/14 essential parameters needed to be commented on for appropriate patient management. These included vital information on T staging, EMVI and presence of restricted diffusion which was missing in many of the initial free text reports, which would have potentially significant impact on patient care. The improvement was seen in both subspecialty GI onco-radiologist reports as also ‘general’ onco-radiologist reports. It also resulted in a higher satisfaction rate amongst the referring oncologists.

**Figure 8:** Responses to the anonymous online survey conducted for the members of the colorectal tumor board after introduction of dedicated rectal MRI template

Our results are in accordance with earlier studies on structured reporting for rectal cancer MRI. In a study by Tersteeg *et al.*<sup>[11]</sup> which analyzed 492 MRI reports, 6 items were described significantly more frequently after the implementation of standardized reporting. In another study by Sahni *et al.*<sup>[12]</sup> 7/14 quality measures were significantly more frequently documented after the implementation of the structured template. P. J. Brown *et al.*<sup>[12]</sup> analyzed 360 primary rectal cancer staging MRI reports, which showed a statistically significant increase in the inclusion of certain findings like relationship of tumor with MRF (from 65.9% in free text reports to 96.3% in template reports), and the presence of EMVI (from 51.6% in free text reports to 98.7% in template reports). The study revealed significant improvement in the ‘completeness’ percentage score with use of the template, a median of 96% inclusion of all variables (IQR: 92-97%), compared to median 57% inclusion of all variables (IQR- 55–68%) respectively.<sup>[12]</sup>

There are several limitations to our study, including a relatively small sample size, lack of assessment of the accuracy of the reports and lack of objective assessment of the clinical impact of the improved quality reports (although subjective assessment of satisfaction of the referring oncologists was performed with an anonymous survey). There was also the possibility of a bias in the survey as majority of the respondents would be people who were involved in the process of creating the template initially. Finally, we cannot comment of the utility of structured templates elsewhere in radiology, as our study was limited to evaluating the use of structured template in rectal cancer MRI reporting.

In conclusion, the introduction of a structured template for rectal cancer significantly improved the quality of our

reports, across both general and subspecialty radiologists, as also the satisfaction of referring providers.

#### Financial support and sponsorship

Nil.

#### Conflicts of interest

There are no conflicts of interest.

#### References

1. Tersteeg JJC, Gobardhan PD, Crolla RMPH, Kint PA, Niers-Stobbe I, Boonman-de Winter LJM, *et al.* Improving the quality of MRI reports of preoperative patients with rectal cancer: Effect of national guidelines and structured reporting. *Am J Roentgenol* 2018;1:1240-4.
2. Sahni VA, Silveira PC, Sainani NI, Khorasani R. Impact of a structured report template on the quality of MRI reports for rectal cancer staging. *Am J Roentgenol* 2015;205:584-8.
3. Nörenberg D, Sommer WH, Thasler W, D'haese J, Rentsch M, Kolben T, *et al.* Structured reporting of rectal magnetic resonance imaging in suspected primary rectal cancer: Potential benefits for surgical planning and interdisciplinary communication. *Invest Radiol* 2017;52:232-9.
4. Gollub MJ, Arya S, Beets-Tan RG, Gonen M, Jhaveri K, Kassam Z, *et al.* Use of magnetic resonance imaging in rectal cancer patients: Society of Abdominal Radiology (SAR) rectal cancer disease-focused panel (DFP) recommendations 2017. *Abdom Radiol* 2018;43:2893-902.
5. Beets-Tan RG, Lambregts DM, Maas M, Bipat S, Barbaro B, Curvo-Semedo L, *et al.* Magnetic resonance imaging for clinical management of rectal cancer: Updated recommendations from the 2016 European Society of Gastrointestinal and Abdominal Radiology (ESGAR) consensus meeting. *Eur Radiol* 2018;28:1465-75.
6. Cho SH, Cho YS, Choi IY, Ha HI, Huh J, Hur BY, *et al.* Essential items for structured reporting of rectal cancer MRI: 2016 consensus recommendation from the Korean Society of Abdominal Radiology. *Korean J Radiol* 2017;18:132-51.
7. Ganeshan D, Duong PA, Probyn L, Lenchik L, McArthur TA, Retrouvey M, *et al.* Structured reporting in radiology. *Acad Radiol* 2018;25:66-73.
8. Neri E, Brady AP, Gibaud B, Visser J, Nahum Goldberg S, Pyatigorskaya N, *et al.* ESR paper on structured reporting in radiology *Insights Imaging* 2018;9:1-7.
9. Herts BR, Gandhi NS, Schneider E, Coppa CP, Mody RN, Baker ME, *et al.* How we do it: Creating consistent structure and content in abdominal radiology report templates. *Am J Roentgenol* 2019;212:490-6.
10. Flusberg M, Ganeles J, Ekinci T, Goldberg-Stein S, Paroder V, Kobi M, *et al.* Impact of a structured report template on the quality of CT and MRI reports for hepatocellular carcinoma diagnosis. *J Am Coll Radiol* 2017;14:1206-11.
11. Wetterauer C, Winkel DJ, Federer-Gsponer JR, Halla A, Subotic S, Deckart A, *et al.* Structured reporting of prostate magnetic resonance imaging improves interdisciplinary communication. *Eur Urol Suppl* 2018;17:e2562.
12. Brown PJ, Rossington H, Taylor J, Lambregts DM, Morris E, West NP, *et al.* Standardised reports with a template format are superior to free text reports: The case for rectal cancer reporting in clinical practice. *Eur Radiol* 2019;22:1-8.