

Skin reactions caused by bone-anchored hearing aid (BAHA) implantation

Gen-di Yin, Xiangli Zeng, Peng Li*

Department of Otorhinolaryngology, Third Affiliated Hospital, Sun Yat-Sen University, Guangzhou 510630, China

Received 13 November 2015; revised 12 January 2016; accepted 13 January 2016

Abstract

Objective: To report a case of intractable skin reactions caused by bone-anchored hearing aid (BAHA) implantation to improve our understanding and treatment of BAHA implantation-caused skin reactions.

Methods: We reported a case of severe skin reactions caused by BAHA implantation. Related literature were also reviewed.

Results: We found grade IV skin reactions, including hyperplasia around the implant, which led to the removal of the BAHA implant 10 months after implantation. The findings indicated poor skin hygiene, allergy to titanium and inadequate surgical skills as the possible causes of the skin reaction.

Conclusion: Skin adverse reactions, usually rare in BAHA implantation patients, may cause implant removal and implantation failure. We suggest to further investigate the mechanisms underlying titanium allergy.

Copyright © 2016, PLA General Hospital Department of Otolaryngology Head and Neck Surgery. Production and hosting by Elsevier (Singapore) Pte Ltd. This is an open access article under the CC BY-NC-ND license (<http://creativecommons.org/licenses/by-nc-nd/4.0/>).

Keywords: Conductive hearing disorder; Bone-anchored hearing aid (BAHA); Skin reactions

1. Introduction

The bone-anchored hearing aid (BAHA) has been used by over 80,000 patients worldwide since its first clinical application in 1971. The BAHA is mainly applied in patients with conductive, mixed or unilateral hearing losses (Mazita et al., 2009). The BAHA consists of three parts, a titanium implant, a titanium base, and a detachable sound processor. The stability of the titanium implant is critically important for installing the sound processor and titanium metal base. In most reports, BAHA implants were stable, and patients had significant hearing improvement. However, falling off or removal of BAHA implants has been reported in appropriately 4%–10% of patients due to various causes (Arnold et al., 2011; Hobson et al., 2010; Badran et al., 2009). Numerous studies have

focused on BAHA implantation failures. In the present study, we report a case of severe skin reactions caused by BAHA implantation. Possible causes of skin reactions and BAHA implantation failure are analyzed.

2. Clinical manifestations

The study was approved by the Medical Research Ethics Committee of the Third Affiliated Hospital of Sun Yat-sen University, Guangzhou, China. All human studies were performed in accordance with the ethical standards laid down in the 1964 Declaration of Helsinki and its later amendments. The participant involved in the study signed informed consent forms.

A 20-year-old male was admitted to our hospital due to discharging ears with hearing loss for over 10 years (Fig. 1). The patient complained of recurring discharges of yellow pus of small amount and foul odor from both ears, which would aggravate when exposed to water or when having a cold. The patient also reported bilateral hearing loss, worse in right ear.

* Corresponding author.

E-mail address: lp76@163.net (P. Li).

Peer review under responsibility of PLA General Hospital Department of Otolaryngology Head and Neck Surgery.

The patient had no earache, dizziness, tinnitus, facial pain or numbness, headache, or nasal congestion. The patient was diagnosed with cleft lip and palate at birth, which were repaired when he was 5 years old.

The implanted titanium plate was removed due to rejection reactions when he was 6 years old. Temporal bone CT scan showed bilateral chronic otitis media. Hearing examinations suggested conductive hearing disorders and eustachian tube dysfunction. Pre-operative BAHA softband test showed improved hearing. BAHA implantation was performed in the left temporal bone under local anesthesia. The skin around the titanium base healed well within the first three months after BAHA implantation (Fig. 2). However, hyperplasia and mild swelling of the skin around the titanium base occurred after 3 months (Fig. 2). Daily dressings exchange and local Mometasone had little effects. Hyperplasia was partially controlled by three skin removal surgeries (Fig. 2), but the titanium base was eventually completely covered by skin growth (Fig. 2) and had to be removed 10 months after implantation (Fig. 2).

3. Discussion

Typically BAHA installation includes surgical implantation of the BAHA in the temporal bone or attaching the BAHA to the head with a soft band. The titanium base and sound processor are installed six weeks after BAHA implantation surgery when the titanium implant is stable in the temporal bone through bone fusion. It has been reported that surgical BAHA implantation improves hearing by 5–20 dB across 1–4 kHz. Softband BAHA is usually used in children who have relatively thin temporal bone that can cause implant instability (vanderPouw et al., 1999). Generally, surgical BAHA implantation exhibits better hearing improvement than softband BAHA.

Most patients wearing softband BAHA have congenital atresia and microtia. It has been reported that 87.9% of softband HAHA are used by congenital atresia and microtia patients (Asma and Ubaidah, 2013). Otitis media usually causes conductive hearing loss. Tympanoplasty and ossicular chain reconstruction are typically conducted to improve hearing in otitis media patients. However, hearing reconstruction or conservative treatments are not effective for some otitis media patients due to malformation of middle and external ears and eustachian tube dysfunction. Therefore, BAHA implantation is an alternative approach for these otitis media patients to improve hearing, as BAHA implantation is not affected by ear drainage. The patient in the present study had congenital cleft lip and palate and had undergone a uvulopalatoplasty surgery. It has been reported that hearing improvement after uvulopalatoplasty is seen only in some patients of congenital cleft lip and palate due to structural and functional abnormalities of tensor veli palate and levator muscles, which affect eustachian tube function (Alper et al., 2012). Eustachian tube dysfunction, which can lead to nasopharyngeal reflux into the middle ear cavity and repeated middle ear infections, was identified in this patient prior to surgery. Relapse of middle ear infections after hearing reconstruction surgery is often reported in patients with eustachian tube dysfunction. Therefore, BAHA implantation rather than tympanoplasty surgery was considered for this patient.

Two major skin reactions of the BAHA implantation surgery have been documented. Flap necrosis, although still at low incidences, is the most common short-term skin reaction (Fontaine et al., 2014). Long-term skin reactions, which have been reported in 15–21% of BAHA recipients, include mainly inflammation and soft tissue infections. The skin around the abutment often shows redness, tenderness, granulation and secretions, which are usually caused by infiltrations by B cells,

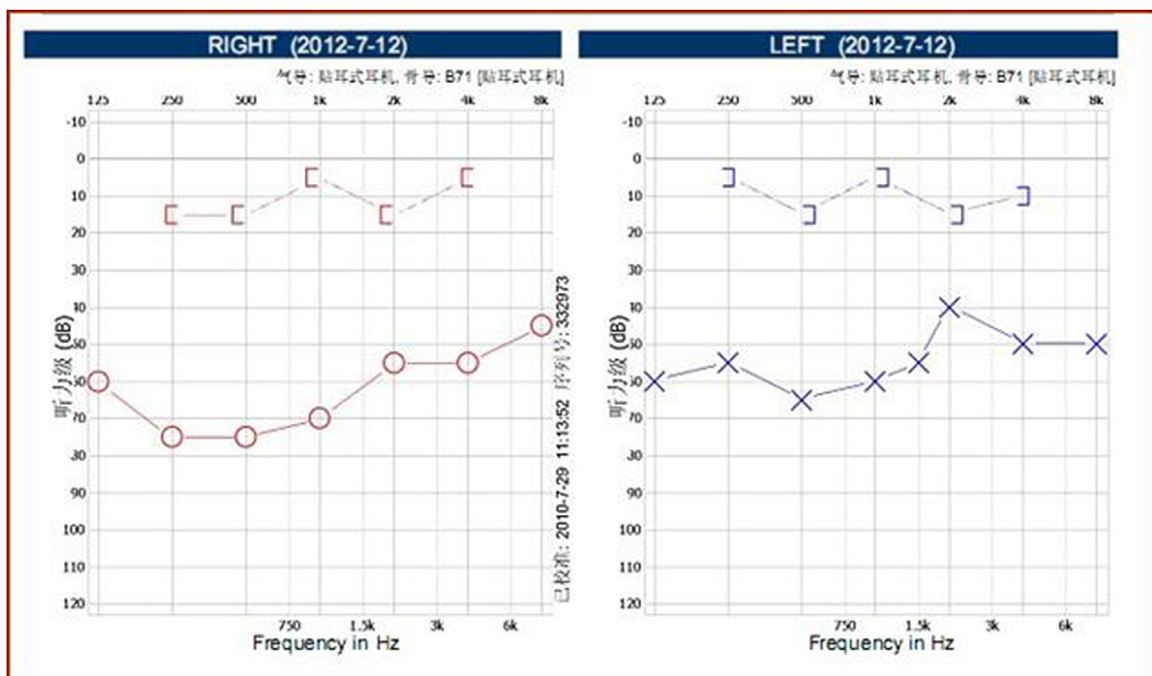


Fig. 1. Pure tone hearing thresholds indicating bilateral conductive loss, with air bone gaps of 25–40 dB.

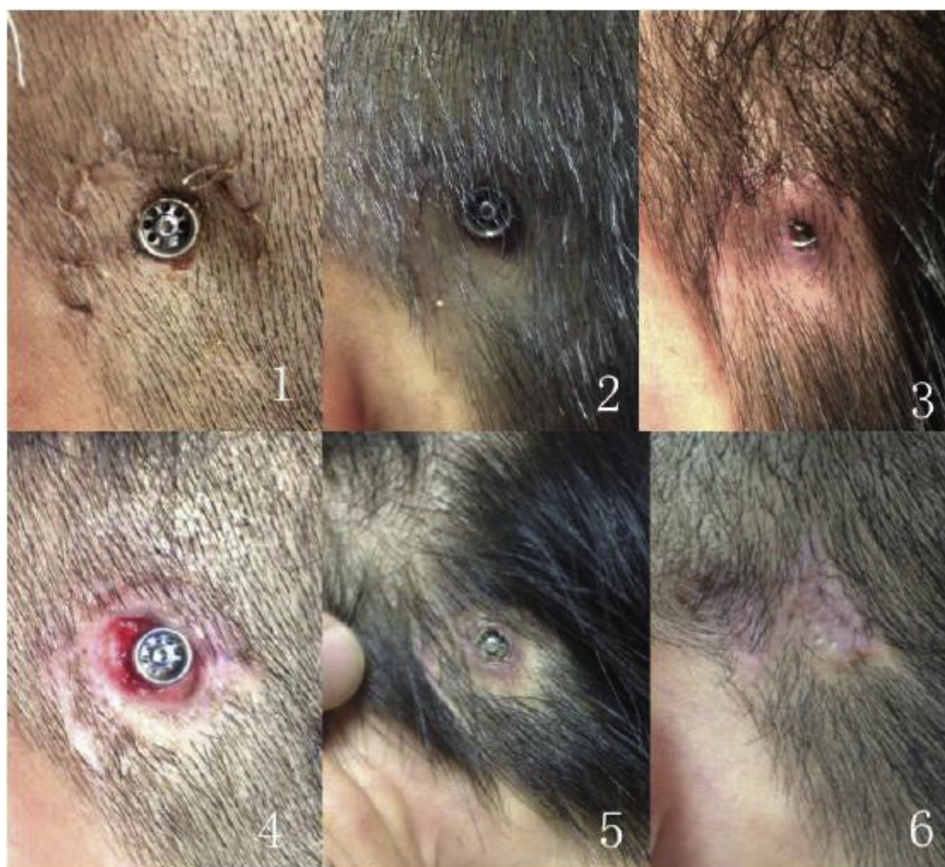

Fig. 2. Skin reactions after BAHA implantation. (1). Five days after BAHA implantation surgery. (2). Two weeks after BAHA implantation surgery. (3). Hyperplasia at three months after BAHA implantation surgery. (4). After first skin removal surgery. (5). After third skin removal surgery. (6). After BAHA removal.

multinucleated cells and plasma cells (Holgers, 2000). Skin reactions caused by BAHA implantation are typically evaluated using the scoring system described by Holgers et al. (1988), with no skin irritation being grade 0, mild redness being grade I, redness and moisture being grade II, granuloma formation representing grade III, and clear local skin infections defined as grade IV.

Grades I or II skin reactions are managed by abutment and local skin cleaning with soft brushes and local antibiotics application. Granuloma in grade III skin reactions should be removed. In grade IV skin reactions, skin infections must be controlled and the BAHA implant should be removed as soon as possible (Holgers et al., 1988).

In the present case, skin reactions of grade III including local swelling and granulation tissue were observed three months after the BAHA implantation surgery. As skin cleaning and resection failed to inhibit skin hyperplasia, skin infections started to develop, which further stimulated skin hyperplasia, forming grade IV skin reaction. Since no skin reactions were observed immediately after the BAHA implantation surgery, the skin reactions were of delayed type hypersensitivity (DTH) caused by continuous exposure of skin to the implant. The implant was removed due to uncontrollable infections and hyperplasia. Physicians must understand both the causes and therapy principles for skin reactions after BAHA implantation to effectively manage skin reactions. Previous studies

have reported a number of causes of skin hyperplasia around the implant, including susceptibility to scars, inappropriate wear of speech processors, friction between metal base and skin, loose base, certain skin diseases such as eczema, psoriasis, beaded red moss disease and hyperhidrosis, and poor hygiene of the skin around the base (vanderPouw et al., 1999; Fontaine et al., 2014; de Wolf et al., 2009).

To prevent skin hyperplasia and increase the successful rate of BAHA implantation, physicians should know the patient's history of susceptibility to scars. BAHA implantation is not recommended for patients with high susceptibility to scars and sensitivity to titanium. In addition, patients with skin diseases should be successfully treated before the BAHA implantation surgery. Improvement of BAHA implantation skills can reduce the incidence of skin reactions. For example, thin flap, clean removal of hair follicles and other subcutaneous tissues, and direct suture of the flap and periosteum to reduce friction between the metal base and flap can reduce the incidence of skin hyperplasia. Chandrasekhar et al. suggested that a metal base 8.5 mm higher than the skin may help reduce friction between the base and skin and thus the incidence of skin hyperplasia (Pelosi and Chandrasekhar, 2011). In addition, patients should be educated about good hygiene of the skin around the base. Local application of silver nitrate and cortisol can also inhibit skin hyperplasia (Van Rijswijk and Mylanus, 2008). Moreover, subcutaneous tissue removal or repair

using skin flaps can be considered for the treatment of skin hyperplasia caused by BAHA implantation (Stalfors and Tjellström, 2008).

In the present case, the patient had undergone repair of cleft lip and palate using a titanium plate, which had to be removed due to local reactions. We speculate that the patient is allergic to titanium. BAHA removal due to suspicious allergy to titanium has been reported previously (House and Kutz, 2007; Egusa et al., 2008; Mine et al., 2010), but the mechanisms underlying allergy to titanium are not understood. In addition, the patient in the present case had poor hygiene of the skin around the BAHA implant, which caused repeated skin infections and may have contributed to skin hyperplasia. Furthermore, this was the first BAHA implantation surgery the authors and the relatively thick skin flap may have also contributed to BAHA implantation Failure.

BAHA has been used to improve hearing for over 30 years and extensive experiences on BAHA implantation surgery have been accumulated. Skin reactions after BAHA implantation surgery are mainly associated with poor skin hygiene, allergy to titanium and inadequate surgery skills. Skin hygiene and surgery skills can be improved by patient education and surgeon training. However, the mechanisms underlying titanium allergy are not clear. The immunological pathways and histocompatibility issues in patients who are allergic to titanium BAHA need to be further investigated.

Conflict of interest

The authors have no conflicts of interest to declare.

Acknowledgment

This study was supported by Guangdong Provincial Science and Technology Project:2013B022000046.

References

- Alper, C.M., Losee, J.E., et al., 2012. Postpalatoplasty Eustachian tube-function in young children with cleft palate. *Cleft Palate Craniofac. J.* 49 (4), 504–507.
- Arnold, A., Caversaccio, M.D., et al., 2011. Surgery for the bone-anchored hearing aid. *Adv. Otorhinolaryngol.* 71, 47–55.
- Asma, A., Ubaidah, M.A., 2013. Surgical outcome of bone anchored hearing aid (BAHA) implant surgery: a 10 years experience. *Indian J. Otolaryngol. Head Neck Surg.* 65 (3), 251–254.
- Badran, K., Arya, A.K., Bunstone, D., et al., 2009. Long-term complications of bone-anchored hearing aids: a 14-year experience. *J. Laryngol. Otol.* 123 (2), 170–176.
- de Wolf, M.J., Hol, M.K., Mylanus, E.A., et al., 2009. Bone-anchored hearing aid surgery in older adults: implant loss and skin reactions. *Ann. Otol. Rhinol. Laryngol.* 118, 525–531.
- Egusa, H., Ko, N., Shimazu, T., Yatani, H., 2008. Suspected association of an allergic reaction with titanium dental implants: a clinical report. *J. Prosthet. Dent.* 100, 344–347.
- Fontaine, N., Hemar, P., Schultz, P., et al., 2014. BAHA implant: implantation technique and complications. *Eur. Ann. Otorhinolaryngol. Head Neck Dis.* 131 (1), 69–74.
- Hobson, J.C., Roper, A.J., Andrew, R., et al., 2010. Complications of bone-anchored hearing aid implantation. *J. Laryngol. Otol.* 124 (2), 132–136.
- Holgers, K.M., 2000. Characteristics of the inflammatory process around skin-penetrating titanium implants for aural rehabilitation. *Audiology* 39 (5), 253–259.
- Holgers, K.M., Tjellström, A., et al., 1988. Soft tissue reactions around percutaneous implants: a clinical study of soft tissue conditions around skin-penetrating titanium implants for bone-anchored hearing aids. *Am. J. Otol.* 9 (1), 56–59.
- House, J.W., Kutz Jr., J.W., 2007. Bone-anchored hearing aids: incidence and management of postoperative complications. *Otol. Neurotol.* 28, 213–217.
- Mazita, A., Fazlina, W.H., Abdullah, A., et al., 2009. Hearing rehabilitation in congenital canal atresia. *Singap. Med. J.* 50 (11), 1072–1076.
- Mine, Y., Makihira, S., Nikawa, H., Murata, H., Hosokawa, R., Hiyama, A., Mimura, S., 2010. Impact of titanium ions on osteoblast, osteoclast and gingival epithelial-like cells. *J. Prosthodont. Res.* 54, 1–6.
- Pelosi, S., Chandrasekhar, S.S., 2011. Soft tissue overgrowth in bone-anchored hearing aid patients: use of 8.5 mm abutment. *J. Laryngol. Otol.* 125 (6), 576–579.
- Stalfors, J., Tjellström, A., 2008. Skin reactions after BAHA surgery: a comparison between the U-graft technique and the BAHA dermatome. *Otol. Neurotol.* 29 (8), 1109–1114.
- Van Rijswijk, J.B., Mylanus, E.A., 2008. Intralesional triamcinolone acetonide injection in hypertrophic skin surrounding the percutaneous titanium implant of a bone-anchored hearing aid. *J. Laryngol. Otol.* 122, 1368–1370.
- vanderPouw, C.T., Mylanus, E.A., et al., 1999. Percutaneous implants in the temporal bone for securing a bone conductor: surgical methods and results. *Ann. Otol. Rhinol. Laryngol.* 108 (6), 532–536.