



Case report

A welder with pneumosiderosis: a case report

Imran Khalid¹, Tabindeh J Khalid² and Jeffrey H Jennings^{1*}

Address: ¹Henry Ford Hospital, Division of Pulmonary and Critical Care, 2799 W Grand Blvd, Detroit, MI, 48202, USA and ²Henry Ford Hospital, Department of Family Medicine, 2799 W Grand Blvd, Detroit, MI, 48202, USA

Email: IK - dr.imrankhalid@yahoo.com; TJK - tabindeh@yahoo.com; JHJ* - jjennin2@hfhs.org

* Corresponding author

Published: 20 April 2009

Received: 24 December 2008

Cases Journal 2009, 2:6639 doi: 10.1186/1757-1626-2-6639

Accepted: 20 February 2009

This article is available from: <http://casesjournal.com/casesjournal/article/view/2/4/6639>

© 2009 Khalid et al; licensee Cases Network Ltd.

This is an Open Access article distributed under the terms of the Creative Commons Attribution License (<http://creativecommons.org/licenses/by/3.0>), which permits unrestricted use, distribution, and reproduction in any medium, provided the original work is properly cited.

Abstract

Pneumosiderosis or Welder's lung is an occupational lung disease which is usually seen after chronic exposure to iron dust. We present a case of a 64-year-old welder in whom the diagnosis of pneumosiderosis was made by lung biopsies. We also briefly review the literature regarding the disease, its prognosis and association with development of lung cancer. Avoidance of iron dust exposure and implementing prevention strategies in people at risk are the mainstay of therapy.

Introduction

Pneumosiderosis or Welder's lung is an occupational lung disease which is usually seen after chronic exposure to iron dust, especially in welders. We present a case of pneumosiderosis and briefly review the literature regarding the disease.

Case presentation

A 64-year-old African American male was referred to the pulmonary clinic for evaluation of abnormal imaging. His primary care physician had obtained a chest radiograph after the patient presented with two weeks of a productive cough. The patient otherwise was asymptomatic. He had been diagnosed with chronic obstructive pulmonary disease, diabetes, allergic rhinitis and benign prostatic hypertrophy. His medications which adequately controlled his medical problems included inhaled triamcinolone, albuterol, metformin and tamsulosin. He had been an active smoker until 8 years ago and had a 60 pack-year history of smoking prior to that. He did not drink alcohol

and never used illicit drugs. He worked in an automobile factory for about twenty five years. However, for the last fifteen years his only job was as a steel welder where he was involved in welding the steel frames for the automobiles. During that time, it was the only task that he was doing in the factory. He did use eye protective shields and a face mask which were provided to him. The part of the building he worked in was small and enclosed, and the exhaust system was also not optimal. There were no employee health surveillance programs implemented by the employer until about ten years ago. However, these were done infrequently and patient was not subjected to one while he was working.

When patient was seen in the pulmonary clinic, he still complained of occasional productive cough, but otherwise denied having fevers, night sweats, chest pain, shortness of breath, orthopnea or unintentional weight loss. On physical examination, his vitals revealed a blood pressure of 123/73, pulse of 68/minute, respiratory rate of

17/minute and temperature of 97.8 Fahrenheit. Pulmonary examination did not reveal any crackles or wheezing. The remainder of the examination was also within normal limits. Spirometric assessment revealed an FEV₁ of 2.59 liters (104% of predicted) and FVC of 3.83 liters (113% of predicted). However FEV₃/FVC ratio was reduced suggesting mild obstruction in the mid-flow range. His chest radiograph (CXR) showed a pattern of reticular-nodular opacities bilaterally, with lower lung field predominance (Figure 1). A computed tomographic scan (CT) of the chest showed multiple small reticulonodular opacities without lymphadenopathy (Figure 2). As the patient was having recurrent episodes of productive cough, in order to evaluate for underlying infection, he underwent a bronchoscopy with bronchoalveolar lavage (BAL) and transbronchial biopsies. The bacterial, viral, fungal and acid fast bacilli cultures from the BAL fluid were negative. The biopsy specimens showed dense nodular interstitial fibrosis containing clusters and sheets of macrophages having cytoplasmic iron pigment (Figure 3). This was also confirmed with Prussian Blue staining. The diagnosis of pneumosiderosis (Welder's lung) was made. Ferritin levels were not measured in the BAL as the diagnosis was easily established by the biopsy specimen. The patient was advised to change his job, as even after preventive measures he developed Welder's lung from significant iron dust exposure. His intermittent bouts of productive cough were treated with bronchodilators and steroids.

The patient retired from his job after his initial evaluation. His respiratory symptoms, which first appeared after about fifteen years of the initial exposure to iron dust, resolved

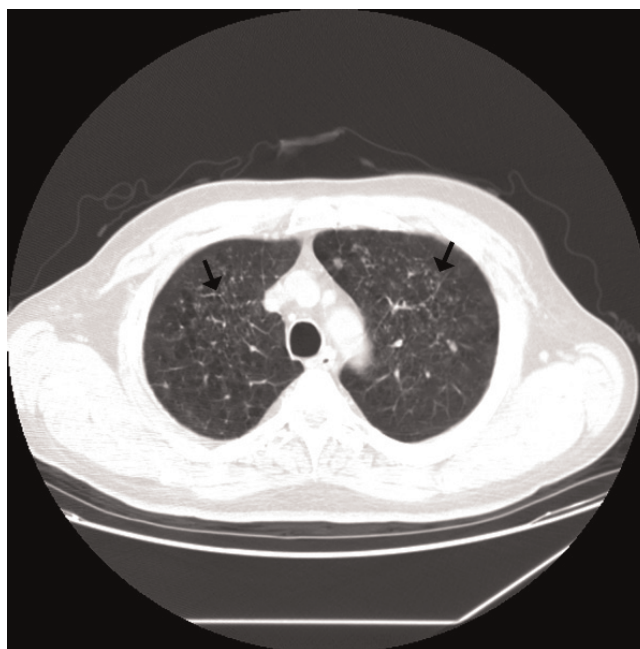

Figure 2.
Computed Tomographic (CT) Scan of the Chest: Arrows show multiple small reticulonodular opacities.

within a month with supportive therapy. One year after the initial presentation, he is doing well without any pulmonary complaints.

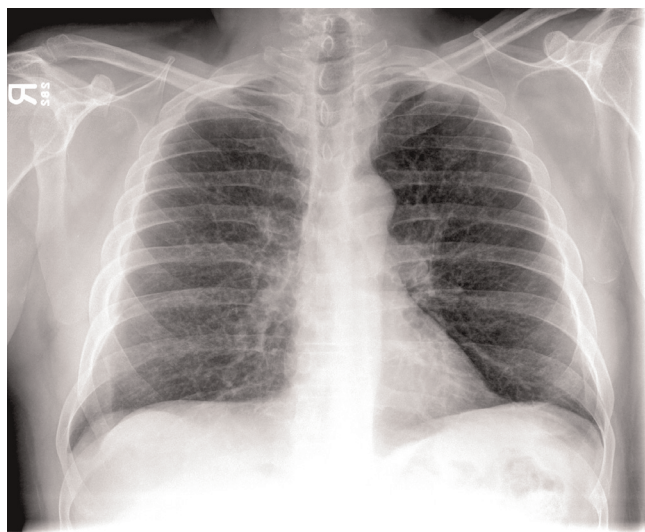


Figure 1.
Chest Radiograph: Increased reticulonodular interstitial opacities bilaterally, more prominent in the lower lung fields.

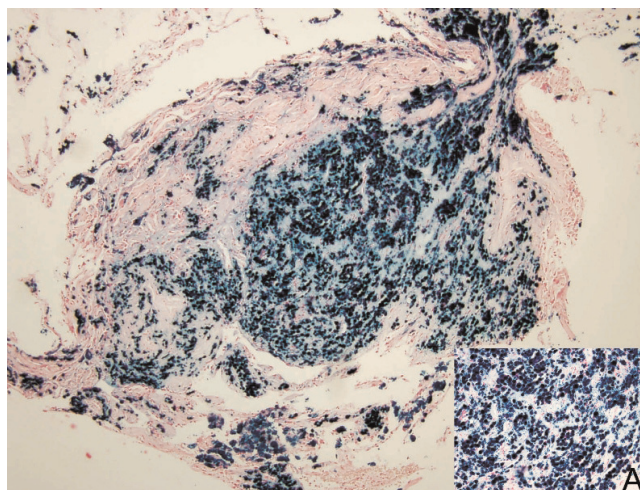


Figure 3.
Lung Biopsy: Dense nodular interstitial fibrosis containing clusters and sheets of macrophages with cytoplasmic iron pigment. "Insert A" shows the Prussian Blue staining of the iron pigment.

Discussion

Pneumosiderosis, or more commonly referred to as Welder's lung, is an occupational lung disease that occurs after chronic inhalation of iron dust particles, especially in welders. Although it takes years of exposure for a patient to become symptomatic, rapid development of symptomatic disease within a year after exposure has been reported [1]. In addition, high intensity brief exposures to iron dust can also result in future symptoms [2]. The symptoms are usually non-specific and most commonly include shortness of breath, cough and sputum production [3]. With continued exposure patients can develop chronic interstitial lung disease, chronic bronchitis regardless of smoking, decline in pulmonary function and persistent symptoms [2,3,4]. Development of progressive massive fibrosis is relatively rare. The serum ferritin levels are typically elevated along with elevated ferritin in BAL [5]. The CT scan usually shows multiple small centrilobular nodules in the lungs [5,6]. A case of spontaneous pneumothorax in a patient with Welder's lung has also been described [6].

The treatment is usually symptomatic. Prognosis is generally favourable if strict avoidance from the iron dust is adopted. However, an association with lung cancer has been postulated in these patients [7,8]. Among the stainless steel welders, the risk for development of lung cancer increases significantly with increasing accumulative welding particulate exposure and duration of exposure [8]. This risk remains even after controlling for the smoking status of the person [7,8].

Conclusion

Pneumosiderosis or Welder's lung is an occupational disease that occurs mainly in welders after prolonged exposure to iron dust. Avoidance of iron dust exposure and implementing strict prevention strategies are the mainstay of therapy in these patients.

Consent

Written informed consent was obtained from the patient for publication of this case report and accompanying images. A copy of the written consent is available for review by the Editor-in-Chief of this journal.

List of abbreviations

FEV₁, Forced expiratory volume FEV in 1 second; FVC, Forced vital capacity; FEV₃, Forced expiratory volume FEV in 3 seconds; BAL, Bronchoalveolar lavage.

Competing interests

The authors declare that they have no competing interests.

Authors' contributions

IK wrote the introduction and case report portion of the manuscript. TJK wrote the discussion. JHJ was a major contributor in preparing the images and making critical revisions to the whole manuscript. All authors read and approved the final manuscript.

References

- Ishida Y, Sera K, Ohta K, Kageshita T: **A case of rapid development of arc welder's lung during the course of a year.** *Nihon Kokyuki Gakkai Zasshi* 2003, **41**:351-355.
- Glass WI, Taylor DR, Donoghue AM: **Chronic interstitial lung disease in a welder of galvanized steel.** *Occup Med* 1994, **44**:158-160.
- Ozdemir O, Numanoglu N, Gönüllü U, Savaş I, Alper D, Gürses H: **Chronic effects of welding exposure on pulmonary function tests and respiratory symptoms.** *Occup Environ Med* 1995, **52**:800-803.
- Beckett WS, Pace PE, Sferlazza SJ, Perlman GD, Chen AH, Xu XP: **Airway reactivity in welders: a controlled prospective cohort study.** *J Occup Environ Med* 1996, **38**:1229-1238.
- Yoshii C, Matsuyama T, Takazawa A, Ito T, Yatera K, Hayashi T, Imanaga T, Kido M: **Welder's pneumoconiosis: diagnostic usefulness of high-resolution computed tomography and ferritin determinations in bronchoalveolar lavage fluid.** *Intern Med* 2002, **41**:1111-1117.
- Fidan F, Esme H, Unlu M, Acar M, Albayrak R, Dilek FH: **Welder's lung associated with pneumothorax.** *J Thorac Imaging* 2005, **20**:120-122.
- Hansen KS, Lauritsen JM, Skytthe A: **Cancer incidence among mild steel and stainless steel welders and other metal workers.** *Am J Ind Med* 1996, **30**:373-382.
- Sørensen AR, Thulstrup AM, Hansen J, Ramlau-Hansen CH, Meersohn A, Skytthe A, Bonde JP: **Risk of lung cancer according to mild steel and stainless steel welding.** *Scand J Work Environ Health* 2007, **33**:379-386.

Do you have a case to share?

Submit your case report today

- Rapid peer review
- Fast publication
- PubMed indexing
- Inclusion in Cases Database

Any patient, any case, can teach us something



**CASES
NETWORK**

www.casesnetwork.com