

[Orthopaedic Surgery]

Arthroscopic Posterior Cruciate Ligament Tibial Inlay Reconstruction: A Surgical Technique That May Influence Rehabilitation

Michael J. Salata, MD, and Jon K. Sekiya, MD*

Context: The reconstruction of isolated complete posterior cruciate ligament (PCL) injuries remains a controversial topic. Proponents for reconstruction cite the premature development of arthritis in the medial and patellofemoral compartments as a compelling reason to offer reconstruction. Currently, no consensus exists about which technique should be used to reconstruct the PCL.

Type of Study: Surgical technique.

Evidence Acquisition: A MEDLINE and PUBMED search was performed using the following combination of keywords for the years 1985-2009: *PCL*, *posterior cruciate ligament*, and *rehabilitation*. The reviewed articles were those that addressed rehabilitation of the PCL after reconstruction and were written in the English language.

Results: This PCL reconstruction technique may be more inherently stable and allow a more progressive rehabilitation program.

Conclusion: There are unique features of all-arthroscopic, double-bundle, allograft reconstruction of the PCL that allow a more aggressive approach in PCL reconstruction rehabilitation. The stability afforded by the anatomic press-fit tibial plug and the augmented tibial and augmented femoral fixation are a plus. The anatomic position of the tibial insertion avoids the “killer turn” of the transtibial approach, limiting concerns for graft abrasion with range of motion and resultant elongation. The outside-in method for the femoral tunnels also minimizes the abrasion that can occur at the “critical corner.”

Keywords: posterior cruciate ligament, rehabilitation

Isolated posterior cruciate ligament (PCL) injuries continue to produce a conundrum for treating surgeons. Biomechanical studies have suggested that the medial and patellofemoral compartments in the PCL-deficient knee experience increased abnormal forces that may lead to premature and severe arthritis.³ Historically, good outcomes were reported with nonoperative management, but more recent biomechanical and longer-term clinical studies have suggested that this is not the case.^{3,7,9,15} These less-than-optimal outcomes could be attributed to more complex injury patterns that may have been overlooked or misdiagnosed. Recent studies have also shown that high-grade (III) laxity in the PCL-deficient knee may not be an isolated injury.^{12,21,22} This examination finding is a

harbinger of a combined posterolateral corner (or posteromedial corner) and PCL injury.²¹ Some authors have advocated PCL reconstruction in patients that have this high degree of laxity (8 to 10 mm greater than the contralateral side) in an attempt to minimize the poor outcomes and premature arthrosis associated with the chronically PCL-deficient knee.^{11,14} Another clear indication for PCL reconstruction is the patient with a truly isolated PCL injury that remains symptomatic despite adequate rehabilitation.⁶ The most common indication for PCL reconstruction is the multiligamentous knee injury. A slow and more deliberate rehabilitation following PCL reconstruction has been recommended to allow the newly reconstructed ligament time to incorporate and thereby maximize the chance for

From the Department of Orthopaedic Surgery, University of Michigan, Ann Arbor, Michigan

*Address correspondence to Jon K. Sekiya, MD, MedSport, University of Michigan, 24 Frank Lloyd Wright Drive, Ann Arbor, MI 48106 (e-mail: sekiya@med.umich.edu).

Dr. Jon K. Sekiya, MD is a consultant for and receives royalties from Arthrex, Inc.

DOI: 10.1177/1941738110385308

© 2011 The Author(s)

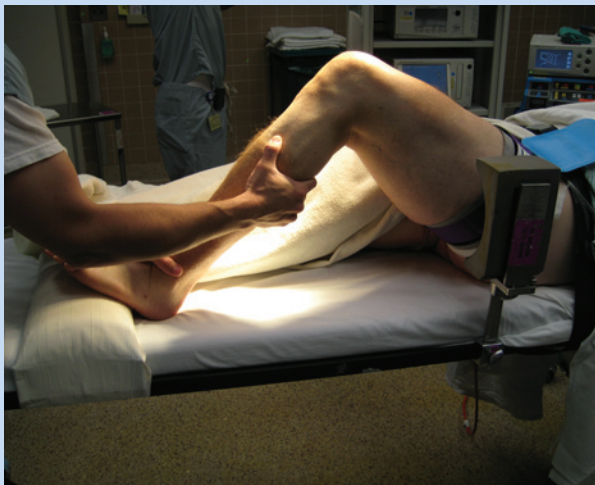

Figure 1. Positioning for the arthroscopic inlay procedure. A sandbag is taped to the table on the side of the operative extremity to allow the knee to be flexed optimally in the arc range of 45° to 90°.

stability.¹⁰ These recommendations were based on the transtibial technique and the incorporation of ligament into bone tunnels.

SURGICAL TECHNIQUE

Many variables must be considered when proceeding with surgical reconstruction of the PCL—including type of graft and technique (single vs double bundle, transtibial vs inlay, open vs arthroscopic). Although a recent review found no definitive clinical difference between single- and double-bundle reconstructions, the biomechanical studies did suggest that the latter offer some advantages over the former.¹⁶

As with any knee reconstruction, the initial step is a thorough examination under anesthesia and an arthroscopic examination. Before reconstruction of the PCL, the integrity of all ligaments, menisci, and chondral surfaces is thoroughly evaluated, and all associated injuries are addressed. Special attention should be paid to medial and lateral compartment opening with valgus or varus stress applied, to accurately diagnose posteromedial or posterolateral corner injury, which may negatively affect outcomes if not addressed.

Positioning

A radiolucent table is used to facilitate the use of fluoroscopy, which is necessary for accurate creation of the tibial socket. Most of the procedure is performed between 45° and 90° of flexion, facilitated by a sandbag taped to the table on the side of the operative extremity to allow the knee to be optimally flexed (Figure 1). By using a sandbag with the knee flexed, the contents of the popliteal fossa fall away from the posterior tibia, which allows a safe arthroscopic dissection of the tibial footprint. A well-padded pneumatic tourniquet is applied to the proximal one-third of the thigh, although this is usually not

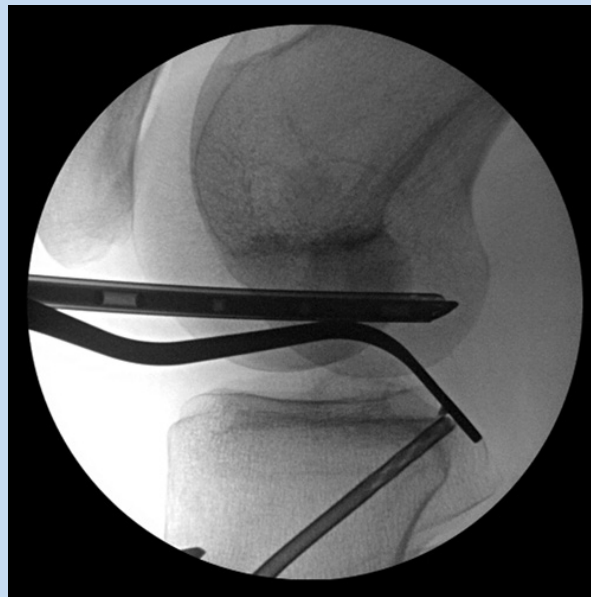

Figure 2. Fluoroscopic image showing the posterior cruciate ligament guide and the cannulated drill creating the tibial socket.

inflated. By working without a tourniquet, it is easier to detect a vascular injury if one were to occur. A flip-down lateral post is placed at the level of the tourniquet in the proximal one-third of the thigh and set in a high position to buttress the leg.

Portals

Slight modifications to the standard arthroscopic portals are necessary with this technique. The anterolateral portal is made in the standard fashion, but the anteromedial portal is established closer to the patellar tendon for better access to the posteromedial joint. Before passage of the graft, this anteromedial portal will be extended to a 2-cm parapatellar arthrotomy to facilitate graft passage. With the arthroscope in the posterior recess of the knee, an 18-gauge spinal needle is used to locate a posteromedial working portal, located along a line between the posteromedial edge of the tibia and the femoral condyle. To maximize its utility, the posteromedial portal should be placed approximately 1 cm proximal to the posteromedial joint line (see Video 1, available in the online version of this article at <http://sph.sagepub.com/supplemental/>). The posteromedial portal allows safe dissection of soft tissues, facilitating clearance of the tibial footprint. Once the portals are established, the remnants of the PCL are debrided from the tibial and femoral footprints.

Tibial Socket

Using fluoroscopy and direct visualization through the arthroscope, a PCL guide (Arthrex Inc, Naples, Florida) is used to place a guide pin for the tibial socket (Figure 2). The target

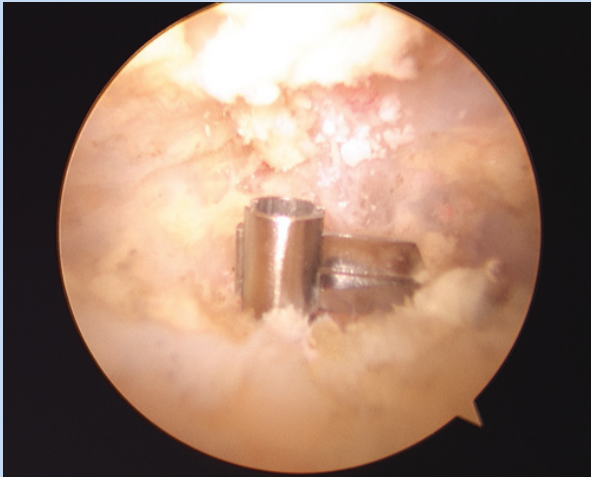

Figure 3. FlipCutter in the engaged position with the blade locked down at a 90° angle ready to begin reaming of the tibial socket.

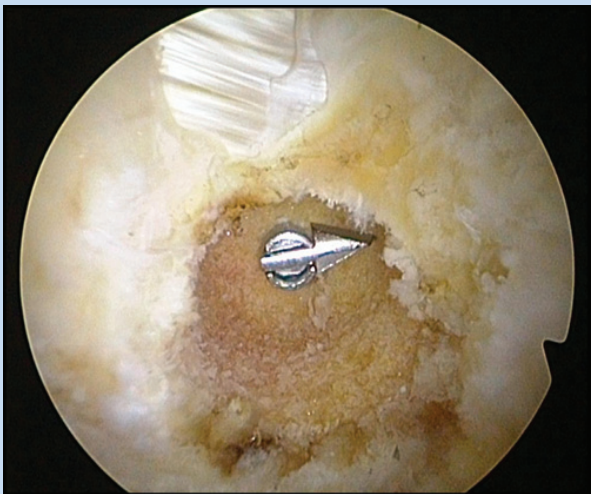


Figure 4. The tibial socket has been created by the FlipCutter to a diameter of 13 mm.

is 7 mm distal to the proximal aspect of the tibial footprint. A 3.5-mm cannulated drill is used to ream over the guide wire. Fluoroscopy and direct vision ensure that the drill does not plunge into the posterior structures of the knee. Further protection is afforded by the 13-mm footplate that is built into this drill guide. The drill and guide wire are removed and replaced by a FlipCutter (Arthrex Inc). This device is pushed through the newly created tunnel, and once visualized, the blade is engaged by “flipping” it into a position perpendicular to the main shaft in an inverted L configuration (Figure 3). Retrograde drilling of a 13-mm-diameter tibial socket to a depth of 10 to 12 mm restores the native PCL attachment and accommodates a double-bundle configuration (Figure 4). When

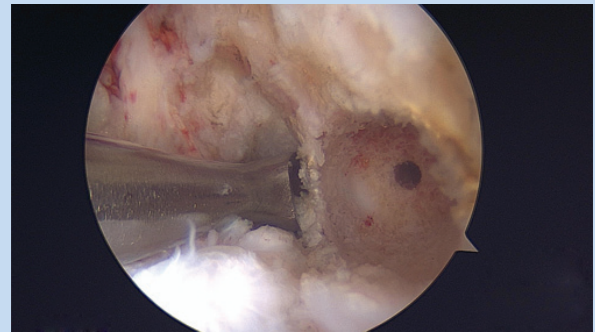


Figure 5. The tibial socket has been completed, and the FlipCutter device has been withdrawn. Note the intact posterior cortical wall, which allows the socket to secure a press fit with the corresponding bone plug.

the tunnel is complete, the blade is disengaged and the device is withdrawn (Figure 5, Video 2).

Graft Preparation

A fresh-frozen whole Achilles tendon allograft with a minimum tendon length of 7 cm is currently favored over the bone–patellar tendon–bone allograft originally described in the technique.^{4,19} Although no difference has been shown subjectively or objectively between allograft and autograft when clinical parameters are taken into account,⁸ autograft is favored by some surgeons. If autograft tissue is preferred, the most robust and amenable graft selection for this technique is either contralateral or ipsilateral quadriceps tendon (Edward M. Wojtys, MD, personal communication).

When allograft is used, 2 bundles are created by taking advantage of the natural raphe between the superficial and deep fibers of the Achilles tendon. A No. 10 blade is used to sharply develop this interval in line with the longitudinal fibers of the graft to a distance 1 cm from the calcaneal bone plug (Figure 6). The bundles will be in an anterior-to-posterior orientation when this technique is used with the larger bundle (8 to 11 mm) for the anterolateral bundle and with the smaller bundle (6 to 9 mm) for the posteromedial bundle. Each limb of the newly formed bifid graft is whip-stitched with a No. 2 braided nonabsorbable suture (Figure 1).

Sculpting of the tibial bone plug is crucial for the press fit that is the key to the stability in this procedure and justifies the early motion postoperatively.¹⁸ The calcaneal (allograft) or quadriceps (autograft) bone plug is fashioned into a single cylindrical 12-mm plug if a 13-mm socket is created with the aid of a coring reamer (Figure 1).^{5,18} A central tunnel is created in the plug and is overreamed to a diameter of 3.5 mm with a cannulated drill system (Figure 7). The 1 cm of tendon that was left in continuity is then whip-stitched with a No. 2 braided nonabsorbable suture (Figure 8). The ends of this stitch are then passed through the center tunnel in the bone plug from cortical to cancellous so that they can be used

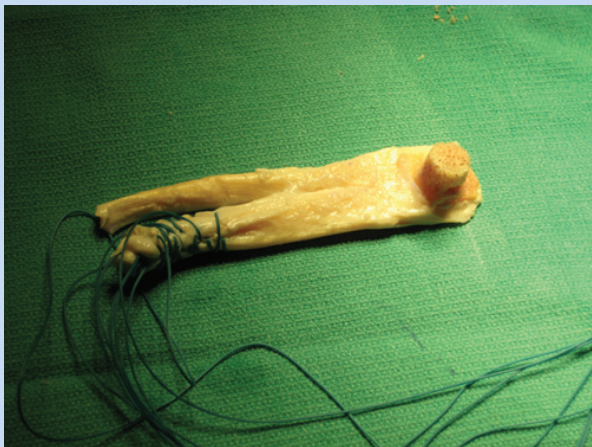

Figure 6. Two limbs are created from the allograft with a No. 10 blade in line with the longitudinal fibers of the graft to a distance 1 cm from the calcaneal bone plug.

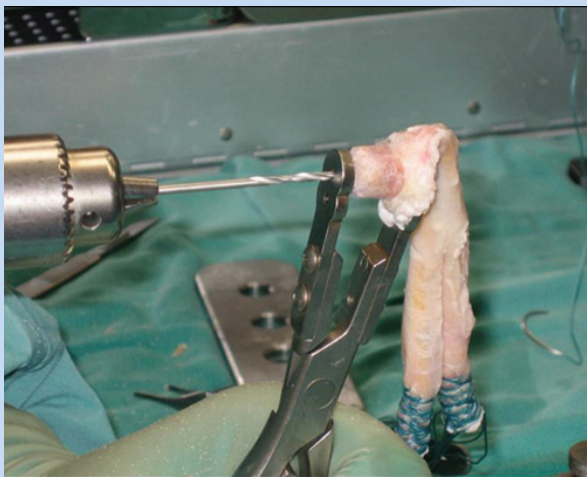


Figure 7. Creation of the central hole in the calcaneal bone plug is performed with the use of a 3.5-mm cannulated drill system as shown here.

to guide the bone plug into position and tied over a post to provide addition fixation. An additional No. 2 suture is used to further secure the bone plug.

Femoral Tunnel

The femoral tunnels are created with an outside-in technique (Figure 9). This method was recommended by Handy et al¹³ as a way to decrease the angulation of the femoral tunnel at the so-called critical corner, which may decrease strain in the PCL graft. Additional advantages of this technique include the ability to differentially tension the bifid limbs of the graft once the tibial plug is seated and fixed; it also provides the option to

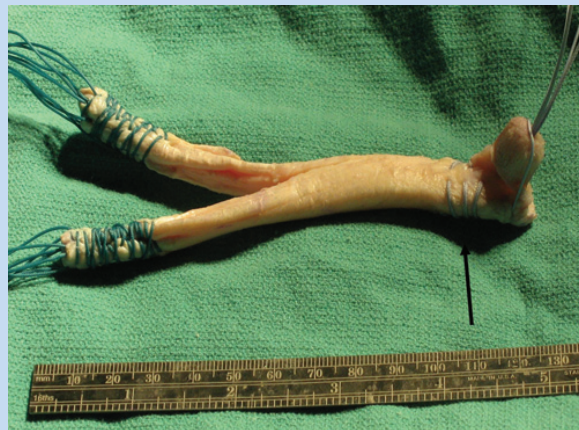

Figure 8. A strong No. 2 braided nonabsorbable suture is passed through the remaining 1 cm of tendon near the bone plug (arrow) and then passed through the center hole to assist in fixation and guide the bone plug into the tibial socket.

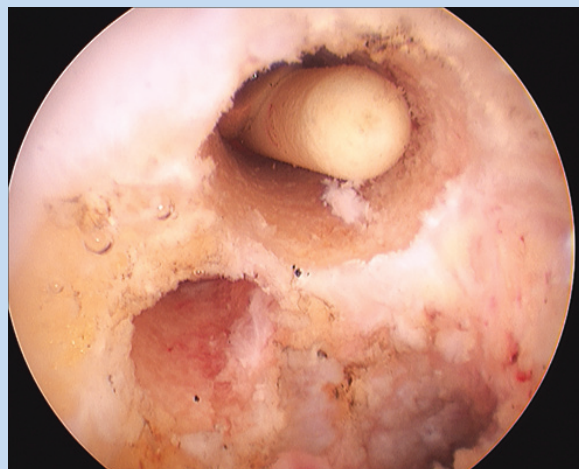


Figure 9. Anterolateral and posteromedial femoral tunnels have been created via an outside-in technique.

augment the metal or bioabsorbable soft tissue screw fixation in the femoral tunnels with a number of additional fixation techniques. These include tying the suture ends around a post, over the medial condylar bone bridge, or over a plastic button. This rigid femoral fixation is another advantage of this procedure that allows for an earlier range-of-motion protocol and an accelerated rehabilitation postoperatively. The remainings from the bone tunnels can be used to fill the patellar donor site.

To create the femoral tunnels, an incision is made anteromedially over the vastus medialis obliquus at the level of the medial epicondyle extending in line and anterior to the intermuscular septum. A Cobb elevator is used to sweep

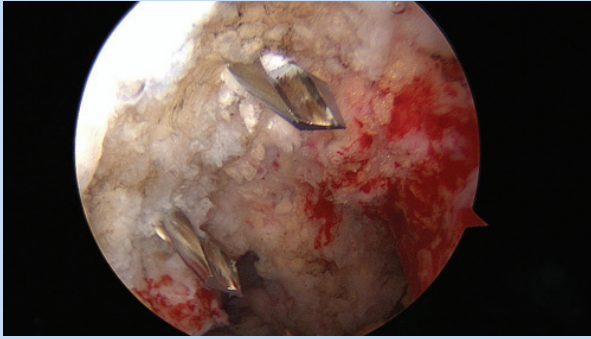


Figure 10. Note the anatomic position of the femoral tunnels as evidenced by the guide pins entering the respective anterolateral and posteromedial bundle footprints.

the vastus medialis obliquus off the floor of the intermuscular septum, and an S-shaped retractor is positioned over the anterior femur. Anatomic placement of the femoral tunnels is desired (Figure 10). Ideally, the anterior edge of the anterolateral tunnel is 1 to 2 mm off the articular margin of the medial femoral condyle at the 11:30 (left) or 12:30 (right) clock position. To create the tunnel, the guide pin should be placed roughly 5 mm posterior to the articular margin to accommodate the 9-mm tunnel for the anterolateral bundle (Figure 10). For the posteromedial tunnel, the guide pin should be placed roughly 7 mm off the articular margin at the 9-o'clock (left) or 3-o'clock (right) position to accommodate a 7-mm tunnel. The edge of the drilled tunnel should lie 3 mm from the articular margin (Video 3). Failure to maintain adequate spacing between the 2 tunnels on the medial femoral cortex may result in convergence of the tunnels and loss of the potential benefits of a double-bundle reconstruction.

Graft Passage / Tibial Fixation

To facilitate graft passage, the AM portal is routinely extended to a 2-cm arthrotomy through the capsule and fat pad. It is very important that the passing sutures traverse cleanly through the arthrotomy and fat pad, or the graft may become incarcerated in the fat pad. A hemostat and arthroscopic probe may be used to guide the graft into the tibial socket. The bone plug seating into the tibial socket is confirmed with fluoroscopy (Video 4). The tibial side is then fixed, and the femoral limbs are retrieved into the respective tunnels with a looped 18-gauge wire. Press fitting the bone plug into the tibial socket provides unique stability to this construct.^{4,5,23} The press fit is further augmented by the guiding No. 2 sutures over a post or onto a plastic button.^{4,5} Based on biomechanical studies of fixation strength, coupled with the suspected decreased strain that the graft is not at the posterior tibia (“killer turn”) or femoral tunnels (critical corner), patients may participate in an early protected range-of-motion protocol. This may be beneficial in regaining knee range of motion at an earlier stage of the postoperative spectrum and may allow for faster return

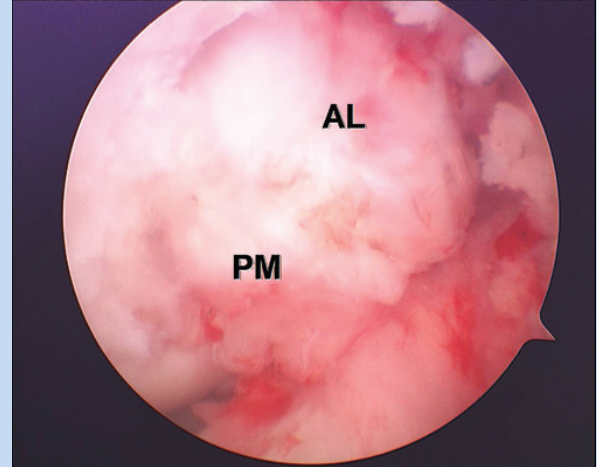


Figure 11. Appearance of the final graft in place. Note the 2 discrete bundles: anterolateral (AL) and posteromedial (PM).

of the dynamic secondary stabilizers of the knee, such as the quadriceps and hamstrings. This faster return of motion and secondary stabilization may allow for a more accelerated return to activities and may be protective of the graft to some degree, with the return of muscle groups that can potentially work in parallel to limit translation of the knee joint.

Femoral Fixation

Once the tibial plug is secured in the socket and the femoral limbs have been passed into their respective tunnels, attention is turned to femoral fixation. Before fixing the limbs in the femoral tunnels, the graft is cycled in an effort to eliminate potential laxity in the construct. In multiligament injured knees, the collaterals are fixed first, followed by the PCL and, finally, the anterior cruciate ligament. Both limbs are tensioned at 90° because recent data have suggested that the posteromedial bundle is important for stability in higher degrees of knee flexion.¹ Although both limbs are tensioned at the same degree of flexion in this technique, their unique attachments and distinctive orientations allow for differential function of the bundles throughout the knee range of motion.¹ The sequence for femoral fixation is the anterolateral bundle first, then the posteromedial bundle in a similar fashion. The leading sutures are then tied to each other over the medial cortical bone bridge or around a post to further enhance the femoral fixation (Figure 11, Video 5).

Rehabilitation Protocol

Little data exist on the rehabilitation of the PCL-reconstructed knee. This protocol differs from many¹⁰ because it allows for immediate range of motion of the reconstructed knee in a controlled setting. Immediate partial weightbearing in full extension is allowed in a brace. Partial weightbearing in full extension allows the tibia to reduce on the femur secondary

to the conformity of the articular surfaces, allowing the PCL to rest in a position that minimizes strain on the graft and in turn decreases graft elongation and leads to a more stable construct (Chris Harner, MD, personal communication).

DISCUSSION

An early and aggressive rehabilitation program following PCL reconstruction has been viewed as being undesirable and detrimental to the postoperative stability; in fact, some studies have shown grade II or higher residual laxity in the PCL-reconstructed knee in up to 40% of patients, which may be in part due to rehabilitation technique.¹³ Fanelli¹⁰ stated, "An accelerated PCL postoperative rehabilitation is entirely undesirable in a level V treatise on PCL rehabilitation. Rather, the use of a slow and deliberate postoperative rehabilitation program is vital to a successful outcome after PCL reconstructive surgery." These recommendations are based on experience primarily with the transtibial technique. Some authors have suggested that this type of reconstruction is susceptible to increased strain at the killer turn around the posterior tibia,^{2,17} potentially leading to graft thinning and subsequently to increased laxity. The graft may also see increased strain at the femoral tunnel sites at the critical corners. Handy et al¹³ showed that with an inside-out technique, the graft tunnel angle on the femoral side can exceed that at the killer turn at the posterior aspect of the tibia. The authors suggested that the graft sees increased strain at the killer turn and could be compromised at the critical corners based on the high graft tunnel angles observed in their study.¹³ Based on this theory, some have proposed that the number of knee rehab cycles should be limited to avoid graft abrasion at either the posterior tibia or the femoral tunnel insertions until preliminary soft tissue healing has occurred. The inlay technique may limit this confounder by minimizing potential areas of stress on the tibial side by the anatomic tibial attachment and press-fit plug. Overall, the rehabilitation protocol progression is based on an 8-week bone-to-bone healing time course for the tibial plug, with continued healing of the soft tissue limbs and remodeling of the tibial insertion occurring for months postoperatively.

Rehabilitation is vital to the successful outcome of any knee ligament reconstruction, and PCL reconstruction is no exception. Developing a rehabilitation program based on the science of healing and laboratory biomechanics is the logical way to proceed. This rehabilitation protocol is shaped by the type of reconstruction performed. This reconstruction has been extensively tested in biomechanical laboratory studies with favorable results.^{4,5,19,23}

An additional key point to a successful rehabilitation program in the PCL-reconstructed knee is to maintain the reduction of the tibia on the femur and to limit the posterior translation that may occur and produce strain on the newly created graft.⁶ Unlike some of the leading rehabilitation protocols in

the literature,¹⁰ immediate partial weightbearing is allowed. In some protocols, this is reserved until postoperative week 7.¹⁰ Weightbearing allows for reduction of the PCL, and it minimizes the force that the graft experiences while in its critical healing stages.²⁰ In addition, addressing all injured structures, including collateral ligaments, is essential to optimize final stability.

CONCLUSION

There are unique features of this reconstruction that could allow for alterations in the previously proposed rehabilitation protocols for PCL reconstruction. The stability afforded by the anatomic press-fit tibial plug and the fact that tibial and femoral fixation is augmented may allow a slightly more aggressive rehabilitation program. The anatomic position of the tibial insertion of the PCL with this reconstruction avoids the killer turn that can be seen with the transtibial approach, which may minimize concerns for abrasion of the graft and resultant elongation. The decreased graft tunnel angles on the femoral side created with an outside-in drilling technique could also allow the graft to see lower forces and decrease the risk of elongation. Further clinical follow-up from patients having undergone this type of reconstruction are necessary and underway to determine whether the advantages do indeed afford the opportunity to utilize a more aggressive postoperative rehabilitation program.

REFERENCES

- Ahmad CS, Cohen ZA, Levine WN, et al. Codominance of the individual posterior cruciate ligament bundles: an analysis of bundle lengths and orientation. *Am J Sports Med.* 2003;31(2):221-225.
- Bergfeld JA, Graham SM, Parker RD, et al. A biomechanical comparison of posterior cruciate ligament reconstructions using single- and double-bundle tibial inlay techniques. *Am J Sports Med.* 2005;33(7):976-981.
- Boynton MD, Tietjens BR. Long-term followup of the untreated isolated posterior cruciate ligament-deficient knee. *Am J Sports Med.* 1996;24(3):306-310.
- Campbell RB, Jordan SS, Sekiya JK. Arthroscopic tibial inlay for posterior cruciate ligament reconstruction. *Arthroscopy.* 2007;23(12):1356, e1351-e1354.
- Campbell RB, Torrie A, Hecker A, et al. Comparison of tibial graft fixation between simulated arthroscopic and open inlay techniques for posterior cruciate ligament reconstruction. *Am J Sports Med.* 2007;35(10):1731-1738.
- Chu BI, Martin RL, Carcia CR, et al. Surgical techniques and postoperative rehabilitation for isolated posterior cruciate ligament injuries. *Orthop Phys Ther Practice.* 2007;19(4):185-189.
- Clancy WG Jr, Shelbourne KD, Zoellner GB, et al. Treatment of knee joint instability secondary to rupture of the posterior cruciate ligament: report of a new procedure. *J Bone Joint Surg Am.* 1983;65(3):310-322.
- Cooper DE, Stewart D. Posterior cruciate ligament reconstruction using single-bundle patella tendon graft with tibial inlay fixation: 2- to 10-year follow-up. *Am J Sports Med.* 2004;32(2):346-360.
- Dejour H, Walch G, Peyrot J, et al. [The natural history of rupture of the posterior cruciate ligament]. *Rev Chir Orthop Reparatrice Appar Mot.* 1988;74(1):35-43.
- Fanelli GC. Posterior cruciate ligament rehabilitation: how slow should we go? *Arthroscopy.* 2008;24(2):234-235.
- Fanelli GC, Giannotti BF, Edson CJ. The posterior cruciate ligament arthroscopic evaluation and treatment. *Arthroscopy.* 1994;10(6):673-688.
- Garavaglia G, Lubbeke A, Dubois-Ferriere V, et al. Accuracy of stress radiography techniques in grading isolated and combined posterior knee injuries: a cadaveric study. *Am J Sports Med.* 2007;35(12):2051-2056.

13. Handy MH, Blessey PB, Kline AJ, et al. The graft/tunnel angles in posterior cruciate ligament reconstruction: a cadaveric comparison of two techniques for femoral tunnel placement. *Arthroscopy*. 2005;21(6):711-714.
14. Johnson DH, Fanelli GC, Miller MD. PCL 2002: indications, double-bundle versus inlay technique and revision surgery. *Arthroscopy*. 2002;18(9)(suppl 2):40-52.
15. Keller PM, Shelbourne KD, McCarroll JR, et al. Nonoperatively treated isolated posterior cruciate ligament injuries. *Am J Sports Med*. 1993;21(1):132-136.
16. Kohen R, Sekiya JK. Single versus double bundle PCL reconstruction: a systematic review. *Arthroscopy*. In press.
17. Markolf KL, Feeley BT, Jackson SR, et al. Biomechanical studies of double-bundle posterior cruciate ligament reconstructions. *J Bone Joint Surg Am*. 2006;88(8):1788-1794.
18. Ruberte R AA, Campbell RB, Sekiya JK. Biomechanical comparison of figure-of-eight versus cylindrical tibial inlay constructs for arthroscopic posterior cruciate ligament reconstruction. *Arthroscopy*. In press.
19. Sekiya JK, Kurtz CA, Carr DR. Transtibial and tibial inlay double-bundle posterior cruciate ligament reconstruction: Surgical technique using a bifid bone-patellar tendon-bone allograft. *Arthroscopy*. 2004;20(10):1095-1100.
20. Sekiya JK, West RV, Ong BC, et al. Clinical outcomes after isolated arthroscopic single-bundle posterior cruciate ligament reconstruction. *Arthroscopy*. 2005;21(9):1042-1050.
21. Sekiya JK, Whiddon DR, Zehms CT, et al. A clinically relevant assessment of posterior cruciate ligament and posterolateral corner injuries: evaluation of isolated and combined deficiency. *J Bone Joint Surg Am*. 2008;90(8):1621-1627.
22. Tibor LM, Marchant MH Jr., Taylor DC, et al. Management of medialsided knee injuries Part II: posteromedial corner. *Am J Sports Med*. In Press.
23. Zehms CT, Whiddon DR, Miller MD, et al. Comparison of a double bundle arthroscopic inlay and open inlay posterior cruciate ligament reconstruction using clinically relevant tools: a cadaveric study. *Arthroscopy*. 2008;24(4):472-480.

For reprints and permissions queries, please visit SAGE's Web site at <http://www.sagepub.com/journalsPermissions.nav>.