




Chinese Taipei Society of
Ultrasound in Medicine

Available online at www.sciencedirect.com

ScienceDirect

journal homepage: www.jmu-online.com



LETTER TO THE EDITOR

Large Subchorionic Hematoma: Breus' Mole



Ahmed Samy El-agwany*

Department of Obstetrics and Gynecology, Faculty of Medicine, Alexandria University, Egypt

Received 23 February 2017; accepted 22 June 2017

Available online 27 November 2017

KEYWORDS

Subchorionic
hematoma,
Intrauterine growth
retardation,
Twin,
Ultrasound

Abstract A case of large subchorionic hematoma complicated by intrauterine growth retardation and oligohydramnios diagnosed at 32 weeks' gestation with twin pregnancy after ICSI is reported below. The patient was on clexane injection during pregnancy for mitral valve replacement. She was managed with tocolysis using progesterone therapy and antibiotic with followup until delivery. At 34 weeks, a male baby weighing was delivered without complication by caesarean section because of single fetal demise of twin pregnancy.

© 2017, Elsevier Taiwan LLC and the Chinese Taipei Society of Ultrasound in Medicine. This is an open access article under the CC BY-NC-ND license (<http://creativecommons.org/licenses/by-nc-nd/4.0/>).

Introduction

Large subchorionic hematoma, which was first described by Breus [1] in 1892 (Breus' mole), is a serious condition that is frequently complicated by intrauterine growth retardation (IUGR) and intrauterine fetal death (IUFD). We encountered a case complicated by IUGR and oligohydramnios diagnosed at 32 weeks' gestation in twin pregnancy after ICSI on anticoagulant.

Case report

A 30 year-old, G2P0+1, history of previous one hysterotomy, was admitted to our hospital for ANC. There was no complaints. She was about 28 weeks of gestation with twin

pregnancy after ICSI. She was hypothyroid on L-Thyroxine and with mitral valve replacement on clexane injection of 80 mg every 12 h and PGDM on insulin. Ultrasonographic examination revealed twin dichorionic diamniotic pregnancy with IUGR of first baby with oligohydramnios. A large homogenous mass about 14 cm in dimensions was detected beside the fetal placenta of the IUGR fetus (Fig. 1). No blood flow was detected in the mass on color Doppler. The patient was admitted for tocolysis with progesterone and follow-up until delivery with antibiotic. The patient was managed conservatively for 4 weeks, where IUGR fetus died. A male baby was delivered without complication by caesarean section after steroid therapy for lung maturation at 32 weeks. During removal of the placenta, large amount of dark brown blood with no clots was noted.

This hematoma might be related to minor trauma with high dose of anticoagulant therapy.

Discussion

It is a rare disease, with an incidence of 1 in 1200 placentas. Women with cardiac problems, disorders of circulation,

Conflict of interest: The authors declare no conflict of interest.

* Correspondence to: Ahmed Samy El-agwany, Shatby Maternity University Hospital, Faculty of Medicine, Alexandria University, Alexandria, Egypt.

E-mail addresses: Ahmedsamyagwany@gmail.com,
ahmed.elagwany@alexmed.edu.eg.

<https://doi.org/10.1016/j.jmu.2017.09.006>

0929-6441/© 2017, Elsevier Taiwan LLC and the Chinese Taipei Society of Ultrasound in Medicine. This is an open access article under the CC BY-NC-ND license (<http://creativecommons.org/licenses/by-nc-nd/4.0/>).

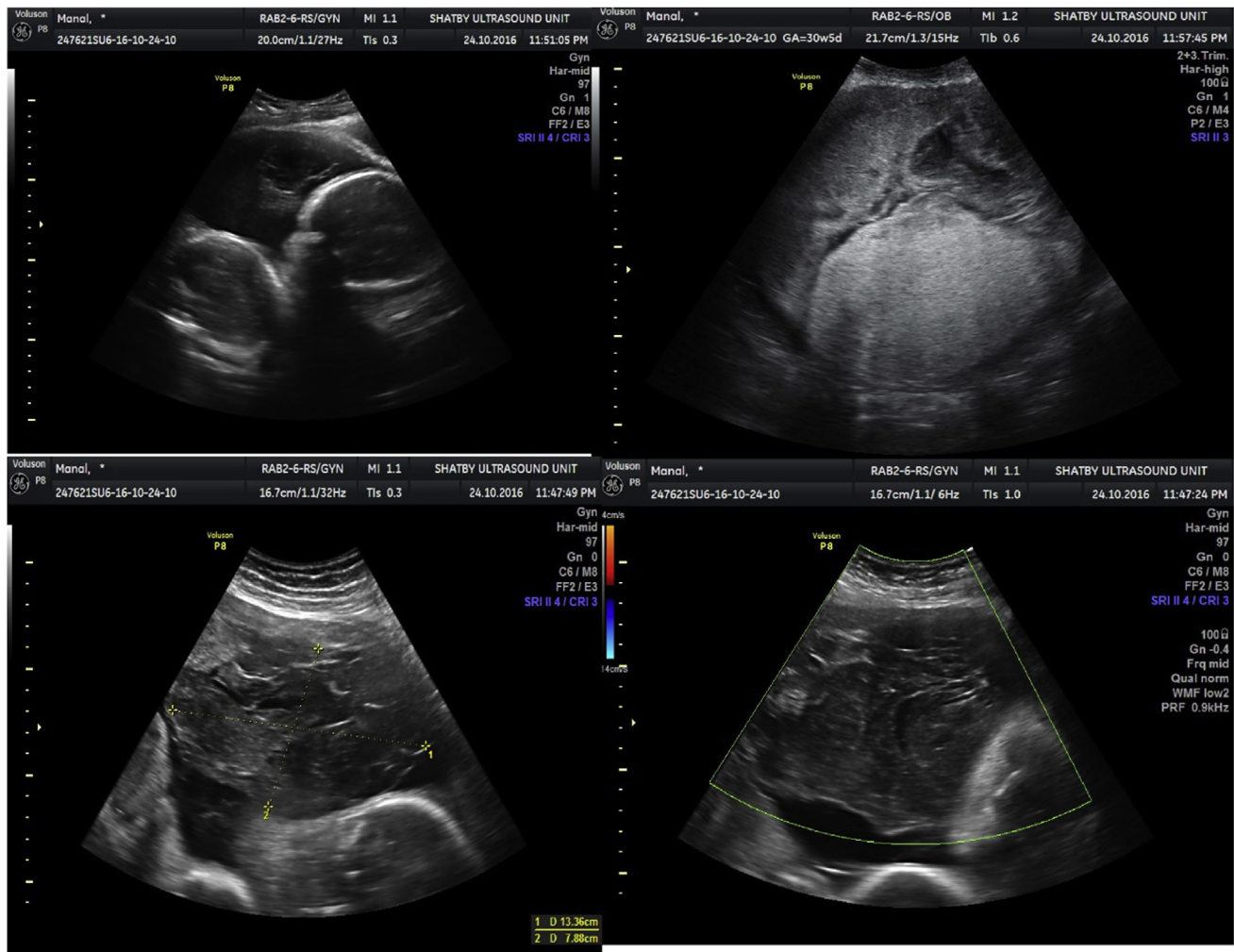


Figure 1 Ultrasound showing twin pregnancy with dichorionic placenta and subchorionic hematoma that was avascular.

monosomy, hypertension and diabetes are predisposed to Breus' mole. The mole is formed as a sub-chorionic hematoma, formed out of the intervillous blood, causing progressive accumulation of the clotting substance called fibrin with increasing gestational age [2].

Breus mole is reported to be found in the placetae of macerated stillborn foetuses, indicating that massive subchorionic hematoma could have been the cause of their demise. A massive Breus' mole can cause disturbances in blood flow in the spiral arteries and might result in intrauterine growth restriction of the foetus [3].

Although the reported frequency of subchorionic hematoma is very low, some cases of IUGR associated have been investigated [4–6]. The mechanism of IUGR is due to utero-placental insufficiency. The location of hematoma has been suggested to impede the cord insertion [5,7]. The hematoma can easily compress the umbilical vessels. Tocolysis and antibiotic therapy are common for the management because likely to result in abortion or premature delivery associated with chorioamnionitis [8]. In 1991, Baxi and Pearlstone [9] suggested that antibodies are an etiologic factor for subchorionic hematoma. The antibodies have been suggested to increase the platelets to aggregate, which leads to thrombosis and vasculitis. It is a condition in which a large amount

of blood mainly of maternal origin collects and separates the chorionic plate from the villous chorion [6].

Its etiology and pathogenesis remained a dilemma in the 18th and early 19th century. The term Breus' "Mole" does not actually mean molar degeneration as seen in hydatiform moles, but is related to "mass" or coagulated blood. Their significance depends not on their size, but on their site of appearance. For eg: if near cord insertion they may lead to cord compression and decreased fetal perfusion, fetoplacental insufficiency or hematoma dissected into base of the umbilical cord causing umbilical venous obstruction.

Author's contribution

All the authors contributed to protocol development, data collection and management, Data analysis and Manuscript writing/editing.

Ethical disclosure

The authors declare that the procedures followed were in accordance with the regulations of the relevant clinical

research ethics committee and with those of the Code of Ethics of the World Medical Association (Declaration of Helsinki).

Confidentiality of data

The authors declare that they have followed the protocols of their work center on the publication of patient data.

Right to privacy and informed consent

The authors have obtained the written informed consent of the patients or subjects mentioned in the article. The corresponding author is in possession of this document.

References

- [1] Breus C. *Das Tuberosa Subchoriale Haematom der Decidua*. Leipzig: Deuticke; 1892.
- [2] Shimizu I, Shikado K, Mituda N, et al. Ultrasonographic findings in massive subchorionic hematoma (Breus' mole). *Ultrasound Obstet Gynecol* 1995;6(suppl):163.
- [3] Suzuki S, Mine K, Sawa R, et al. 10% maltose infusion therapy for oligohydramnios. *Aust NZ J Obstet Gynecol* 1999;39:373–5.
- [4] Thomas D, Makhoul JM, Iler C. Fetal growth retardation due to massive subchorionic thrombohematoma: report of two cases. *J Ultrasound Med* 1992;11:245–7.
- [5] Tam W, Fung HY, Fung T, et al. Intra-uterine growth retardation and transverse lie due to massive subchorionic thrombohematoma and overlying large subchorionic cyst. *Acta Obstet Gynecol Scand* 1997;76:381–3.
- [6] Richards DS, Bennett B. Prenatal ultrasound diagnosis of massive subchorionic thrombohematoma. *Ultrasound Obstet Gynecol* 1998;11:364–6.
- [7] Kirkinen P, Jouppila P. Intrauterine membranous cyst: a report of antenatal diagnosis and obstetric aspects in two cases. *Obstet Gynecol* 1986;67:26S–30S.
- [8] Seki H, Kuromaki K, Takeda S, et al. Persistent subchorionic hematoma with clinical symptoms until delivery. *Int J Gynaecol Obstet* 1998;63:123–8.
- [9] Baxi LV, Pearlstone MM. Subchorionic hematomas and the presence of autoantibodies. *Am J Obstet Gynecol* 1991;165:1423–4.