



Case report

Oculocardiac reflex elicited by orbital floor fracture and inferior globe displacement



Chau M. Pham*, Steven M. Couch

Department of Ophthalmology and Visual Sciences, Washington University in St Louis, St Louis, MO, United States

ARTICLE INFO

Article history:

Received 11 October 2016

Received in revised form

26 December 2016

Available online 3 February 2017

Keywords:

Oculocardiac reflex
Orbital floor fracture
Blow out fracture

ABSTRACT

Purpose: To review the physiology, presentation and management of the oculocardiac reflex (OCR) by describing a case of the OCR associated with an orbital foreign body and complete ocular prolapse through a large orbital floor fracture in a 40-year-old male following a motor vehicle accident.

Observations: The patient demonstrated marked bradycardia and hypotension necessitating intubation and medical therapy for autonomic shock. A computed tomography (CT) showed a total blow out floor fracture and complete dislocation of a radiographically intact globe with uninterrupted rectus muscle attachments into the left maxillary sinus. He was taken to the operating room for urgent repair resulting in subsequent termination of severe OCR.

Conclusions and importance: The oculocardiac reflex can precipitate marked bradycardia and hypotension in the setting of trauma with significant orbital and maxillofacial injury. Prompt identification and management with vagolytic agents or definitive surgical intervention may prevent morbidity or mortality.

© 2017 The Authors. Published by Elsevier Inc. This is an open access article under the CC BY-NC-ND license (<http://creativecommons.org/licenses/by-nc-nd/4.0/>).

1. Introduction

Independently described by both G Dagnini (Bologna) and B Aschner (Vienna) in 1908, the oculocardiac reflex (OCR) is frequently reported during strabismus surgeries (incidence 16–95%) where traction on extra-ocular muscles elicits a vagal response via a reflex arc involving the trigeminal nerve, brainstem, and vagus nerve.^{1,2} Well-known in the pediatric ophthalmology and anesthesiology literature, this reflex has also been reported in a variety of adult surgeries including maxillofacial surgeries involving the maxillary and mandibular distributions of the trigeminal nerve, skull base surgeries, and even surgery involving an empty orbit.^{3–5} The OCR has also been described in the setting of trauma, most commonly associated with trapdoor fractures involving entrapment of an extraocular muscle.^{6,7} Here we describe a case of the OCR resulting in autonomic instability elicited by total globe dislocation through a large orbital floor fracture.

1.1. Case presentation

A 40-year-old man with no significant prior medical history sustained a near complete orbital floor fracture with embedding of a large foreign body in the left superior orbit after a high speed motor vehicle accident. He was intubated and sedated shortly upon arrival to the emergency room for autonomic instability including episodes of bradycardia to the 20s, periods of asystole lasting up to 6 s, and hypotension requiring treatment with a norepinephrine infusion. It was also noted that gentle manipulation of the foreign body by physicians in the emergency room resulted in exacerbation of the bradycardia. A CT of the orbits revealed no intracranial abnormalities; however, was significant for a near complete fracture of the left orbital floor and inferior displacement of what appeared to be an intact globe into the left maxillary sinus (Fig. 1). Coronal CT (Fig. 1) revealed extraocular muscles and optic nerve with radiographic evidence of intact attachments to both the globe and their origins. On clinical exam the left globe was not visualized and assessment of visual acuity and pupillary reaction were not able to be completed due to the large foreign body and almost total inferior displacement of the globe in to the maxillary sinus. The patient was taken to the operating room on an urgent basis for removal of orbital foreign body and repair of left orbital floor fracture. A 4 cm by 7 cm plastic foreign body was found to be firmly lodged in the

* Corresponding author. 660 S. Euclid Ave, Box 8096, St. Louis, MO 63110, United States.

E-mail address: phamc@vision.wustl.edu (C.M. Pham).

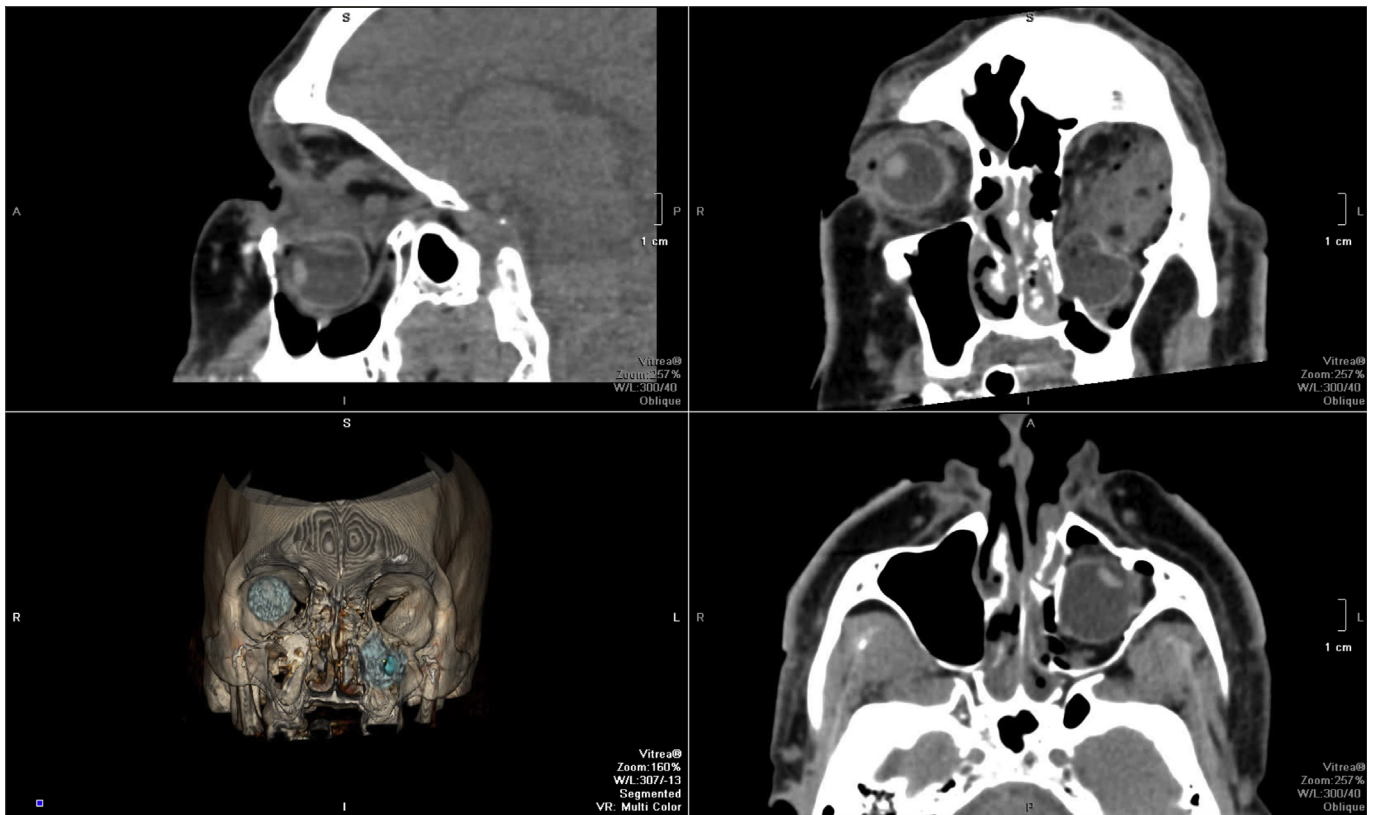


Fig. 1. Clockwise from top left. Sagittal, coronal, and axial views of non-contrast computed tomography (CT) and 3-dimensional (3D) reconstruction showing total displacement of the left globe in to the left maxillary sinus.

superonasal aspect of the left orbit and was extricated after bisection using heavy gauge Mayo scissors (Fig. 2). The orbit was carefully explored and all visible areas of the globe were found to be intact with no scleral lacerations; however, the majority was prolapsed into the left maxillary sinus. After globe extrication from the sinus, further exploration found the globe as well as all rectus muscle insertions to be fully intact. The optic nerve appeared attached without any external evidence of avulsion. The floor was

repaired with a 46 by 35 mm Medpor implant (Stryker, Kalamazoo, MI, USA) (Fig. 2). The patient remained hemodynamically stable for the duration of the surgery and was quickly weaned from the norepinephrine infusion post-operatively. At one week post-surgery, the patient had light perception vision and minimal extra-ocular movements. Unfortunately, the patient did not follow up beyond his inpatient stay, so further postoperative data is absent.

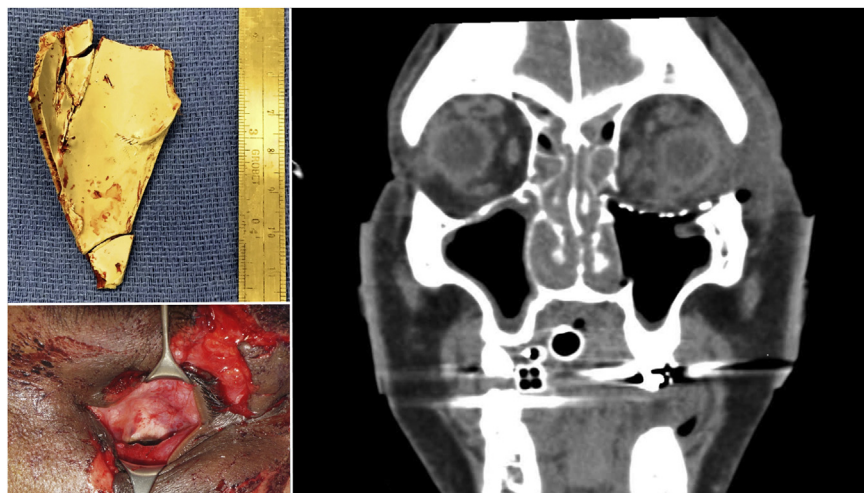


Fig. 2. Clockwise from top left. The foreign body was found to be approximately 4 cm × 7 cm in size. Post-operative coronal view of non-contrast computed tomography (CT). Intraoperative view of inferiorly displaced globe.

2. Discussion

The OCR is classically described as being elicited by traction on the extraocular muscles or pressure on the globe. Stimulation of stretch receptors begins the afferent limb of the arc via the ciliary ganglion and ophthalmic branch of the trigeminal nerve terminating in the sensory nucleus of the trigeminal nerve. The efferent limb is mediated by the motor nucleus of the Vagus nerve and its negative effects on heart rate and cardiac output.⁸ Increased risks for the OCR include age (increased vagal tone in younger patients), hypercarbia (Blanc et al. found high Pa CO₂ more than doubled the percentage of significant bradycardia however did not hypothesize on a mechanism for this finding), hypoxemia, light anesthesia, and potent narcotics (which may augment vagal tone by inhibiting the sympathetic nervous system).^{9–11} Alternatively, very deep anesthesia and retrobulbar block were found to decrease risk via blockage of the afferent limb (although the OCR conceivably could be triggered by orbital pressure in the latter case).¹² Blanc et al. found that the OCR is also affected by the strength, duration, and waveform of the stimulus; a rapid square pattern was more likely to elicit the reflex than a slow progressive stimulus.¹⁰ The reflex is also reported to be fatigable, and repeated muscle traction has been shown to abolish or produce a modified response.¹⁰ In rare cases, the OCR has been associated with death.¹³

In the present case, the diagnostic dilemma lay in the etiology of this patient's hypotension and bradycardia. In the setting of trauma the differential diagnosis for hypotension includes: hemorrhage, cardiac tamponade, pneumo- or hemothorax, cardiogenic or neurogenic shock, pharmacologic or toxicologic agents, and fat or air embolism. Meanwhile, factors that may cause bradycardia in this setting include hypothermia, prolonged hypoxemia, pressure on the carotid sinus, or pharmacologic agents. Our patient had sustained significant facial trauma, however initial radiographic imaging was negative for intracranial abnormalities, spinal fractures, long bone fractures, or significant intra-abdominal injuries. We hypothesize that pressure from the foreign body coupled with downward traction caused by negative pressure within the maxillary sinus on the displaced globe and intact rectus muscles elicited the OCR.

Current recommendations for the prophylaxis and management of the OCR include risk factor identification and modification, careful cardiopulmonary monitoring, prophylactic treatment with either vagolytic agents or peripheral nerve blocks, cessation of the inciting stimulus, treatment with vagolytic agents should the reflex occur, and treatment with sympathomimetic drugs should these interventions fail.¹⁴

In the present case, norepinephrine was used as a temporizing measure until traction on the extraocular muscles from downward displacement was definitively relieved by surgical removal of the foreign body, globe repositioning in the orbit, and repair of the floor fracture, with subsequent weaning of the patient off of the need for pharmacologic augmentation.

3. Conclusion

This case demonstrates that the OCR should be part of the differential diagnosis of bradycardia and hypotension in the setting of trauma involving significant orbital and maxillofacial injuries, and although it can rarely prove to be fatal, patients should receive

prompt evaluation and close cardiopulmonary monitoring. Management should include removal of the inciting stimulus if possible, and the judicious use of vagolytic agents.

Patient consent

Patient unavailable for permission. Photographs and figures have no identifying features.

Acknowledgements and disclosures

Funding

No funding or grant support.

Conflict of interest

The authors have no financial disclosures relating this topic.

Authorship

All authors attest that they meet the current ICMJE criteria for Authorship.

Acknowledgements

None.

References

- Dagnini G. Intorno ad un riflesso provocato in alcuni emiplegici collo stimolo della cornea e colla pressione sul bulbo oculare. *Boll Sci Med.* 1908;8:380–381.
- Aschner B. Über einen bisher noch nicht beschriebenen reflex von auge auf krieslauf und atmung. Verschinden des Radialispulses bei Druck auf das Auge. *Wien Klin Wschr.* 1908;21:1529–1530.
- Lang S, Lanigan ET, Van der Wal M. Trigemino-cardiac reflexes: maxillary and mandibular variants of the oculocardiac reflex. *Can J Anaesth.* 1991;38:757–760.
- Koerbel A, Gharabaghi A, Samii A, et al. Trigemino-cardiac reflex during skull base surgery: mechanism and management. *Acta Neurochir (Wien).* 2005;147:727–732.
- Tsai JC, Heitz JW. Oculocardiac reflex elicited during debridement of an empty orbit. *J Clin Anesth.* 2012;24:426–427.
- Joseph JM, Rosenberg C, Zoumalan CI, Zoumalan RA, White WM, Lisman RD. Oculocardiac reflex associated with a large orbital floor fracture. *Ophthalm Plast Reconstr Surg.* 2009;25:496–498.
- Sires BS, Stanley Jr RB, Levine LM. Oculocardiac reflex caused by orbital floor trapdoor fracture: an indication for urgent repair. *Arch Ophthalmol.* 1998;116:955–956.
- Dewar KM. The oculocardiac reflex. *Proc R Soc Med.* 1976;69:373–374.
- Yi C, Jee D. Influence of the anaesthetic depth on the inhibition of the oculocardiac reflex during sevoflurane anesthesia for pediatric strabismus surgery. *Brit Journ Anes.* 2008;101:234–238.
- Blanc VF, Hardy JF, Milot J, Jacob JL. The oculocardiac reflex: a graphic and statistical analysis in infants and children. *Can Anaesth Soc J.* 1983;30:360–369.
- Chung CJ, Lee JM, Choi SR, Lee SC, Lee JH. Effect of remifentanyl on oculocardiac reflex in pediatric strabismus surgery. *Acta Anaesthesiol Scand.* 2008;52:1273–1277.
- Lübbbers HT, Zweifel S, Grätz KW, Kruse A. Classification of potential risk factors for trigemino-cardiac reflex in craniomaxillofacial surgery. *J Oral Maxillofac Surg.* 2010;68:1317–1321.
- Arndt GA, Stock MC. Death from the oculocardiac reflex. *Can J Anaesth.* 1994;41:161–165.
- Arasho B, Sandu N, Spiriev T, Prabhakar H, Schaller B. Management of the trigemino-cardiac reflex: facts and own experience. *Neurol India.* 2009;57:375–380.