

# Microvascular Decompression and Nervus Intermedius Sectioning for the Treatment of Geniculate Neuralgia

Tyler J. Kenning<sup>1</sup> Christine S. Kim<sup>2</sup> Alexander G. Bien<sup>2,3</sup>

<sup>1</sup>Department of Neurosurgery, Albany Medical Center, Albany, New York, United States

<sup>2</sup>Division of Otolaryngology, Albany Medical Center, Albany, New York, United States

<sup>3</sup>Albany Ear, Nose, and Throat Services, Albany, New York, United States

Address for correspondence Tyler J. Kenning, MD, FAANS, Division of Pituitary and Cranial Base Surgery, Department of Neurosurgery, Albany Medical Center, 47 New Scotland Avenue, MC-10, Albany, NY 12208, United States (e-mail: kennint@mail.amc.edu).

J Neurol Surg B 2019;80(suppl S3):S316–S317.

## Abstract

**Objectives** Demonstrate the surgical treatment of geniculate neuralgia via microvascular decompression and nervus intermedius sectioning.

**Designs** Single case-based operative video.

**Setting** Tertiary center with dedicated skull base team.

**Participants** The patient is a 62-year-old female with a history of deep right-sided otalgia consistent with geniculate neuralgia. She failed appropriate medical treatment. Her magnetic resonance imaging (MRI) showed an ectatic verteobasilar system as well as an anterior inferior cerebellar artery (AICA) loop causing compression of the VII/VIII nerve complex in the cerebellopontine angle.

**Main Outcome Measures** Resolution of right-sided otalgia.

**Results** The patient underwent retrosigmoid craniotomy with microvascular decompression of the VII/VIII nerve complex and nervus intermedius sectioning. Intraoperatively, the patient was noted to have an ectatic vertebral artery and AICA that were compressing the root entry zone of the VII/VIII nerve complex. Microvascular decompression was performed of both the vertebral artery and AICA with Teflon. The nervus intermedius was sharply sectioned. The patient's postoperative course was uneventful with no complications. She continues to have resolution of her right sided otalgia at 6 months postoperatively.

The link to the video can be found at: [https://youtu.be/uRb\\_QfrINSk](https://youtu.be/uRb_QfrINSk).

## Keywords

- ▶ geniculate neuralgia
- ▶ microvascular decompression
- ▶ nervus intermedius
- ▶ retrosigmoid craniotomy
- ▶ ear pain
- ▶ otalgia
- ▶ nerve sectioning

**Conflict of Interest**  
None.



[www.thieme.com/skullbasevideos](http://www.thieme.com/skullbasevideos)

[www.thieme.com/jnlsbvideos](http://www.thieme.com/jnlsbvideos)

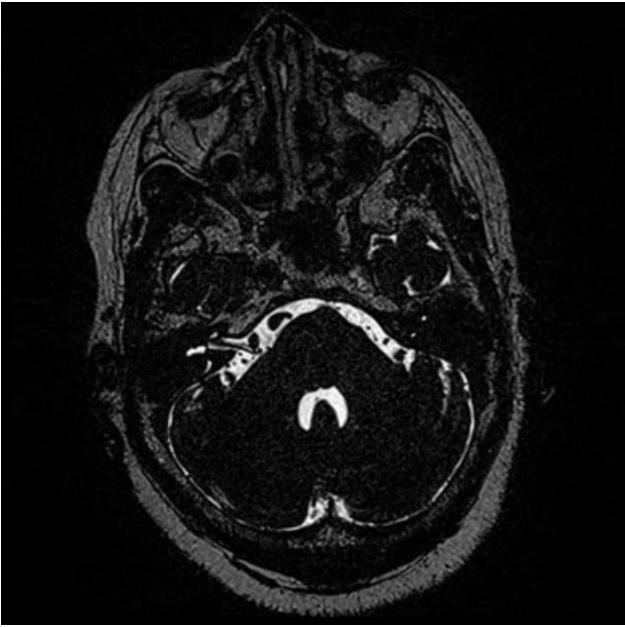
received  
May 30, 2018  
accepted  
August 19, 2018  
published online  
November 30, 2018

DOI <https://doi.org/10.1055/s-0038-1675151>.  
ISSN 2193-6331.

© 2019 Georg Thieme Verlag KG  
Stuttgart · New York

License terms





**Fig. 1** Preoperative axial T2 FIESTA MRI showing vascular compression of the right VII/VIII nerve complex by an ectatic vertebral artery and AICA. AICA, anterior inferior cerebellar artery; FIESTA, fast imaging employing steady-state acquisition; MRI, magnetic resonance imaging.