

Giant unusual shaped chronic subdural hematoma in a patient with untreated congenital hydrocephalus

Arvind Mishra, Bal. K. Ojha, Anil Chandra, Chhitij Srivastava, Sunil Kumar Singh

Department of Neurosurgery, Chhatrapati Sahuji Maharaj Medical University, Lucknow, Uttar Pradesh, India

ABSTRACT

Subdural hematoma is a well known complication of ventriculoperitoneal shunt insertion for hydrocephalus and usually spreads out over the cerebral convexity, and appears as a crescent shaped lesion on imaging. Chronic subdural hematoma in a case of untreated compensated congenital hydrocephalus has not been reported in English literature. We report the rare case of an adult with congenital hydrocephalus with a huge unusual shaped hemispheric subdural hematoma.

Key words: Chronic subdural hematoma, giant, hydrocephalus

Introduction

Subdural hematoma, one of the complications of shunt insertion, is usually caused by rapid excessive drainage of cerebrospinal fluid. The subdural hematoma generally appears as a crescent-shaped mass over the convexity adjacent to the inner table of the skull on computed tomography (CT) scans or adjacent to the dura matter on magnetic resonance images (MRI). We describe the rare case of an adult with untreated compensated congenital hydrocephalus with unusual shaped huge hemispheric subdural hematoma.

Case Report

We admitted an interesting case of compensated congenital hydrocephalus. Patient was a 39-year-old female with history of enlarged head size and delayed developmental milestones since birth, who presented with intermittent headache and vomiting for 1.5 months, right hemiparesis for five days, urinary incontinence, and drowsiness for one day. There was history of multiple episodes of minor head injury due to frequent

falls. There was no history of coagulation disorder, seizure, shunt surgery, or any drug intake. On examination, patient was conscious, oriented, but drowsy, head circumference was 74 cm, pupils were bilateral normal size and reactive, bilateral papilledema was present and right side hemiparesis (power: MRC grade 1 in upper limb and 3 in lower limb) was present. Hemoglobin was 12 gm% and other routine blood investigations including coagulation profile were normal.

CT scan was showing huge left hemispheric chronic subdural hematoma with unusual shape occupying whole left cerebral hemisphere and compressing the falx with almost complete obliteration of left lateral ventricle with dilated right lateral ventricle [Figure 1]. MRI was showing huge subdural hematoma hyperintense on both T1 and T2 weighted image with additional evidence of multiple septations in subdural hematoma [Figure 2 and 3]. Patient was operated by double burr hole craniostomy. Large amount of thick motor oil colored subdural fluid was drained. Subdural space was irrigated with saline solution till the effluent became clear. Brain did not reach to surface completely at the end of procedure. Subgaleal close drainage system was put.

Postoperatively, patient became alert. The patient did not develop any problems in the early postoperative period and her subgaleal drain was removed on the second postoperative day. Right hemiparesis improved to power grade 4 in both upper and lower limbs. Postoperative CT scan showed almost complete evacuation of hematoma [Figure 4].

Discussion

Chronic subdural hematoma is one of the most frequent types of intracranial hemorrhage that is still associated with significant morbidity. Although minor previous head injury is

Access this article online	
Quick Response Code:	Website: www.asianjns.org
	DOI: 10.4103/1793-5482.92183

Address for correspondence:

Dr. Arvind Mishra, Department of Neurosurgery,
C. S. M. Medical University, Lucknow, Uttar Pradesh, India.
E-mail: arvindmishrams@yahoo.co.in

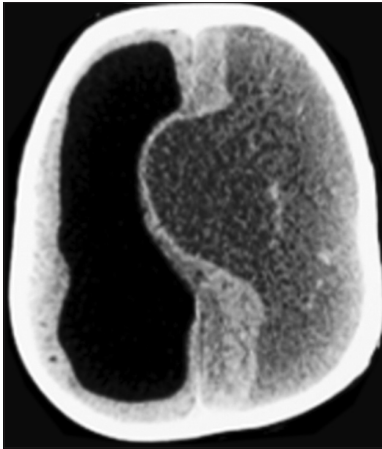


Figure 1: Preoperative CT scan showing giant hemispheric chronic SDH

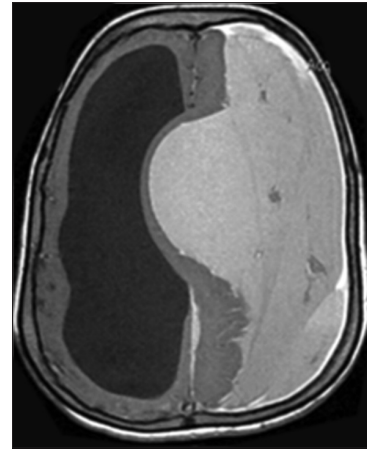


Figure 2: Preoperative T1 weighted MRI showing giant chronic subdural hematoma

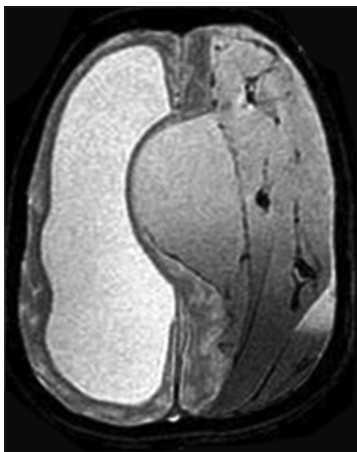

Figure 3: Preoperative T2 weighted MRI showing multiple septations in chronic subdural hematoma

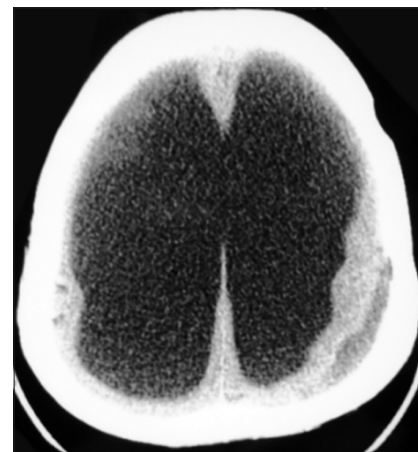


Figure 4: Postoperative CT scan showing complete evacuation of hematoma

sometimes unrecognized, a mild traumatic event has preceded the hemorrhage in 60 to 80% of reported cases.^[1]

Very few cases of chronic subdural hematoma occupying almost entire hemisphere have been reported. Although the cause of chronic subdural hematoma varies, it usually spreads out over the cerebral convexity and generally appears as a crescent-shaped lesion on neuroradiological images.^[1,2]

Unlike epidural hematomas, subdural hematomas are not restricted by dural tethering at the cranial sutures; they can cross suture lines and continue along the falx and tentorium. However, they do not cross the midline because of the meningeal reflections,^[3] but in our case, contralateral extension of chronic subdural hematoma was another unique finding. When hemorrhages of differing ages exist within a subdural collection, septae may separate the different blood products as happened in our case.

The cause of chronic subdural hematoma in our patient is probably repeated head trauma, but the exact mechanism for this unusual shaped hematoma in our patient is unclear. Chronic subdural hematoma is probably caused by tearing of the

bridging veins or bleeding from an enlarged vein in the subdural zone. Due to long standing compensated hydrocephalus with a large head and little brain parenchyma, our patient tolerated this huge chronic subdural hematoma for long duration before it became symptomatic. Decrease of elastence of brain due to chronic compensated congenital hydrocephalus may have allowed hematoma to grow unexpectedly.

References

1. Shimizu S, Ozawa T, Irikura K, Sagiuchi T, Kan S, Fujii K. Huge chronic subdural hematoma mimicking cerebral infarction on computed tomography: Case report. *Neurol Med Chir (Tokyo)* 2002;42:380-2.
2. He XS, Zhang X. Giant calcified chronic subdural hematoma: A long term tomography complication of shunted hydrocephalus. *J Neurol Neurosurg Psychiatry* 2005;76:367.
3. Murata T, Shigeta H, Horiuchi T, Sakai K, Hongo K. Globular subdural hematoma in a shunt-treated infant: Case report. *Neurosurg Pediatr* 2010;5:210-2.

How to cite this article: Mishra A, Ojha BK, Chandra A, Srivastava C, Singh SK. Giant unusual shaped chronic subdural hematoma in a patient with untreated congenital hydrocephalus. *Asian J Neurosurg* 2011;6:121-2.

Source of Support: Nil, **Conflict of Interest:** None declared.