

# Feasibility of radiofrequency catheter ablation in a patient with deep brain stimulators



Mordechai Grabie, MD,\* James Gabriels, MD,\* Kun Xiang, MD, PhD,<sup>†</sup>  
Claude S. Elayi, MD,<sup>†</sup> John N. Makaryus, MD,\*<sup>‡</sup> John N. Catanzaro, MD, FHRS<sup>†</sup>

From the \*Department of Cardiology, North Shore University Hospital, Northwell Health, Manhasset, New York, <sup>†</sup>Department of Electrophysiology, University of Florida, Jacksonville, Florida, and <sup>‡</sup>The Feinstein Institute for Medical Research, Northwell Health, Manhasset, New York.

## Introduction

Deep brain stimulation has been used as a treatment modality for conditions such as Parkinson disease, essential tremor, psychiatric illnesses, and chronic pain, with excellent results.<sup>1–8</sup> Deep brain stimulators (DBS) function by focused neurostimulation of the brain through electrodes that carry impulses from a neurostimulator that is typically implanted below the clavicle. Technical issues with these electromechanical devices arise when patients require imaging or treatment modalities that use electrical or magnetic currents.

There have been 2 reported prior ablations performed in patients with DBS, 1 using radiofrequency energy<sup>9</sup> and the other involving cryoablation.<sup>10</sup> We report another successful radiofrequency ablation (RFA) of supraventricular tachycardia in a patient with bilateral DBS for essential tremor without interference from the DBS or complications owing to delivery of radiofrequency energy.

## Case report

A 76-year-old woman with an essential tremor had received bilateral Activa SC Deep Brain Stimulators (Medtronic Inc, Minneapolis, MN) (Figure 1A) 2 years prior to presenting to the Emergency Department with recurrent palpitations. An event monitor, which she had been wearing as an outpatient for the same symptoms, revealed a regular narrow complex tachycardia at 180 beats per minute. A decision was made to proceed with an electrophysiology study and possible ablation.

On the day of her procedure her DBS was interrogated prior to the procedure and was deemed to be functioning properly. The baseline lead impedances were measured with a stimulation amplitude of 0.7 V. No changes were

made to the DBS programming prior to the ablation. During the electrophysiology study, tachycardia was induced with bipolar atrial burst pacing from a diagnostic catheter and was confirmed to be atrioventricular nodal reentrant tachycardia (AVNRT) using both atrial burst pacing and atrial extrastimuli (Figure 1B). There were no artifacts from the DBS noted on the intracardiac tracings (Figure 1B–D). An electroanatomic map was created using the EnSite Precision (Abbott, Abbott Park, IL) mapping system, which eliminated the need for fluoroscopy. There was no difficulty with placing the surface patches, mapping, or respiratory gating owing to inference from the DBS. The ground patch for the ablation was kept in the standard position on the patient's back. Her slow pathway was identified and modified with a 4 mm Blazer II standard curve RFA catheter (Boston Scientific, Marlborough, MA) with temperature control mode (temperature: 55°C, power: 50 W) (Figure 1C, D). Following the ablation, her AVNRT was no longer inducible with standard stimulation protocols. The DBS was interrogated again at the end of the case. The device was functioning properly at 0.7 V without any significant changes in the impedance of the leads owing to the ablation.

## Discussion

Performing an RFA in patients with a DBS is not without risk, given previous reports of DBS malfunction related to interference by extraneous stimuli. Spiegel and colleagues<sup>11</sup> reported transient dystonia in a patient with Parkinsons disease with a DBS who underwent magnetic resonance imaging. Yamamoto and colleagues<sup>12</sup> also demonstrated the risk of performing a direct current cardioversion in a patient with a DBS. This patient suffered an inadvertent thalamotomy as a result of the electrical current from the cardioversion.<sup>12</sup> The risks of applying electrical energy in close proximity to a DBS are due to ohmic heating of the device's leads in which the metal of the leads act as a conductor of electric current to produce heat. This can potentially damage the leads through direct heating or by heating the surrounding tissues. In an ex vivo experiment using bovine myocardium, Nguyen and colleagues<sup>13</sup> demonstrated that using RFA in

**KEYWORDS** Deep brain stimulation; Electrical interference; Ohmic heating; Procedural safety; Radiofrequency ablation (Heart Rhythm Case Reports 2020;6:253–255)

**Address reprint requests and correspondence:** Dr Mordechai Grabie, Department of Cardiology, North Shore University Hospital, Northwell Health, 300 Community Drive, Manhasset, NY 11030. E-mail address: MGrabie@northwell.edu.

## KEY TEACHING POINTS

- Radiofrequency ablations (RFA) can likely be safely performed in patients with deep brain stimulators (DBS).
- When performing RFA in a patient with a DBS, it is important to maximize the distance between the catheter and the DBS.
- Additional data are required to produce specific guidelines for RFA in patients with DBS.

close proximity to a copper wire, a defibrillator lead, and a circular mapping catheter results in increased heating of the surrounding tissue. Because of these risks, device manufacturers have issued warnings regarding performing magnetic resonance imaging or use of devices that produce electrical current such as cardiac pacemakers and defibrillators in patients with DBSs, although no specific recommendation has been made regarding radiofrequency ablations. The 2 prior reports of AVNRT ablations in patients with DBSs also did not find any negative effects on the DBS systems.<sup>9,10</sup>

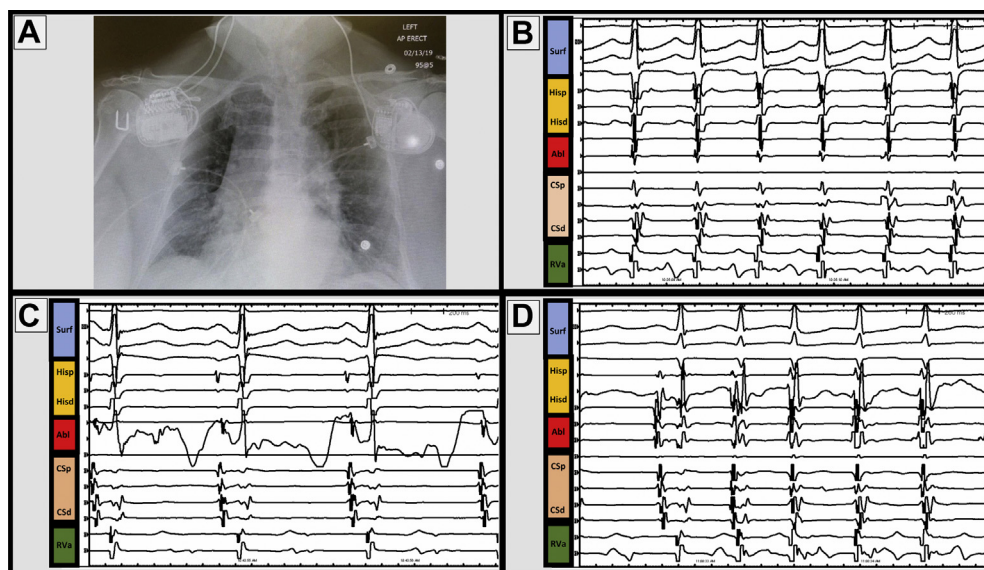
Despite the risks of heating and lead malfunction, as well as the potential for inadvertent tissue damage when radiofrequency energy is applied in the presence of metallic objects, we did not observe any adverse events in our patient. In this case, the subclavicular location of the pulse generators and the distance between the ablation catheter and neurostimulator made damage unlikely. This low probability is supported

by the work of Nguyen and colleagues,<sup>13</sup> who demonstrated that thermal change occurred at a maximal average distance of 5 mm between an ablation catheter and a metal object, whereas distances beyond 5 mm experienced less or insignificant thermal change. Furthermore, given our placement of the ground patch on the patient's back, the DBS was not interposed between the ablation catheter and the ground patch, which further lowered the risk.<sup>13</sup> To confirm that the ablation did not affect the DBS, we measured the lead impedances before and after the procedure and found no significant change.

In addition to the risk of damage to the DBS by RFA, there have also been reports of DBSs causing imaging artifacts including interference with electrocardiographic monitoring.<sup>14</sup> Kooger and colleagues<sup>15</sup> reported a case of a young patient with a DBS for dystonia who presented with tachycardia and had a 3-lead Holter monitor placed, which revealed a rhythm that was interpreted as atrial flutter. The true underlying sinus rhythm was not appreciated until the DBS was turned off.<sup>15</sup> In our case, the 200 Hz signal of the DBS did not affect our use of the EnSite Precision mapping system, likely because our standard high- and low-pass signal filters of 30 and 150 Hz removed this frequency.

## Conclusions

Although further work is needed to confirm our findings, our experience provides further evidence that RFA can be a safe and efficacious procedure for patients with DBS. This information is useful to electrophysiologists who may be tasked with treating arrhythmias in patients with DBS.



**Figure 1** Chest radiograph of deep brain stimulators and intracardiac electrograms. **A:** Chest radiograph of bilateral Activa SC Deep Brain Stimulators (Medtronic Inc, Minneapolis, MN) implanted inferior to the clavicle. **B:** Surface and intracardiac electrograms demonstrating a zero RP tachycardia with the ablation catheter positioned at the site of the slow pathway. **C:** Slow pathway modification with 4 mm Blazer II standard curve radiofrequency ablation catheter (Boston Scientific, Marlborough, MA) (temperature: 55°C, power: 50 W) during sinus rhythm. **D:** Junctional beats during slow pathway modification. Abl = ablation catheter; CSd = distal coronary sinus; CSp = proximal coronary sinus; Hisd = distal His; Hisp = proximal His; RVa = right ventricular apex; Surf = surface.

## References

1. Deuschl G, Schade-Brittinger C, Krack P, et al. A randomized trial of deep-brain stimulation for Parkinson's disease. *N Engl J Med* 2006;355:896e908.
2. Kupsch A, Benecke R, Muller J, et al. Pallidal deep-brain stimulation in primary generalized or segmental dystonia. *N Engl J Med* 2006;355:1978e90.
3. Denys D, Mantione M, Figeet M, et al. Deep brain stimulation of the nucleus accumbens for treatment-refractory obsessive-compulsive disorder. *Arch Gen Psychiatry* 2010;67:1061e8.
4. Mayberg HS, Lozano AM, Voon V, et al. Deep brain stimulation for treatment-resistant depression. *Neuron* 2005;45:651e60.
5. Adams JE, Hosobuchi Y, Fields HL. Stimulation of internal capsule for relief of chronic pain. *J Neurosurg* 1974;41:740-744.
6. Pizzolato G, Mandat T. Deep brain stimulation for movement disorders. *Front Integr Neurosci* 2012;6:1-5.
7. Schupbach WM, Chastan N, Welter ML, et al. Stimulation of the subthalamic nucleus in Parkinson's disease: a 5-year follow-up. *J Neurol Neurosurg Psychiatry* 2005;76:1640-1644.
8. Krack P, Batir A, Van Blercom N, et al. Five-year follow-up of bilateral stimulation of the subthalamic nucleus in advanced Parkinson's disease. *N Engl J Med* 2003;349:1925-1934.
9. Kanagaratnam L, Lee A, Whalley D, Figtree GA. Overcoming artifacts and fears: electrophysiology study and radiofrequency ablation in a Parkinsonian patient with supraventricular tachycardia and a neurostimulator. *Pacing Clin Electrophysiol* 2013;36:e1-3.
10. Gunawardene M, Meyer C, Willems S, Hoffman BA. Cryoablation of an atrioventricular nodal reentrant tachycardia in a patient with an implanted deep brain stimulator. *HeartRhythm Case Rep* 2016;2:258-260.
11. Spiegel J, Fuss G, Backens M, et al. Transient dystonia following magnetic resonance imaging in a patient with deep brain stimulation electrodes for the treatment of Parkinson disease. *J Neurosurg* 2003;99:772-774.
12. Yamamoto T, Katayama Y, Fukaya C, Kurihara J, Oshima H, Kasai M. Thalamotomy caused by cardioversion in a patient treated with deep brain stimulation. *Stereotact Funct Neurosurg* 2000;74:73-82.
13. Nguyen DT, Barham W, Zheng L, Dinagar S, Tzou WS, Sauer WH. Effect of radiofrequency energy delivery in proximity to metallic medical device components. *Heart Rhythm* 2015;12:2162-2169.
14. Martin WA, Camenzind E, Burkhard PR. ECG artifact due to deep brain stimulation. *Lancet* 2003;361:1431.
15. Kooger BLS, Jaspers GJ, Hunnik AV, Delhaas T, Vanagt WY. Deep brain stimulator-induced flutter-like artefact on Holter recording. *Eur Heart J* 2017;38:61.