

Available online at www.sciencedirect.com

journal homepage: www.elsevier.com/locate/radcr

Case report

Paraperitoneal herniation of the ureter[☆]

Bhamidipaty Kanaka Durgaprasad, MD^a, Kompalli J.S.S. Raghu Teja, MD^{b,*},
NagaMalleswara Rao Jannu, MD^c

^a Department of Radiodiagnosis, GIMSR, Visakhapatnam, Andhra Pradesh, India

^b Department of Radiodiagnosis, GITAM Institute of Medical Sciences and Research (GIMSR), Visakhapatnam, 530045, Andhra Pradesh, India

^c Department of General surgery, GITAM Institute of Medical Sciences and Research, Visakhapatnam, India

ARTICLE INFO

Article history:

Received 6 May 2021

Revised 17 July 2021

Accepted 17 July 2021

Keywords:

Ureter

Hernia

Scrotum

Contrast-enhanced computed tomography

Ultrasonography

ABSTRACT

Ureteral herniation into the scrotum is rare and often associated with congenital abnormalities or postoperative anatomic changes. A high index of suspicion is needed to avoid intraoperative ureteric injuries. A 50-year-old man with ureteric herniation into an inguino-scrotal hernia reported acute left flank pain and had a history of recurrent urinary tract infections. Contrast-enhanced computed tomographic evaluation revealed a left ureter extending from the pelvis into the scrotum through the inguinal canal. Screening ultrasound of the scrotum revealed the intrascrotal extension of the ureter along with the other hernial contents and diagnosed as a Paraperitoneal inguinal herniation of the ureter. Various cross-sectional imaging modalities, including Ultrasound, provide good anatomic details that can diagnose the presence of a herniated ureter.

© 2021 The Authors. Published by Elsevier Inc. on behalf of University of Washington.

This is an open access article under the CC BY-NC-ND license

(<http://creativecommons.org/licenses/by-nc-nd/4.0/>)

Introduction

An inguinoscrotal hernia is a common disorder that usually contains various intraperitoneal organs (small intestine, colon, appendix, ovaries, etc.). Ureteral herniation into the scrotum is rare and often associated with congenital abnormalities or postoperative anatomic changes. Patients typically remain asymptomatic, and evidence of ureteral herniation is usually found incidentally. Lower urinary tract symptoms, hematuria, acute urinary obstruction, double phase micturition pressure to initiate or finish voiding, or ipsilateral flank pain with an inguinal hernia may indicate urologic organ

involvement. It should prompt further investigations with ultrasound and CT scans. If left untreated, inguinal hernias can lead to strangulation of the bladder or ureter, which would require surgical resection with ureteric reimplantation. A high index of suspicions is needed to avoid intraoperative ureteric injuries.

Case report

A 50-year-old man with a history of recurrent urinary tract infections and acute left flank pain presented to the ER

[☆] Competing interests: The authors have declared that no competing interests exist.

* Corresponding author. Assistant Professor, Department of Radiodiagnosis, GITAM Institute of Medical Sciences and Research, GITAM Deemed to be University, Visakhapatnam

E-mail address: drkjsr@gmail.com (K.J.S.S.R. Teja).

<https://doi.org/10.1016/j.radcr.2021.07.046>

1930-0433/© 2021 The Authors. Published by Elsevier Inc. on behalf of University of Washington. This is an open access article under the CC BY-NC-ND license (<http://creativecommons.org/licenses/by-nc-nd/4.0/>)

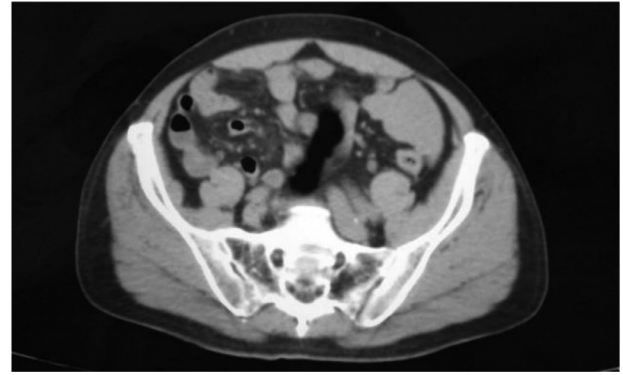
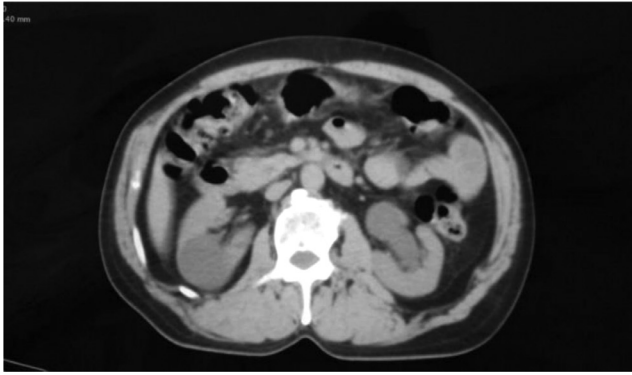

Fig. 1 – Axial plain CT images of the abdomen showing left hydronephrosis and proximal hydroureter.

with recent onset of dysuria and increasing swelling in the left inguinoscrotal region in the absence of fever or scrotal trauma. The gentleman revealed a history of micturition by squeezing his scrotum. There was no relevant surgical or family history. The general physical examination findings were unremarkable, with a normal abdomen at both inspection and palpation; urogenital examination revealed a small left-sided palpable mass of the testis, compatible with an inguinal hernia. At first, gray-scale and color Doppler ultrasonographic images of the abdomen and pelvis were obtained. Contrast-enhanced computed tomographic images of the lower abdomen and pelvis, including the scrotum, were then obtained to evaluate the urinary tract further. Initial preliminary Ultrasound revealed moderate left-sided hydronephrosis with proximal hydroureter and suboptimal visualization of the distal course of the ureter.

Further evaluation with a contrast-enhanced computed tomographic revealed an unusual enhancing structure in the left pelvic and inguinal regions. Further assessment and tracing of the structure revealed the left ureter extending from the pelvis into the scrotum through the inguinal canal. Upon tracing the entire course of the ureter, it appeared to make a sharp turn approximately at the level of the root of the scrotum and then to travel rostrally, where it eventually entered the bladder. Additionally, there appeared to be a hernia sac extending into the inguinal canal with segments of bowel loops, omentum, and fat as contents. Later on, a screening ultrasound of the scrotum revealed the intrascrotal extension of the ureter along with the other hernial contents. Diagnosis revealed Paraperitoneal inguinal herniation of the ureter (Figures 1-6).

Discussion

Herniation of the ureter is rare, and there are about 140 cases approximately that have been reported in the literature, mainly as case reports or few case series [1]. Herniation of the ureter may be of the following types inguinal, femoral, thoracic, and parailiac [2–3]. Because of the rarity of this condition and the fact that it could be clinically indistinguishable from an inguinal hernia or a hydrocele, inguinal hernia involving

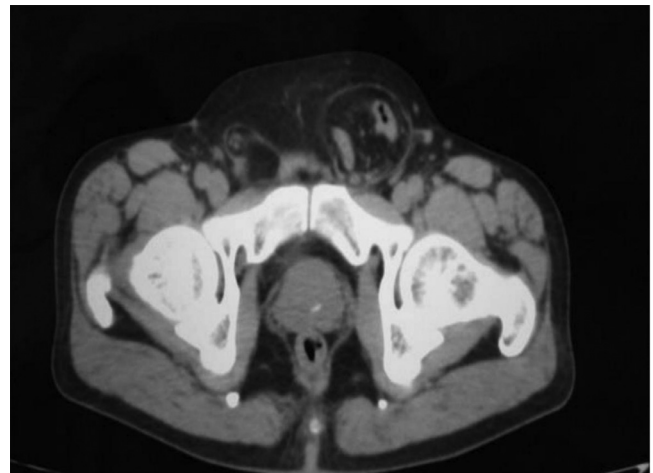


Fig. 2 – Axial plain CT images of the pelvis showing contents of the inguinal hernia (ureter, small bowel loops, omentum and fat).

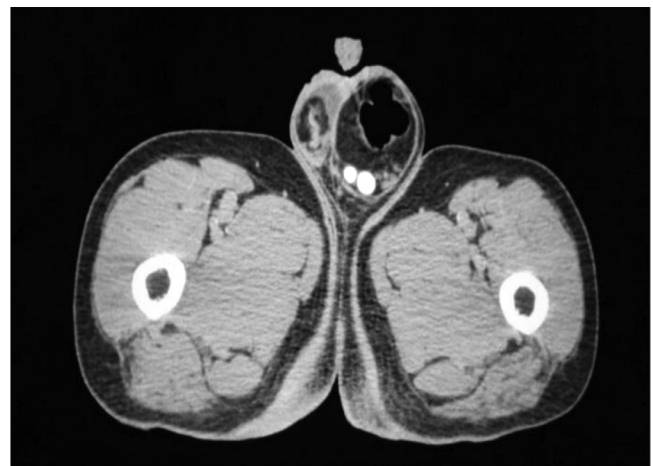

Fig. 3 – Axial Contrast-enhanced computed tomographic images showing efferent and afferent loops of the left ureter in the scrotum.

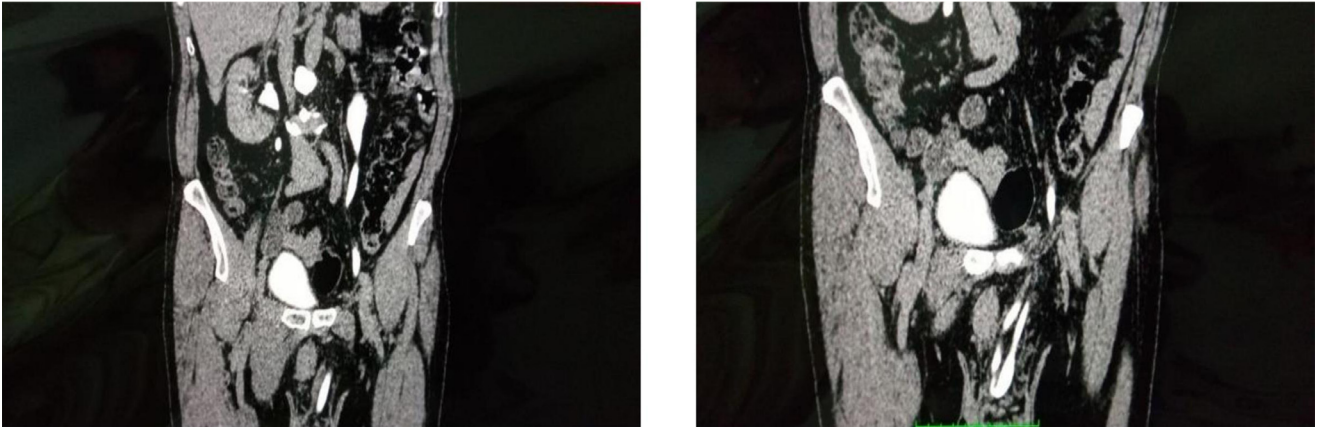


Fig. 4 – Coronal reformatted images of the same patient confirming the course of the ureter.

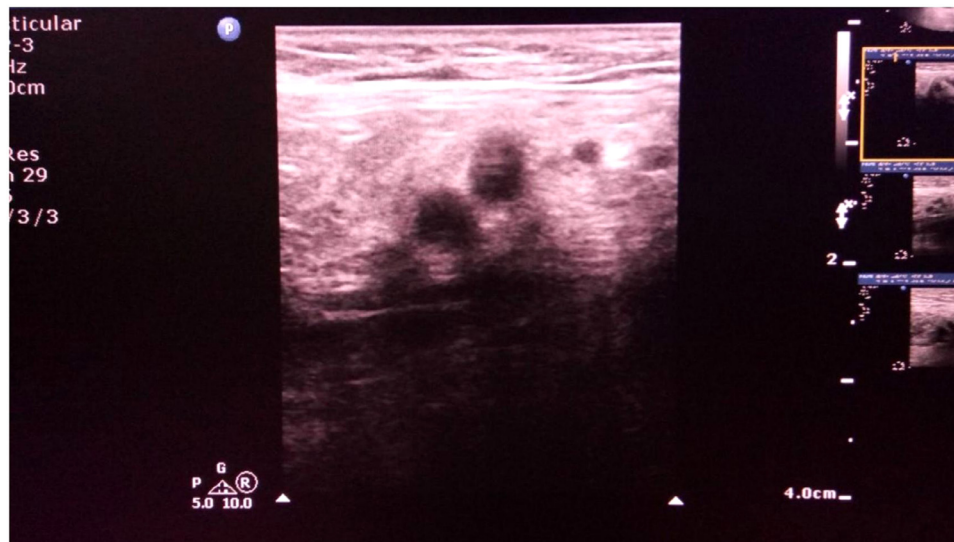

Fig. 5 – Ultrasound image of the scrotum demonstrating the efferent and afferent loops of the ureter.

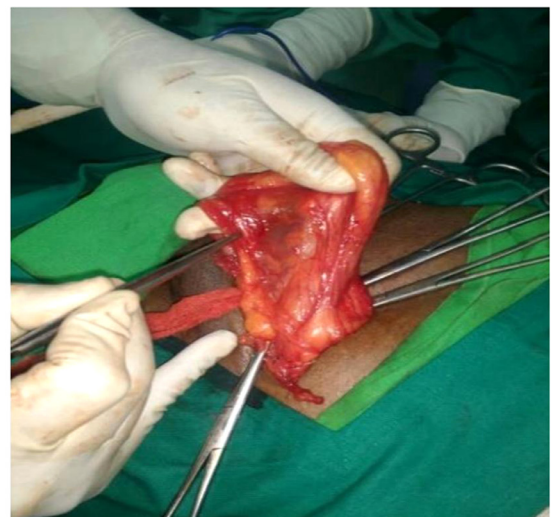
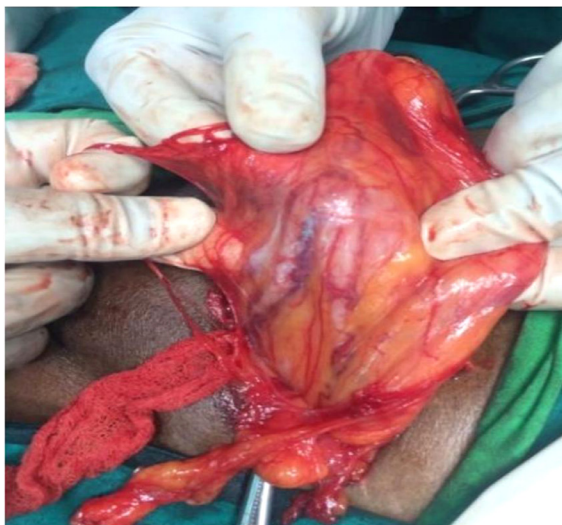

Fig. 6 – Operative images showing the hernial sac with omentum, bowel loops, fat and ureter.

the ureter is difficult to diagnose without imaging and is rarely diagnosed preoperatively [4–5]. Ureteral inguinal herniations incidence is high in males, and with a higher incidence on the right side, that is probably due to the presence of the sigmoid colon contralaterally [6]. A ureteral herniation is more often due to an indirect inguinal hernia (80% of cases) rather than a direct inguinal hernia (20%). Additionally, ureteral herniation is classified into 2 variants, paraperitoneal (80% of cases) and extraperitoneal (20% of cases) [7]. Patients typically remain asymptomatic, and evidence of ureteral herniation is often found incidentally.

The paraperitoneal classification is defined as a loop of ureter that descends with a peritoneal sac into the hernia. This is an acquired pathology in that the ureter develops an adhesion to the peritoneal wall, which then allows it to be pulled into the herniated sac. Paraperitoneal ureteral herniation has a high incidence with kidney transplants, owing to transplant risk factors such as excess length of the grafted ureter and placing the ureter over (rather than under) the spermatic cord have been described in the literature [8]. Extraperitoneal inguinal herniation of the ureter is a rarer entity than the paraperitoneal classification and is believed to be a congenital malformation caused by failure of the ureter to separate from the mesonephric duct during development which further results in the ureter being pulled along with the testis as it descends into the scrotum [9].

While evaluating patients with inguinal hernias, it is crucial to elicit a detailed history to identify urologic organ involvement. Lower urinary tract symptoms, hematuria, acute urinary obstruction, double phase micturition pressure to initiate or finish voiding, or ipsilateral flank pain with an inguinal hernia may indicate urologic organ involvement. It should prompt further investigations with ultrasound and CT scans. If left untreated, inguinal hernias can lead to strangulation of the bladder or ureter, which would require surgical resection with ureteric reimplantation. Depending on the length of the ureter involved, various options for repair would include ureteroneocystostomy, hitch, Boari flap, or possibly transureteroureterostomy. Also, the ipsilateral kidney may become obstructed and nonfunctional, and it may serve as a nidus for recurrent pyelonephritis. In case urologic organ involvement is not identified before surgical repair, there may be a higher risk of iatrogenic damage to the urologic organs; therefore, identification of urologic organ involvement in inguinal hernias is very much essential to prevent surgical complications and also to avoid complications in untreated conditions.

Conclusion

Inguinal hernia of the ureter is a rare finding that may be either acquired or congenital and may be an important cause for obstructive uropathy. The inguinal ureter is prone to injury during hernia repair. Various cross-sectional imaging modalities, including Ultrasound, provide good anatomic details that can diagnose the presence of a herniated ureter.

Patient consent

Written informed consent was obtained from the subject in this study.

REFERENCES

- [1] Odisho AY, Freise CE, Tomlanovich SJ, Vagefi PA. Inguinal herniation of a transplant ureter. *Kidney Int* 2010;78:115.
- [2] Hwang CM, Miller FH, Dalton DP, Hartz WH. Accidental ureteral ligation during an inguinal hernia repair of the patient with crossed fused renal ectopia. *Clin Imaging* 2002;26:306–8.
- [3] Giglio M, Medica M, Germinal F, Raggio M, Campodonico F, Stubinski R, et al. Scrotal extraperitoneal hernia of the ureter: case report and literature review. *Urol Int* 2001;66:166–8.
- [4] Bertolaccini L, Giacomelli G, Bozzo RE, Gastaldi L, Moroni M. Inguino-scrotal hernia of a double district ureter: case report and literature review. *Hernia* 2005;9(3):291–3.
- [5] Sharma RK, Murari K, Kumar V, Jain VK. Inguinoscrotal extraperitoneal herniation of a ureter. *Can J Surg* 2009;52(2):E29–30.
- [6] Giglio M, Medica M, Germinal F, Raggio M, Campodonico F, Stubinski R, et al. Scrotal extraperitoneal hernia of the ureter: case report and literature review. *Urol Int* 2001;66(3):166–8.
- [7] Yahya Z, Al-Habbal Y, Hassen S. Ureteral inguinal hernia: an uncommon trap for general surgeons. *BMJ Case Reports* 2017;2017. doi:10.1136/bcr-2017-219288.8.
- [8] Ghielmini E, Julita E, Cerantola Y, Matter M, Zingg T. Inguinal bladder hernia with acute ureteral obstruction 14 years after kidney transplantation: a case report. *Transplant Proc* 2017;49(7):1593 PMID: 28838448. doi:10.1016/j.transproceed.2017.04.003.
- [9] Kalidas E, Gourgiotis S, Veloudis G, Exarchou E, Vlachos K, Villias C. Asymptomatic extraperitoneal inguinoscrotal hernia involving ureter: a case presentation and review of the literature. *J Nat Sci Biol, Med* 2015;6(3):153–5. doi:10.4103/0976-9668.166126.