

Oncology

Rare soft tissue tumor presenting as inguinal swelling

Mohammed Azaiza^{b,*}, Nuntida Surachaicharn^a, James Siegert^{a,b,c}^a Midwestern University, Downers Grove, IL, 60515, USA^b Franciscan Health Olympia Fields, Olympia Fields, IL, USA^c Specialty Physicians of Illinois, Olympia Fields, IL, USA

A B S T R A C T

Cellular angiofibroma (CAF) is a rare, benign mesenchymal tumor found usually in the female vulvar and male inguinoscrotal regions. A 56-year-old Caucasian gentleman presented with left sided scrotal swelling after masturbating. The swelling was thought to be an inguinal hernia, although was found to be a soft tissue tumor upon dedicated cross-sectional imaging. Pathological evaluation of the mass revealed it to be a cellular angiofibroma. Diagnosis of CAF can only be made after resection and proper immunohistological staining. Ultrasonography and MRI are preferred for detailed soft tissue characterization. After surgical resection, follow-up imaging is recommended given potential risk of malignancy.

Introduction

Cellular angiofibroma (CAF) is rare benign mesenchymal tumor of unknown etiology found usually in the female vulvar and male inguinoscrotal regions. CAF has also been reported in the knee, upper eyelid, oral, and perianal region.¹ Because literature on CAF is rare, and diagnosis is complicated by the possibility of malignancy, we report a case of a 56-year-old male with CAF in the scrotum.

Case report

A 56-year-old Caucasian male with no past medical history presented to general surgery clinic for a consult of umbilical and right inguinal hernia that was reducible, along with a left sided scrotal mass. CT scan of the pelvis revealed a “large, tubular soft tissue mass (3.4 × 8.10cm) within the lower anterior pelvic wall extending into the L scrotum. This is separate from the inguinal canal and is concerning for soft tissue sarcoma” (Fig. 1). The patient was then referred to our urology clinic. The patient reported some swelling along his left penis and prepubic area after masturbating approximately 3 weeks prior. He also reported an emergency department visit seven years prior for abdominal pain, when a CT showed a 2 × 3 cm mass in the exact same area. He denied flatulence or tenderness, changes in bowel or bladder function, previous scrotal trauma, weight loss or changes in appetite, fever, chills or bone pain. All other review of systems was negative.

His physical exam revealed a palpable, soft, freely movable suprapubic and left inguinal scrotal mass and no flatulence. The mass was indistinguishable from the left testicle, lacked clear separation from left

corpora, and no hernia or lymphadenopathy was noted. At this time, the anterior pelvic wall mass extending to the left scrotum (3.4x8x10cm) was concerning for a spermatic cord sarcoma. Left inguinal orchiectomy with possible scrotectomy and resection of the abdominal wall and musculature was considered. Repeat CT showed mildly thickened urinary bladder wall, lobulated tubular soft tissue mass within the lower anterior pelvic wall extending to the scrotum on the left, with a tiny right hydrocele and fat containing right inguinal hernia.

The patient underwent a wide excision of the anterior pelvic mass with left radical orchiectomy en bloc (Fig. 2) and flexible cystoscopy, without any complications. Pathological evaluation by Cleveland Clinic found a cellular angiofibroma measuring up to 16cm, and staining strongly positive for CD34, but negative for actin, S-100, desmin, and smooth muscle actin (Fig. 3). In follow-up at our clinic 5 days after discharge, the patient reported no post-operative problems and no significant pain.

Discussion

Cellular angiofibroma is an uncommon benign mesenchymal tumor that usually presents as a 5–6cm inguinoscrotal mass in men in their mid 50s.¹ Because CAF often presents as a slow growing, painless, solid mass of atypical shape, it can be mistaken for soft tissue sarcoma or even seminoma. CAF also resembles angiomiofibroblastoma and aggressive angiomyxoma, which have a very high rate of local recurrence.¹ Given the possibilities of malignancy and recurrence, suspected CAF demands appropriate work up and correct diagnosis.²

For patients presenting with inguinoscrotal mass, skillful diagnosis

* Corresponding author.

E-mail addresses: mohammed.azaiza@med.lecom.edu (M. Azaiza), nsurachaicharn65@midwestern.edu (N. Surachaicharn), jsiegert@gmail.com (J. Siegert).

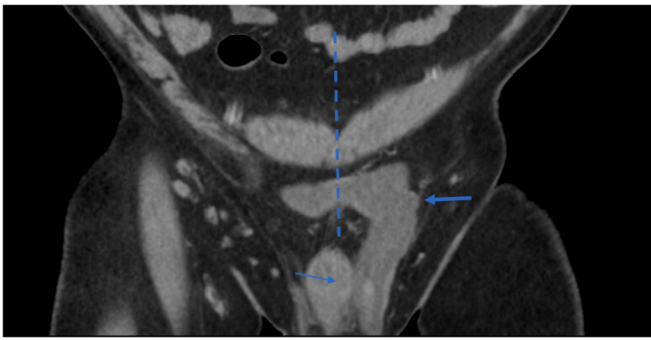


Fig. 1. Coronal view of Computerized Tomography (CT) of the pelvis. CT demonstrated large heterogenous lesion (bold arrow) adjacent to the left corpora cavernosum and crossing anatomical midline (dash blue line).

begins with a thorough history and physical exam. The choice of imaging modality is also essential. Ultrasound is preferred for inguinal scrotal pathologies. However, because cellular angiofibroma shows a

solid mass with heterogenous echogenicity, ultrasound cannot differentiate between benign and malignant tumors. MRI can be useful for precise localization, and differentiation between lesions of testicular versus non-testicular origin. MRI also facilitates as well as characterize the lesion into cystic, solid, mixed as well as detect fat and fibrosis within the lesion. CT is not recommended because it tends to show a poorly defined heterogeneous mass. Ultrasound and MRI are very reliable while CT is not beneficial to show tissue characteristics.³ Regardless of imaging results, first-line treatment for inguinoscrotal tumors is surgical resection, followed by definitive pathological diagnosis.⁴

Differential diagnosis can be informed by microscopic evaluation. CAF is a bland, fatty tumor of spindle cells with no particular pattern and is sometimes found in the myxoid stroma with wispy collagen.⁵ Small-medium sized blood vessels thick with mural hyalinization may be abundant. Immunohistochemical workup may include pRB, MDM2, desmin, CD34, p16 and ER/PR. Although CAF and angiomyxomas are both found in the pelvic region, CAF is typically negative for pRB, but positive for angiomyxoma. A recent report of a ER/PR + epididymal case of CAF hints at a possible hormonal role in CAF pathogenesis.

The potential risks of recurrence and malignant transformation are

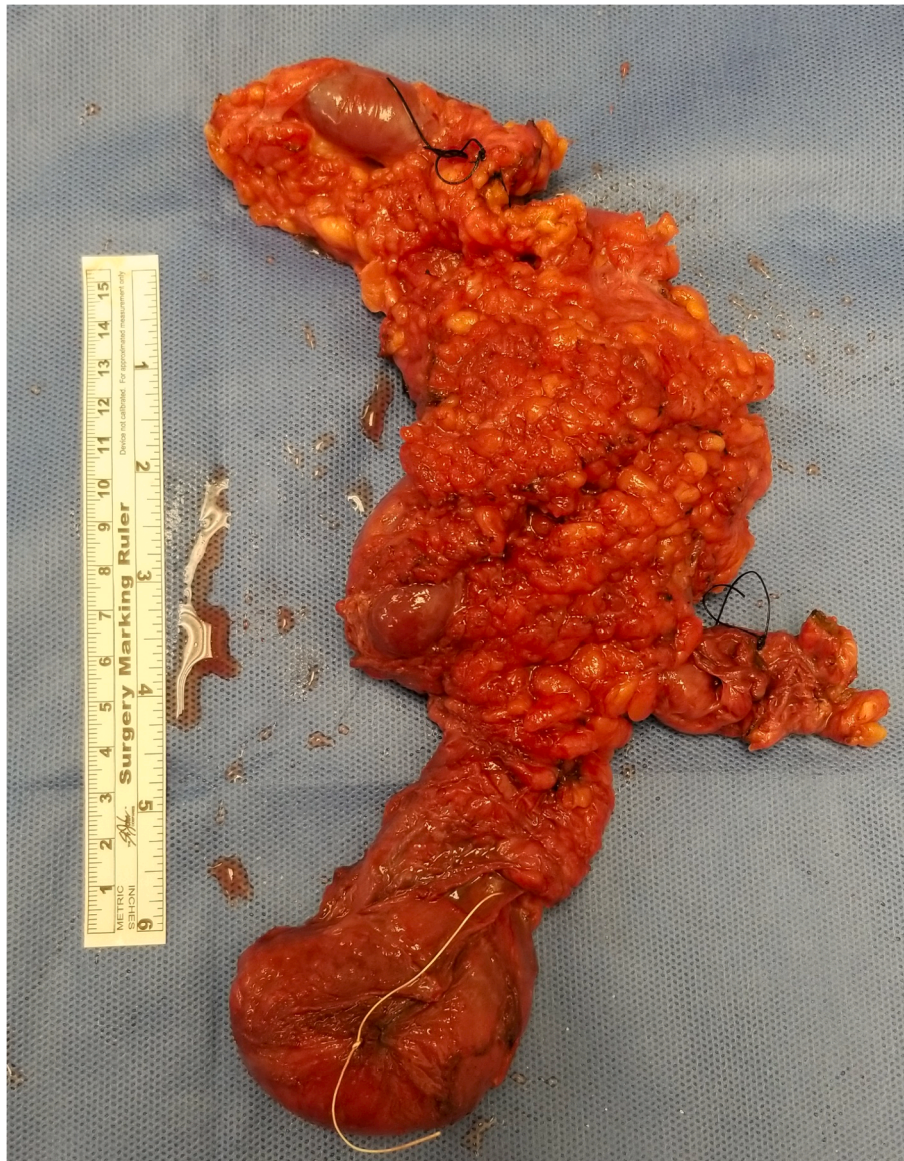


Fig. 2. Gross specimen from en bloc resection of soft tissue tumor. Inferior white suture tags left testicle. Right dark suture tags left spermatic cord, Superior dark suture tags most lateral aspect of tumor.

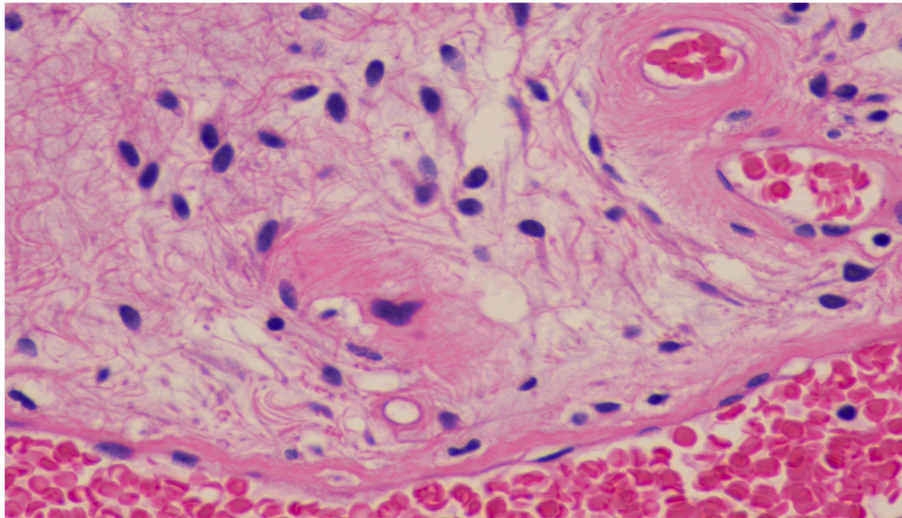


Fig. 3. Microscopic slide, high-power: demonstrating spindle cells in a myxoid stroma with collagen and small size blood vessels, characteristic of cellular angiofibroma.

considered low in cases where excision is complete. But with so few reported cases, prognosis is uncertain, and patients should be followed with a physical and imaging three months after surgery.²

Conclusion

CAF is a benign mesenchymal tumor that can be confused with angiomyxomas and other malignant spindle neoplasms. Diagnosis depends on a thorough work up, imaging with ultrasound and MRI, and judicious histopathology. Complete cure is possible with surgical excision, however follow-up at three months should evaluate for possible recurrence.

References

1. Emtage JB, Parker J, Marcet JE, Finan J, Lockhard JL, Hernandez DJ. A large cellular angiofibroma of the male pelvis presenting with obstructive voiding: a case report and review of the literature. *Can Urolog Assoc.* 2013;7(5-6):e373–e375.
2. Gou Q, Zhang J, Xie J, Ma D, Zhang Y. A rare cellular angiofibroma of the epididymis. *Asian J Androl.* 2018;20:95–96.
3. Aydin M, Uzuner HO, Akgunes E, Bitkin A, Kadihasanoglu M. Cellular angiofibroma of the spermatic cord. *Thieme.* 2017;48:159–160.
4. Chun KH, Inn FX, Hing EY, Hong GE. Imaging modalities for an uncommon inguinal scrotal pathology: a case report and literature review. *Wolters Kluwer-Medknow.* 2015; 9(4):387–389.
5. McCarthy AJ, Chetty R. Tumors composed of fat are no longer a simple diagnosis: an overview of fatty tumours with a spindle cell component. *J Clin Pathol.* 2017;71: 483–492.