



ORIGINAL ARTICLE

Evaluation of post-extraction healing after atraumatic axial tooth extraction using Benex system II versus conventional extraction: Randomized control trial



Alaa Z. Makki^a, Afnan A. Nassar^b, Wajan M. Alharbi^{c,*}, Walaa F. Bisharah^c,
Mona A. Alabdali^c, Anwar M. Alqurashi^c, Noor A. Basandawa^c

^a Oral and Maxillofacial Surgery Department, Faculty of Dental Medicine, Umm Al-Qura University, Makkah 24225, Saudi Arabia

^b Department of Preventive Dentistry, Division of Public Health, Faculty of Dental Medicine, Umm Al-Qura University, Makkah 24225, Saudi Arabia

^c Dental Intern, Faculty of Dental Medicine, Umm Al-Qura University, Makkah 24225, Saudi Arabia

Received 9 January 2021; revised 30 May 2021; accepted 5 September 2021

Available online 14 September 2021

KEYWORDS

Benex system;
Conventional extraction;
Complication;
Socket healing

Abstract *Background and Purpose:* Tooth extraction is critical for dental treatment complications. One of the most discussed topics is socket healing after extraction. The Benex system allows extraction without causing unnecessary socket expansion by removing the tooth vertically, preserving both bone and soft tissue.

Aim: To assess postoperative healing signs, symptoms, and complications using the Benex extraction system and compare it with conventional extraction among patients at Umm Al-Qura University.

Methods: Thirty-eight patients with hopeless single-rooted teeth were included. They were divided into two equal groups: one in which teeth were extracted using the conventional method and one in which extractions were performed by Benex. The Benex system for tooth extraction was performed by drilling into the root canal, followed by screw insertion. Once the extractor was properly positioned, extraction was accomplished by turning the hand screw clockwise. At baseline, the wound size was evaluated. On days 1, 3, and 7 after extraction, telephone interviews were conducted to evaluate pain and post-extraction complications using a pain scale and question-

* Corresponding author.

E-mail addresses: Wajan.alharbi@hotmail.com, wbisharah@gmail.com (W.M. Alharbi).

Peer review under responsibility of King Saud University.



naire. Socket healing and wound size were evaluated after 2 and 4 weeks of extraction using the healing index and H₂O₂ epithelization test.

Results: The Benex extraction system accelerated early soft-tissue healing and decreased pain and wound size compared with the control group. **Conclusion.** The Benex system is relatively safe and easy to use, but this does not eliminate the need for a degree of education and training. Proper selection of the case, knowledge of using the device, and implementation of that knowledge in the treatment planning are important factors in ensuring success with this system.

© 2021 The Authors. Production and hosting by Elsevier B.V. on behalf of King Saud University. This is an open access article under the CC BY-NC-ND license (<http://creativecommons.org/licenses/by-nc-nd/4.0/>).

1. Introduction

Extraction is considered a routine dental practice, and a patient may develop postoperative pain, noting variation in the degree of severity among patients. This variation is related to the amount of trauma incurred during surgery (Al-Khateeb and Alnahar, 2008). Therefore, decreasing the degree of trauma is necessary to preserve the hard and soft tissue parameters around the tooth being extracted, which affects treatment planning, outcome, and prognosis (Kubilius et al., 2012).

One of the most discussed topics in dental research is socket healing after tooth extraction. Healing is defined as the recovery of damaged tissue in the body. This can occur without swelling, hematoma, pain, trismus, or any signs of inflammation or infection that delay healing and can be considered as postoperative complications (Srinivas et al., 2018) (Walter and Israel, 1987) (Rakhshan, 2015).

Two to seven days following a non-surgical tooth extraction, the socket is quickly loaded with a blood clot that is then entirely replaced by growth in granulation tissue density. Epithelialisation is initiated within 24 h and finishes after 1–5 weeks (Pippi, 2017). However, a complete or partial breakdown of the blood clot or empty socket may occur alongside severe pain within 3 days following extraction, which is called dry socket and is one of the most common postoperative complications (Nitzan, 1983).

The Benex extraction system allows for the extraction of teeth without causing unnecessary socket expansion by removing the tooth in the axial direction from its socket. This provides a minimally invasive extraction while preserving both bone and soft tissue at a maximum and reduces the need for flap surgery. The Benex system consists of the Benex extractor itself, diamond burs, pull strings, self-tapping screws, and sectional impression trays (Dietrich et al., 2019) (Hong et al., 2018). There is limited data in the literature regarding postoperative healing after using a vertical tooth extraction system. Therefore, the aim of our study was to assess postoperative healing, including socket wound healing, and to investigate the pain experience and complications after extraction using a Benex extraction system compared with conventional intra-alveolar extraction. Accordingly, the outcomes of this study may help improve a patient's quality of life after dental procedures.

2. Materials and methods

2.1. Study design

This study was a double randomized control trial.

2.2. Subjects and study sample

This study included 38 patients aged 30 to 60 years who were recruited from the Oral and Maxillofacial Surgery Clinic, Faculty of Dentistry, Umm Al-Qura University, Makkah, Saudi Arabia. The study included patients of both gender with a non-restorable single-rooted tooth for extraction. Patients with deciduous teeth, impacted teeth, and teeth with greater than grade I mobility or patients with systemic diseases were excluded.

2.3. Sample size and sample selection

The sample size was calculated for a normal population with a confidence level of 95% and precision of 5% and was calculated using a sample-size calculator (calculator.net) (Nitzan, 1983).

The selected participants were divided into two groups with an allocation ratio of 1:1. Group I consisted of 19 patients who had dentoalveolar extractions with forceps and was considered a control group. Group II consisted of 19 patients treated with the Benex system. Randomisation and double blinding were performed to avoid any bias.

2.4. Statistical method

The statistical data of our research were normally distributed, and unpaired parametric methods were used for analysis.

2.5. Clinical procedure

2.5.1. Extraction method

Anaesthesia was performed under infiltration with 4% articaine hydrochloride with adrenaline (dilution, 1:100000; Septodont, Saint-Maur-des-Fossés, France). Sharpey fibres were cut in the gingival sulcus using a periotome and desmotome (Nordent, Elk Grove Village, IL, US). The coronal part should be at least 2 mm of supragingival tissue. Drilling with the diamond-coated twist drill was performed on the long axis of the tooth and at the centre of the root. The depth of the drilling should be 7 mm inward and with an outward movement. The screw was inserted and the support disk was positioned on adjacent crowns. After the traction rope was inserted into the extraction screw, it was located over the roller and fixed to the notch of the extraction side. Extraction was accomplished by turning the hand screw clockwise (Fig. 1).

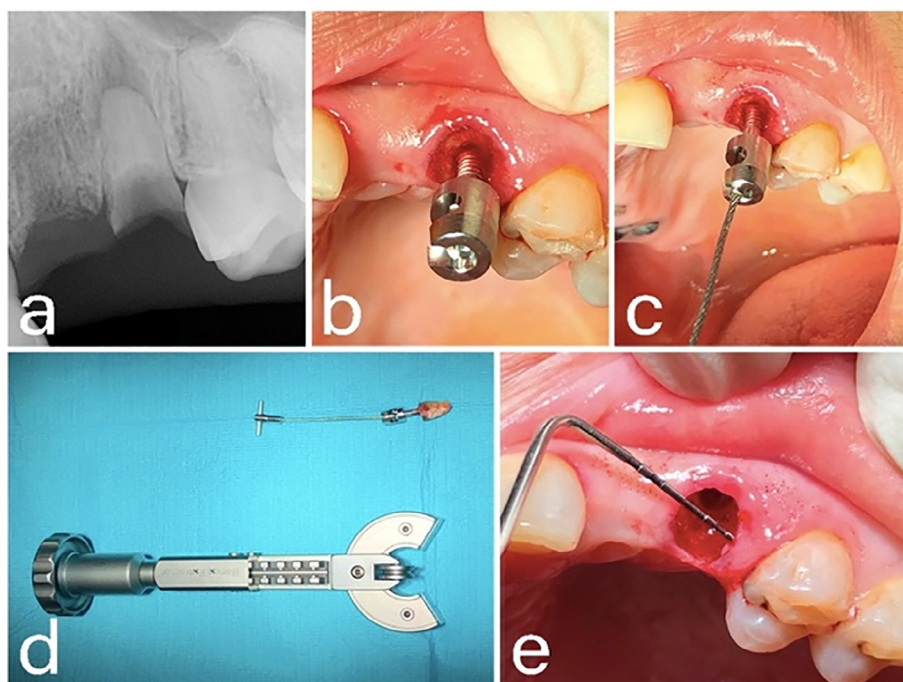


Fig. 1 Extraction of an upper left canine in a 40-year-old woman with the Benex system. (a) Periapical radiograph of the tooth to be extracted. (b) After drilling the tooth, the screw is inserted using a screwdriver. (c) A pull string is hooked into the screw. (d) Benex extraction system and the extracted tooth. (e) The socket after extraction.

2.6. Evaluation method

2.6.1. Pain and post-extraction complication assessment

A questionnaire and pain numeric scale were recorded through three telephone interviews on the evening of the day of tooth extraction and then on days 3 and 7 after tooth extraction. During each interview, the participants were asked about their pain intensity and to score it from 0 (no pain) to 10 (worst pain possible). In addition, they were asked about any possible complications, such as swelling, bleeding, and dry socket.

2.6.2. Socket wound healing assessment

Landry, Turnbull, and Howley index (LWHI) and H₂O₂ epithelialisation tests were performed 2 weeks and 4 weeks after tooth extraction (Ustaoglu et al., 2020). In addition, the extraction socket was measured (Mokhtari et al., 2019). The LWHI evaluates the extraction socket with regard to wound size, tissue colour, bleeding on palpation, presence of granulation tissue, presence of pus, and gingival margin status. Complete wound epithelialisation (CWE) was evaluated for the socket wound by performing the H₂O₂ bubbling test. This test is established based on the metric that if there is discontinuous healing of the epithelium, H₂O₂ will spread in the connective tissue and catalase will break it down to release oxygen and water, creating bubbles in the wound. The field to be assessed was dried and 3% H₂O₂ was applied to the wound using a syringe. The presence of bubbles indicated incomplete epithelialisation. The CWE rate was determined as follows:

$$\text{CWE}(\%) = \frac{\text{number of sites with CWE}(+) \times 100}{\text{total number of sockets}}$$

For wound size determination, the greatest dimensions of each socket were assessed by linear measurements in the mesiodistal and buccolingual directions using a periodontal probe. The paired dimensions were multiplied to yield the square area of the wound (mm²). This single-digit product was compared at three different periods: baseline, 2 weeks, and 4 weeks after extraction.

3. Results

3.1. Baseline characteristics

The study included 38 participants that were divided into two groups: Group 1 (n = 19), had conventional extraction, and group 2 (n = 19) underwent Benex extraction in Table 1.

3.2. Pain and post-extraction complication assessment

The prevalence of post extraction complications on the first day was 15.8% in the control group and 10.5% in the Benex group, the two groups only reported swelling. The comparison of pain scores between the groups showed a significant difference in the Benex group (p = 0.003) based on the unpaired *t*-test, indicating that the Benex group had less pain on day 3.

Pain intensity decreased gradually in both groups, as shown in Fig. 2. It is noteworthy that day 3 had the best result, where the conventional and Benex groups had 5.3% and 31.6% of patients reporting no pain, respectively.

Table 1 Participant baseline characteristics.

	Control group (n = 19)	Benex group (n = 19)
Age (years)		
20–29	8 (42.1%)	3 (15.8%)
30–39	4 (21.1%)	1 (5.3%)
40–49	6 (31.6%)	9 (47.4%)
50–60	1 (5.3%)	6 (31.6%)
Gender		
Female	13 (68.4%)	12 (63.2%)
Male	6 (31.6%)	7 (36.8%)

3.3. Socket wound healing assessment

A comparison of the healing process in the Benex group throughout the different periods of follow-up is shown in Fig. 3.

Landry, Turnbull, and Howley Index LWHI assessment. Wounds were graded on a scale of 1–5, where 1 indicated very poor healing and 5 indicated excellent healing. The results are presented in Table 2.

H₂O₂ epithelization test.

In the second week, both groups showed incomplete epithelialisation. On week four, the control group showed incomplete epithelialisation, while the Benex group showed 42.1% complete wound epithelialisation. Based on the chi-squared test, there was a significant difference (p = 0.023).

Wound size. Results for wound size are shown in Table 3.

4. Discussion

Extraction of remaining tooth roots can be challenging. However, as clinicians, it is our priority to preserve the surrounding soft and hard tissues after tooth extraction. The Benex system is considered one of the most innovative oral surgical instru-

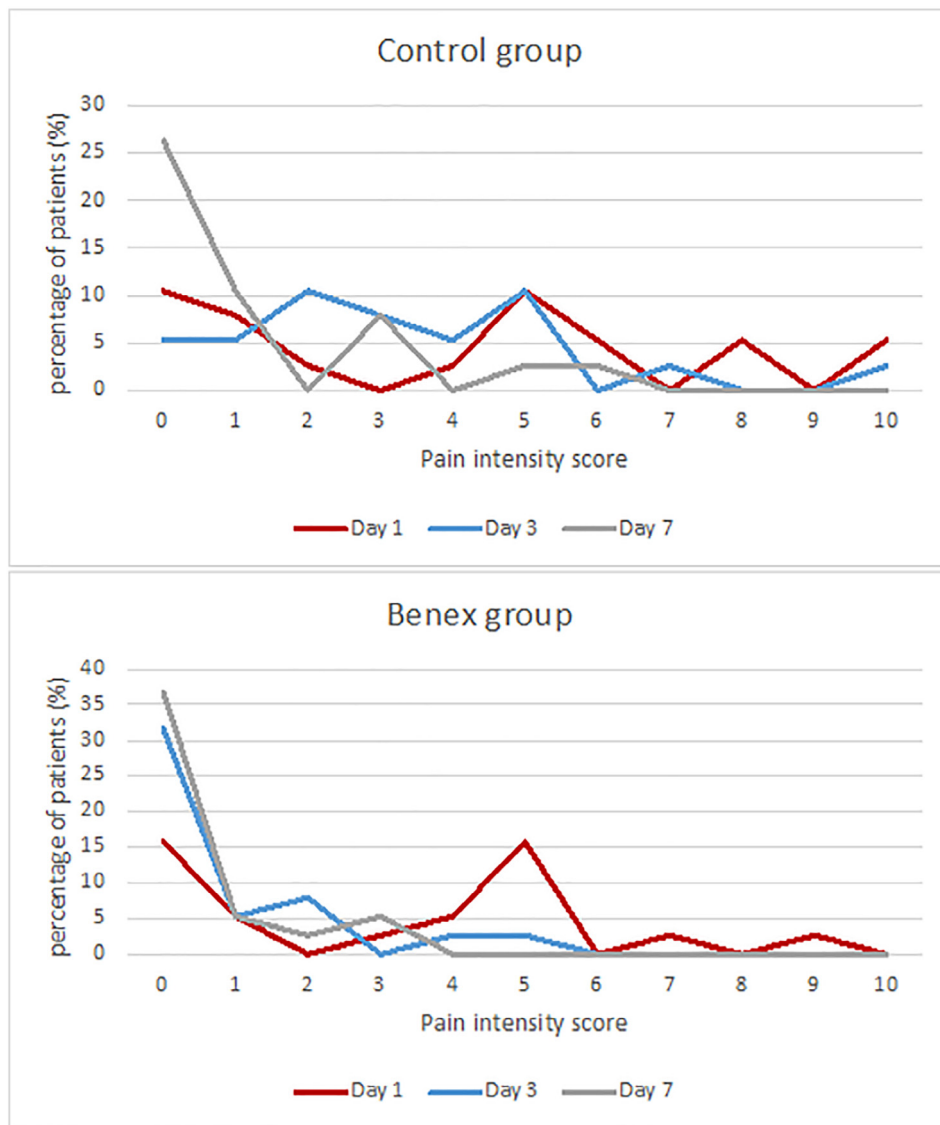


Fig. 2 Distributions of pain intensity according to scores throughout the follow-up period in both groups.

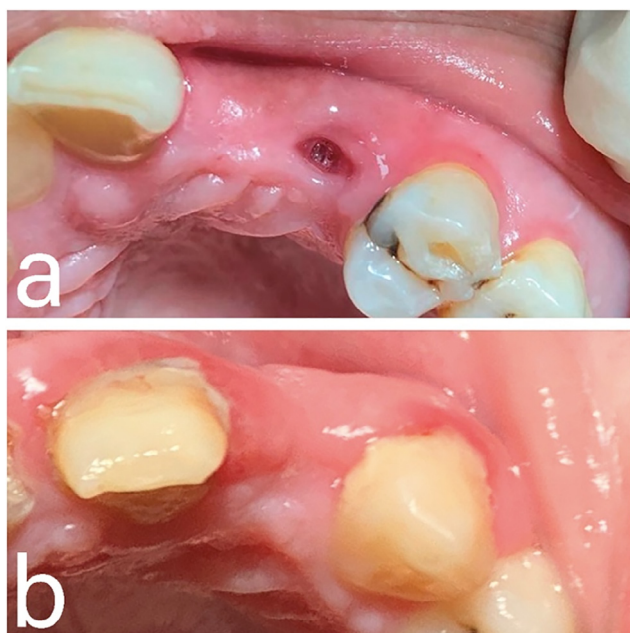


Fig. 3 Evaluation of healing process in Benex group at different follow-up periods. (a) At week 2. (b) At week 4.

ments, and our results support the promotion and promising goal of the system as a minimally invasive approach.

Our study included single-rooted teeth only, although the system can be used for multirooted teeth after separation. However, [Muska et al. \(2013\)](#) reported a lower success rate in multirooted teeth (43%), whereas single-rooted teeth had a far higher success rate (89%). This previous study discussed the major causes of failure with Benex, where one is an incompatibility in root morphology with the vertical removal technique of the device. The other cause is the retention inadequacy of the

screw and/or root fractures. However, the same study stated that only eight teeth (7%) required surgery after a failed Benex extraction, which strongly suggests that its use can reduce the need for surgical extractions ([Muska et al. 2013](#)).

There was one case of dry socket observed in the control group, but none in the Benex group. The patient developed a dry socket and was instructed to come to the emergency department to flush out the socket and apply gel dressing and was prescribed analgesics.

Our study has some limitations. First, complications were evaluated subjectively by the patient, and no clinical examination was performed. Second, wound healing assessment was considered a challenge for numerous reasons, including the lack of standardisation for an accurate description of socket healing and the absence of an approved measuring method for evaluating wound healing.

However, recent studies have shown that measuring wound borders alone is sufficient for reporting wound healing, even if the depth of the wound is neglected ([Mokhtari et al., 2019](#)), and the sample size limitation is a consequence of the COVID-19 pandemic.

5. Conclusion

The Benex system is relatively safe and easy to use, but this does not eliminate the fact that the use of the device requires a degree of education and training. Proper case selection, knowledge in using the device, and implementation of that knowledge in treatment planning are important factors in ensuring the success of this system.

Funding

This research did not receive any specific grant from funding agencies in the public, commercial, or not-for-profit sectors.

Table 2 Comparison of the healing scores obtained according to Landry, Turnbull, and Howley index throughout follow-up period.

	Week 2		Week 4	
	Control	Benex	Control	Benex
	Frequency (%)	Frequency (%)	Frequency (%)	Frequency (%)
1. Very Poor	5 (26.3%)	1(5.3%)	0 (0%)	0 (0%)
2. Poor	7 (36.8%)	1(5.3%)	2 (10.5%)	0 (0%)
3. Good	7 (36.8%)	5 (26.3%)	8(42.1%)	1(5.3%)
4. Very Good	0 (0%)	11(57.9%)	8(42.1%)	10(52.6%)
5. Excellent	0 (0%)	1(5.3%)	1(5.3%)	8(42.1%)
P (95% CI)	0.001		0.007	

Table 3 Comparison of wound size between groups at baseline, 2 and 4 weeks after tooth extraction.

	Baseline			Week 2			Week 4		
	Control	Benex	P value (95% CI)	Control	Benex	P value (95% CI)	Control	Benex	P value (95% CI)
Mean wound size (mm ²)	37.84	26.00	0.001	16.84	10.05	0.011	9.79	3.68	0.012
SD	11.11	9.978	–	5.540	7.699	–	6.909	6.263	–

CRedit authorship contribution statement

Alaa Z. Makki: Supervision, Funding acquisition. **Afnan A. Nassar:** Supervision. **Wajan M. Alharbi:** Data curation, Visualization. **Walaa F. Bisharah:** Methodology, Writing – original draft. **Mona A. Alabdali:** Conceptualization, Investigation. **Anwar M. Alqurashi:** Resources, Writing – review & editing. **Noor A. Basandawa:** Formal analysis, Investigation.

Declaration of Competing Interest

The authors declare that they have no known competing financial interests or personal relationships that could have appeared to influence the work reported in this paper.

References

- Al-Khateeb, T.H., Alnahar, A., 2008. Pain Experience After Simple Tooth Extraction. *J. Oral Maxillofac. Surg.* 66 (5), 911–917. <https://doi.org/10.1016/j.joms.2007.12.008>.
- Dietrich, T., Krug, R., Krastl, G., Tomson, P.L., 2019. Restoring the unrestorable! Developing coronal tooth tissue with a minimally invasive surgical extrusion technique. *Br. Dent. J.* 226 (10), 789–793.
- Hong, B., Bulsara, Y., Gorecki, P., Dietrich, T., 2018. Minimally invasive vertical versus conventional tooth extraction: An interrupted time series study. *J. Am. Dent. Assoc.* 149 (8), 688–695.
- Kubilius, M., Kubilius, R., Gleiznys, A., 2012. The preservation of alveolar bone ridge during tooth extraction. *Stomatologija*.
- Mokhtari, S., Sanati, I., Abdolahy, S.h., Hosseini, Z., 2019. Evaluation of the effect of honey on the healing of tooth extraction wounds in 4-to 9-year-old children. *Niger. J. Clin. Pract.* 22 (10), 1328. https://doi.org/10.4103/njcp.njcp_102_19.
- Muska, E., Walter, C., Knight, A., Taneja, P., Bulsara, Y., Hahn, M., Desai, M., Dietrich, T., 2013. Atraumatic vertical tooth extraction: a proof of principle clinical study of a novel system. *Oral Surg. Oral Med. Oral Pathol. Oral Radiol.* 116 (5), e303–e310.
- Nitzan, D.W., 1983. On the genesis of “dry socket”. *J. Oral Maxillofac. Surg.* 41 (11), 706–710.
- Pippi, R., 2017. Post-surgical clinical monitoring of soft tissue wound healing in periodontal and implant surgery. *Int. J. Med. Sci.* 14 (8), 721–728.
- Rakhshan, V., 2015. Common risk factors for postoperative pain following the extraction of wisdom teeth. *J. Korean Assoc. Oral Maxillofac. Surg.* 41 (2), 59. <https://doi.org/10.5125/jkaoms.2015.41.2.59>.
- Srinivas, B., Das, P., Rana, MoumitaMaity, Qureshi, AbdulQahar, Vaidya, KedarC, Ahmed Raziuddin, ShaikhJunaid, 2018. Wound healing and bone regeneration in postextraction sockets with and without platelet-rich fibrin. *Ann. Maxillofac. Surg.* 8 (1), 28. https://doi.org/10.4103/ams.ams_153_17.
- Ustaoglu, G., Goller Bulut, D., Gümüş, K.Ç., 2020. Evaluation of different platelet-rich concentrates effects on early soft tissue healing and socket preservation after tooth extraction. *J. Stomatol. Oral Maxillofac. Surg.* 121 (5), 539–544.
- Walter, J.B., Israel, M.S., 1987. *General pathology 6th ed.* New York Churchill Livin