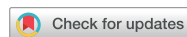

Images in
Cardiovascular Medicine



Coil Embolization for Supra-annular Rupture During Transcatheter Aortic Valve Replacement Under Extracorporeal Membrane Oxygenation Support

Hee Jeong Lee , MD¹, In-Cheol Kim , MD, PhD¹, Hyoung-Seob Park , MD¹, Woo Sung Jang , MD, PhD², Jae Bum Kim , MD², Jin Young Kim , MD³, Seung-Ho Hur , MD, PhD¹, and Cheol Hyun Lee , MD, PhD¹

OPEN ACCESS

Received: Sep 28, 2021

Accepted: Nov 3, 2021

Published online: Nov 29, 2021

Correspondence to

Cheol Hyun Lee, MD, PhD

Division of Cardiology, Department of Internal Medicine, Keimyung University Dongsan Medical Center, 56, Dalseong-ro, Jung-gu, Daegu 41931, Korea.

Email: movicbeat@gmail.com

Copyright © 2022. The Korean Society of Cardiology

This is an Open Access article distributed under the terms of the Creative Commons Attribution Non-Commercial License (<https://creativecommons.org/licenses/by-nc/4.0>) which permits unrestricted noncommercial use, distribution, and reproduction in any medium, provided the original work is properly cited.

ORCID iDs

Hee Jeong Lee

<https://orcid.org/0000-0002-0243-6954>

In-Cheol Kim

<https://orcid.org/0000-0002-5751-2328>

Hyoung-Seob Park

<https://orcid.org/0000-0002-8042-1029>

Woo Sung Jang

<https://orcid.org/0000-0001-5805-670X>

Jae Bum Kim

<https://orcid.org/0000-0002-8820-9866>

Jin Young Kim

<https://orcid.org/0000-0001-6714-8358>

Seung-Ho Hur

<https://orcid.org/0000-0002-3895-1915>

¹Division of Cardiology, Department of Internal Medicine, Keimyung University Dongsan Hospital, Daegu, Korea

²Department of Cardiothoracic Surgery, Cardiovascular Center, Keimyung University Dongsan Hospital, Daegu, Korea

³Department of Radiology, Keimyung University Dongsan Hospital, Daegu, Korea

A 79-year-old woman was admitted for dyspnea due to severe aortic valve (AV) stenosis. Because of rheumatic mitral stenosis, she underwent mechanical mitral valve replacement previously. Computed tomography (CT) showed calcification in the tricuspid AV leaflets (annulus perimeter, 88.4 mm; annulus area, 600.3 mm²) (Figure 1A and B). Transcatheter aortic valve replacement (TAVR) via the transfemoral artery was planned by the cardiology team considering the inoperable condition of the patient.

After achieving femoral access, pre-dilation was performed using a 20-mm Edwards balloon. Thereafter, a 29-mm Sapien S3 prosthesis (Edwards Lifesciences Corporation, Irvine, CA, USA) with 2 mL underfill (+1.6% oversizing) was implanted. However, during valve implantation, supra-annular rupture by the calcified leaflet occurred in the left coronary cusp (Supplementary Video 1). Extracorporeal membrane oxygenation (ECMO) support was provided for the cardiac tamponade and pericardiocentesis was done. Because the post-TAVR CT showed dye leakage at

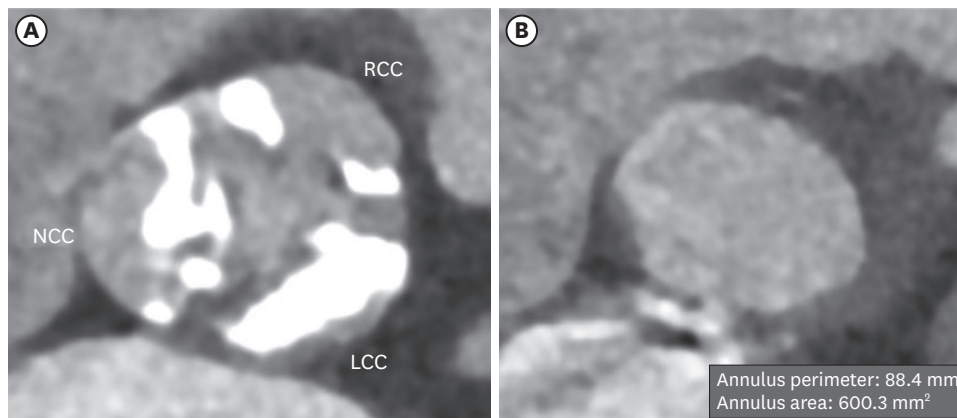


Figure 1. Computed tomography findings of aortic valve. Computed tomography showing heavily calcified leaflets at the sinus Valsalva level (A) and annulus measuring perimeter and area (B). LCC = left coronary cusp; NCC = non-coronary cusp; RCC = right coronary cusp.

Cheol Hyun Lee 
<https://orcid.org/0000-0003-4203-1457>

Funding

The authors received no financial support for the research, authorship, and/or publication of this article.

Conflict of Interest

The authors have no financial conflicts of interest.

Data Sharing Statement

The data generated in this study is available from the corresponding author upon reasonable request.

Author Contributions

Conceptualization: Lee CH; Data curation: Lee HJ, Lee CH, Park HS, Kim IC, Kim JY, Kim JB, Jang WS; Investigation: Lee CH, Lee HJ; Supervision: Lee CH, Hur SH; Visualization: Kim IC, Kim JY; Writing - original draft: Lee HJ, Lee CH; Writing - review & editing: Lee CH, Hur SH.

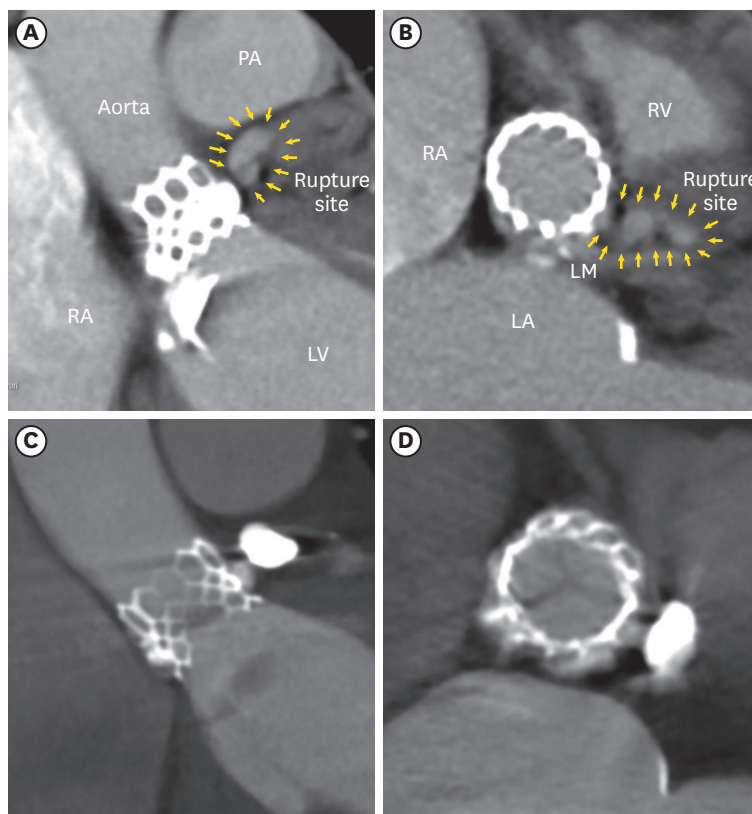


Figure 2. Computed tomography showing the annular rupture on transcatheter aortic valve replacement. Dye leakage is observed in the rupture site on the left coronary cusp side connected to the pericardial space in the perpendicular valve view (A) and en-face valve view (B) (yellow arrows). After coil embolization, no leakage was observed in the perpendicular valve view (C) and in the en-face valve view (D).
 LA = left atrium; LM = left main; LV = left ventricle; PA = pulmonary artery; RA = right atrium; RV = right ventricle.

the rupture site connected to the pericardial space only (Figure 2A and B), heart team decided to proceed with coil embolization.¹⁴⁾ Digital subtraction angiography with a 6-Fr AL2 guiding catheter displayed the rupture site accurately (Figure 3A, Supplementary Video 2). With a Fielder XT wire (Asahi Intecc, Aichi, Japan) and 0.014 Finewire MG microcatheter (Terumo

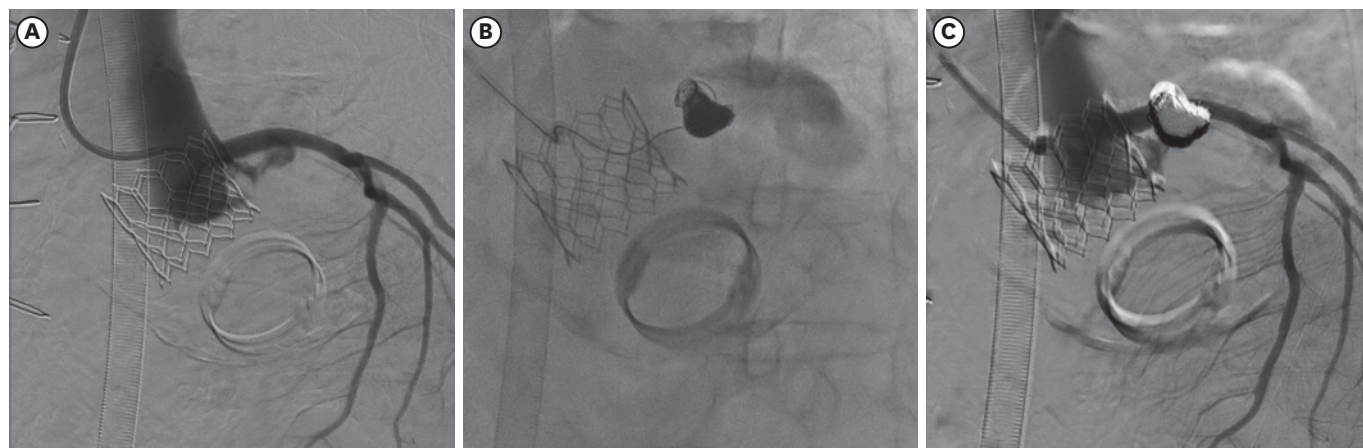


Figure 3. Digital subtraction angiography of annular rupture site. Angiography before coil embolization (A), during coil embolization (B) and after coil embolization (C).

Medical Corp., Somerset, NJ, USA), the narrow, tortuous lesion was penetrated (**Supplementary Video 3**). Successful embolization was performed with detachable coils (Concerto, Medtronic, Inc., Minneapolis, MN, USA) (**Figure 3B, Supplementary Video 4**). Finally, the pericardial drain was tapered and the patient was successfully weaned off ECMO. No dye leakage was observed at the rupture site on the follow-up CT (**Figure 2C and D**).

Written informed consent was obtained from the patient for publication of this article.

SUPPLEMENTARY MATERIALS

Supplementary Video 1

Annular rupture by the calcified leaflet on the left coronary cusp during transcatheter aortic valve implantation.

[Click here to view](#)

Supplementary Video 2

Cineangiography and digital subtraction angiography of the annular rupture site.

[Click here to view](#)

Supplementary Video 3

Penetrating the annular rupture lesion using coronary wire and microcatheter.

[Click here to view](#)

Supplementary Video 4

Embolization of annular rupture site using detachable coil and final digital subtraction angiography.

[Click here to view](#)

REFERENCES

1. Alkhouli M, Carpenter E, Tarabishy A, Sengupta P. Annular rupture during transcatheter aortic valve replacement: novel treatment with amplatzer vascular plugs. *Eur Heart J* 2018;39:714-5.
[PUBMED](#) | [CROSSREF](#)
2. Azarrafiy R, Albuquerque FN, Carrillo RG, Cohen MG. Coil embolization to successfully treat annular rupture during transcatheter aortic valve replacement. *Catheter Cardiovasc Interv* 2018;92:1205-8.
[PUBMED](#) | [CROSSREF](#)
3. Coughlan JJ, Kiernan T, Mylotte D, Arnous S. Annular rupture during transcatheter aortic valve implantation: predictors, management and outcomes. *Interv Cardiol* 2018;13:140-4.
[PUBMED](#) | [CROSSREF](#)
4. Pasic M, Unbehaun A, Buz S, Drews T, Hetzer R. Annular rupture during transcatheter aortic valve replacement: classification, pathophysiology, diagnostics, treatment approaches, and prevention. *JACC Cardiovasc Interv* 2015;8:1-9.
[PUBMED](#) | [CROSSREF](#)