

Can Appropriate Systemic Treatment Help Protect the Cornea in Patients With Rheumatoid Arthritis? A Multidisciplinary Approach to Autoimmune Ocular Involvement

Manuel J. Amador-Patarroyo, MD,* Emilio Jalil-Florencia, MD,* Oscar Otero-Marquez, MD,*
Nicolás Molano-Gonzalez, MSc,† Ruben D. Mantilla, MD,† Adriana Rojas-Villarraga, MD,†
Juan-Manuel Anaya, MD, PhD,† and Carmen Barraquer-Coll, MD*

Purpose: To correlate rheumatologic with ophthalmic and laboratory findings in patients with rheumatoid arthritis (RA) to identify what effect these have on development of ocular disease.

Methods: This is a cross-sectional study of 172 eyes of 86 patients with RA. Patients were examined by a group of rheumatologists. Sociodemographic, clinical, and laboratory data were collected. All patients underwent complete ophthalmologic examination including corneal topography and endothelial cell count.

Results: There was no significant correlation between RA-negative prognostic indicators (NPIs) and pathologic corneal findings. Patients using disease-modifying antirheumatic drugs (DMARDs) and antimetabolic drugs had greater corneal volumes (mean difference 8.51 mm³, 90% confidence interval [CI], 3.98–13.04, $P = 0.004$; and 2.24, 90% CI, 0.32–4.54, $P = 0.048$, respectively). Patients using azathioprine had lower endothelial cell counts compared with those using other drugs (mean difference 180 cells/mm², 90% CI, 69–291, $P = 0.008$). Patients using biologic DMARDs had better tear osmolarity values (between 280 and 300 mOsm/L) than patients not using them (mean difference 14.3 mOsm/L, $P = 0.022$). There was no correlation between NPIs of RA and positive keratoconus screening indices (Spearman correlation OD -0.013 , $P = 0.91$; OS -0.033 , $P = 0.76$).

Conclusions: There was no clear correlation between RA-NPIs and pathologic corneal findings in our study. DMARDs treatment may help maintain corneal integrity in our patients and prevented collagenolytic manifestations of RA. Other medications such as azathioprine should be used carefully, as endothelial damage may potentially occur.

Key Words: cornea, rheumatoid arthritis, keratoconus, collagenolysis, disease-modifying antirheumatic drugs

(*Cornea* 2018;37:235–241)

Rheumatoid arthritis (RA) is a common and chronic systemic inflammatory disease that primarily involves joints. Extra-articular manifestations are also observed in the eye.^{1,2}

One of the most frequent eye complications of RA besides keratoconjunctivitis sicca (KCS) is corneal inflammatory involvement. “Corneal melting” or “corneal melt” refers to clinical characterization of collagen breakdown initiated by significant inflammation in the corneal extracellular matrix. This pathologic process may be also known as collagenolysis. Collagenolysis may be due in part to upregulation of proinflammatory cytokines; these molecules subsequently trigger corneal cells to produce a number of proteolytic enzymes that can effectively degrade the extracellular matrix.³

Other manifestations of corneal inflammation in RA are stromal keratitis, sclerosing keratitis, keratolysis, marginal furrowing or guttering, and peripheral ulcerative keratitis (PUK).⁴ The most common form of corneal melt in RA is PUK. This disorder is not exclusive to RA and may be observed in other systemic immune-mediated conditions, such as vasculitis (ie, granulomatosis with polyangiitis). In PUK, adjacent conjunctival and episcleral tissues reveal an abundance of lymphocytes and macrophages.⁵ These cells, particularly macrophages, may release significant quantities of proinflammatory cytokines and proteases that can exacerbate stromal breakdown.

The importance of early diagnosis and proper treatment of ophthalmic disease in patients with RA cannot be over-emphasized because it permits timely management of

Received for publication March 5, 2017; revision received October 3, 2017; accepted October 5, 2017. Published online ahead of print November 22, 2017.

From the *Escuela Superior de Oftalmología, Instituto Barraquer de America, Bogotá, Colombia; and †Center for Autoimmune Diseases Research (CREA), School of Medicine and Health Sciences, Universidad del Rosario, Bogotá, Colombia. Dr. Rojas-Villarraga is now with Artmedica IPS, Bogotá, Colombia. Supported by Escuela Superior de Oftalmología Instituto Barraquer de America, Bogotá, Colombia.

Juan-Manuel Anaya, MD, PhD, and Carmen Barraquer-Coll, MD contributed equally and should be considered co-lead authors.

The authors have no conflicts of interest to disclose.

Reprints: Manuel J. Amador-Patarroyo, MD, Escuela Superior de Oftalmología Instituto Barraquer de America, Calle 100 No. 18A–51, Bogotá, Colombia 110221 (e-mail: manueljose8@hotmail.com).

Copyright © 2017 The Author(s). Published by Wolters Kluwer Health, Inc. This is an open-access article distributed under the terms of the Creative Commons Attribution-Non Commercial-No Derivatives License 4.0 (CCBY-NC-ND), where it is permissible to download and share the work provided it is properly cited. The work cannot be changed in any way or used commercially without permission from the journal.

potentially serious sight-threatening complications. The presence of ocular disease may also be an indication of ongoing systemic disease activity.⁶

The purpose of our study was to characterize a Latin American population with RA including sociodemographic, clinical, laboratory, and imaging data to identify which of these variables act as negative prognostic indicators (NPIs) and which of them are protective for development of ocular disease. Likewise, we hypothesized that appropriate systemic treatment can protect the cornea in patients with RA.

Previous studies do not differentiate the manifestations caused by RA from those caused by other overlapping autoimmune diseases such as systemic lupus erythematosus (SLE) and Sjögren syndrome (SS). By having teams of both rheumatologists and ophthalmologists, we were able to have a sample of exclusive RA patients with no other overlapping autoimmune disorders that commonly affect the ocular surface. To our knowledge, this is the first project that has taken this into account. In addition, RA may also generate morphologic changes in the cornea changing the refraction of the eye. It has been theorized that chronic epitheliopathy associated with RA increases risk for keratoconus.⁷ For this reason, topographic keratoconus screening indices were also analyzed in this study.

MATERIALS AND METHODS

Examination

Patients were first examined by the rheumatology team where clinical variables, systemic treatment, and laboratory data were collected. This included negative prognostic factors such as anticyclic citrullinated peptide, rheumatoid factor, antinuclear antibody, disease activity score (DAS28), extra-articular involvement, bone erosions, and number of joints involved.⁸ They were then referred to the Cornea and External Disease ophthalmology department of the Barraquer Clinic in Bogota, Colombia. All patients underwent standard refraction with best-corrected visual acuity, slit-lamp biomicroscopy with funduscopy examination, dry eye evaluation with osmolarity testing, and corneal topography using a Pentacam high-resolution rotating Scheimpflug imaging system. Corneal parameters collected included pachymetry (central, apex, and thinnest points), corneal volume, and corneal endothelial cell count.

Study Population

This was a cross-sectional study in which 86 patients with RA were included. All patients with RA were referred from the Center for Autoimmune Diseases Research in Bogota, Colombia, and met both RA criteria from 1987 of the American College of Rheumatology (ACR) and 2010 criteria of the ACR/European League Against Rheumatism.^{9,10} Patients with SS, one of the most common associated autoimmune diseases, were excluded from the analysis. The exclusion was made following the American-European Consensus Group Criteria,¹¹ which requires positive minor salivary gland biopsy. Patients with SS were not considered in

the study because we considered that extreme dry eye could alter the corneal parameters.¹² Patients with other associated autoimmune diseases such as SLE and autoimmune thyroid disease were also excluded from the analysis.

One hundred seventy-two eyes of 86 subjects were enrolled. Exclusion criteria were previous ocular surgery including refractive and cataract surgery, ocular infection, and age younger than 18 years. All patients with RA provided written informed consent, and the study was approved by the local ethics committee and conducted according to the Declaration of Helsinki.

Statistical Analysis

Rheumatologic data were analyzed with ophthalmologic data. Bivariate analyses of some outcomes of interest were performed to find marginal associations. For continuous versus categorical variables, the Kruskal–Wallis test was used, whereas for categorical versus categorical variables, the Spearman correlation was used. Because we included both eyes from the same patient in our analysis, every statistical association between measurements was applied to both eyes. Classic methods such as linear regression study only statistical associations between one dependent variable (ie, only 1 eye) and other covariates. However, in this analysis, we needed to test statistical associations between 2 dependent variables (both eyes) and other covariates (ie, treatment, corneal volume, endothelial cell count, etc.). For that reason, multivariate analysis of variance (MANOVA)¹³ was used to fit linear models for these multivariate outcomes and adjust for possible confounders. MANOVA is simply an ANOVA with several dependent variables. This extended regression model accounts for correlation among dependent variables (ie, corneal volume for right and left eyes, which are highly correlated) and determines statistical associations for the set of dependent variables. However, classic MANOVA assumes multinormal distribution for error's distribution; therefore, permutational MANOVA was used because it is more flexible and does not rely on multivariate normal assumptions. 100,000 permutations were used for the analyses. All statistical analyses were performed using R version 3.3.1.

RESULTS

A total of 172 eyes of 86 patients with RA were included in this study. The ophthalmologic data, demographic/rheumatologic data, and treatment used by patients are shown in Tables 1–3, respectively.

There was no significant association between NPI of RA and positive pathologic corneal findings. We considered 6 NPIs on the analysis: 1) long disease duration, 2) number of joints involved, 3) positive anticyclic citrullinated peptide, 4) presence of bone erosions on x-ray examination, 5) high titers of rheumatoid factor, and 6) a high mean DAS28. Table 4 summarizes the correlations between NPIs and corneal parameters. Patients with only 1 and up to 6 simultaneous NPIs were analyzed, but no correlation was found with pathologic corneal findings (Spearman correlation test $P > 0.05$).

TABLE 1. Ophthalmologic Data (n = 172)

	OD, Mean (SD)	OS, Mean (SD)
Corneal power		
K1	44.4 (1.75)	44.37 (1.5)
K2	43.3 (1.32)	43.5 (1.4)
Km	43.8 (1.45)	43.97 (1.33)
Pachymetric measurements and osmolarity		
Apex (µm)	537 (33.9)	535 (32.2)
Thinnest (µm)	530.3 (34.13)	527 (33.2)
Corneal volume (mm ³)	58.9 (3.7)	58.8 (3.6)
Endothelial cell count (cells/mm ²)	2633 (257)	2655 (255)
Tear osmolarity (mOsm/L)	312 (19.4)*	
	OD, n (%)	OS, n (%)
Ocular surface		
Mild keratitis	14 (8.1)	15 (8.7)
Moderate keratitis	6 (3.4)	2 (1.1)
Severe keratitis	3 (1.7)	4 (2.3)
Corneal scar	7 (4)	6 (3.4)
Scleritis	1 (0.5)	1 (0.5)
Meibomitis	69 (40.1)	56 (32.5)

*Tear osmolarity was measured only in the right eye.
K1, corneal power of the flat axis; K2, corneal power of the steep axis; Km, mean corneal power.

Permutational MANOVA revealed an association between the use of antimalarial drugs and a higher corneal volume among patients with RA in both eyes, which is persistent after adjusting for age in the model. In general, patients using antimalarial drugs had a higher corneal volume (59.25 mm³) compared with those without these drugs (57.15 mm³) [mean pooled difference across both eyes between drug use and no use: 2.24, 90% confidence interval (CI) 0.32–4.54, *P* = 0.048] (Fig. 1). A similar pattern was

TABLE 2. Demographic and Rheumatologic Data (n = 86)

	n (%)
Sex (female/male)	68 (79)/18 (21)
Presence of bone erosions*	33 (38)
No. patients with positive RF	79 (92)
No. patients with positive anti-CCP*	51 (59)
No. patients with positive ANA	30 (34)
	Mean (SD)
Age, yrs	56 (12.7)
Age at onset of RA, yrs	42 (13.8)
Disease duration, yrs*	11.9 (9.3)
RF titers*	231 (302)
Anti-CCP titers	226 (216)
No. joints involved*	7 (2.3)
DAS28*	4.72 (1.62)

*Six variables considered as NPIs.
ANA, antinuclear antibody; anti-CCP, anticyclic citrullinated peptide; RF, rheumatoid factor.

TABLE 3. Number of Patients Using Treatment (n = 86)

	n (%)
MTX only	37 (43)
MTX with other DMARD	26 (19)
LFN	21 (24)
Azathioprine	7 (8)
Corticosteroids	38 (44)
Antimalarials	43 (44)
Anti-TNF	34 (39)
Abatacept	21 (39)
Tocilizumab	8 (9)

Anti-TNF, anti-tumor necrosis factor.

observed in the case of disease-modifying antirheumatic drugs (DMARDs) and corneal volume (mean pooled difference across both eyes between drug use and no use: 8.51, 90% CI, 3.98–13.04, *P* = 0.004) (Fig. 1). Increased corneal volume and thicker pachymetry at the apex and thinnest points were observed in both eyes for DMARD users. However, this result should be taken with care since only 2 patients did not take any DMARDs. For that reason, we did an additional analysis differentiating the DMARDs used. The most common drug used was methotrexate (MTX). The use of only MTX was named regimen 1. The patient using MTX with other DMARDs such as leflunomide (LFN) and sulfasalazine was named regimen 2. At the end, there was no significant difference between the use of both regimens (*P* = 0.11).

Permutational MANOVA was used to evaluate the effect of immunosuppressant drugs such as azathioprine and cyclophosphamide. Age-adjusted corneal parameters including endothelial cell count were taken into account. The results obtained showed no significant interaction

TABLE 4. NPI and Pachymetric Parameter Associations

	Association	<i>P</i>
Age	0.006	0.95
Sex (female/male)	−0.176 (−0.826, 0, 473)	0.498
Pachymetric parameters		
Thinnest point OD	0.07	0.502
Thinnest point OS	0.088	0.436
Apex OD	0.1	0.376
Apex OS	0.089	0.431
Corneal volume OD	−0.007	0.951
Corneal volume OS	−0.06	0.62
Endothelial cell count OD	0.096	0.41
Endothelial cell count OS	0.12	0.34
ART-max OD	−0.013	0.91
ART-max OS	−0.33	0.76

Associations between age, sex, corneal pachymetric parameters, and NPIs are shown in the second column. For continuous variables, the Spearman correlation coefficient is presented as an association measure. For categorical variables (ie, sex), the mean difference of NPI among groups is presented as an association measure. *P* values of the statistical associations are presented in the third column.

ART-Max, Ambrósio relational thickness index.

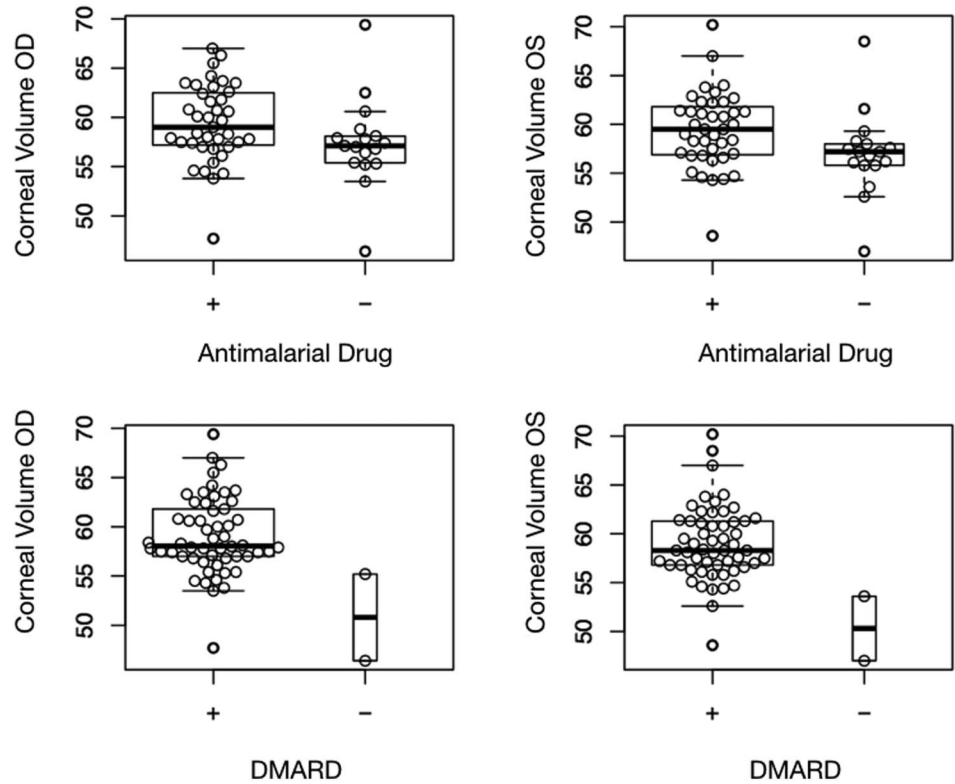


FIGURE 1. Boxplots of corneal volumes in both eyes by consumption of antimalarial and DMARDs.

between age, corneal parameters, and immunosuppressant drug use ($P = 0.44$). Patients using azathioprine had lower endothelial cell counts compared with those not using azathioprine (mean pooled difference across both eyes: 180 cells/mm², 90% CI, 69.01–291.24, $P = 0.008$). As expected, the endothelial cell count decreased as age increased (5.27 cells/mm² per yr, 90% CI, 2.56–7.99, $P = 0.00083$). There was no significant effect of age on any of the pachymetric readings or the corneal endothelial cell count (Fig. 2), suggesting that the use of azathioprine might be an independent factor causing a lower endothelial cell count.

Use of biologic DMARDs was not strongly associated with negative or positive corneal findings, although, abatacept and tocilizumab were associated with reduction in tear osmolarity in the right eye (mean difference of 14.3 mOsm/L, Kruskal–Wallis $P = 0.022$). Patients using this particular biologic treatment had a more normal tear osmolarity (between 288 and 300 mOsm/L) as measured by the TearLab Osmolarity Test.

Finally, our analyses did not show any clear association between NPI of RA and positive topographic keratoconus screening index Ambrósio relational thickness (ART-Max) (Spearman correlation test $P > 0.05$) (Table 4). Only 4

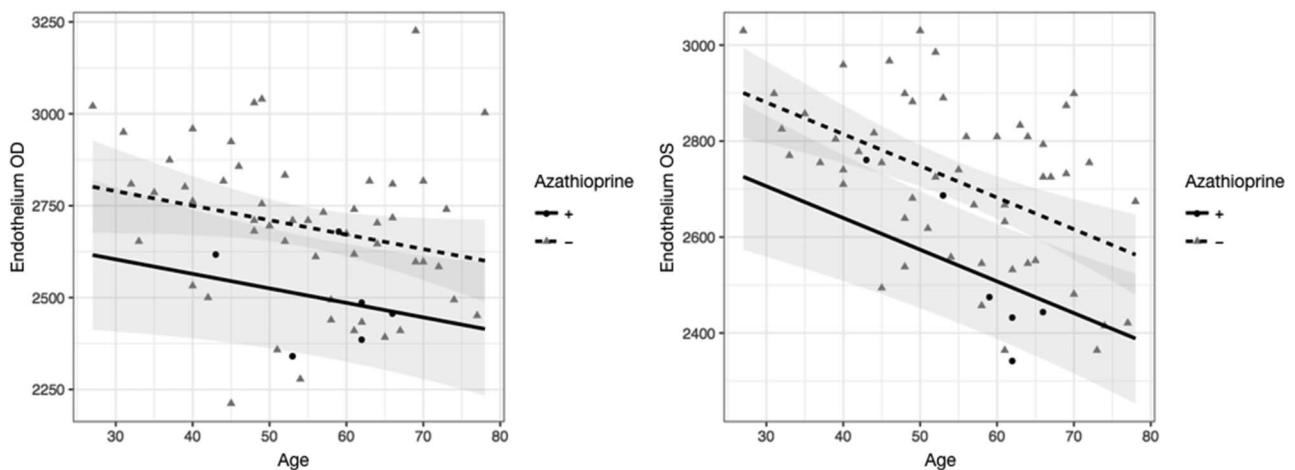


FIGURE 2. Scatter plots and linear fits of endothelial cell count in both eyes vs. age, grouped by Azathioprine use.

patients were diagnosed as having some level of corneal ectasia. This prevalence was not considered higher than the normal population.^{14,15}

DISCUSSION

Negative Prognostic Factors and Corneal Findings

Our results indicate that patients who are well controlled may be protected from the chronic inflammatory processes of RA, especially from the extra-articular manifestations. We correlated all known NPIs for RA, with abnormal findings in the cornea. There was no strong association among these factors and pathologic corneal findings. Many studies have correlated the presence, duration, and degree of activity of RA, with changes in corneal parameters. The results vary between the different studies. Özcürü et al¹⁶ studied 104 eyes of patients with RA. No statistically significant differences were found between measurements of central corneal thickness, nor in keratomeries when comparing patients with RA with patients without RA. This study also showed that the central corneal thickness was not related to the degree of DAS28 or to the duration of the disease. Villani et al¹ reported a significantly thinner corneal thickness in patients with RA compared with non-AR subjects. Gunes et al¹² showed that patients with RA have thinner central and peripheral corneal thickness and lower corneal volume than the non-RA population ($P < 0.001$). No statistically significant relationships were found between the corneal parameters and the clinical variables of RA. Jayaraj et al¹⁷ showed no statistically significant association of ocular manifestations with the severity of RA (DAS28), nor with disease duration.

DMARDs, Antimalarial Drugs, and the Cornea

In our study, patients receiving DMARDs such as MTX, LFN, and hydroxychloroquine had a higher corneal volume. Patients taking MTX, LFN, or both had thicker pachymetry at the thinnest and central points of the cornea compared with patients receiving another type of medication, suggesting that the use of DMARDs could have a protective effect in the development of corneal disease, possibly because of inhibition of leukocyte replication and release of inflammatory mediators on the ocular surface protecting against collagenolysis.

DMARDs are a category of drugs defined by their use in RA to slow down disease progression. DMARDs can be further subdivided into traditional small molecular mass drugs synthesized chemically (antimalarial drugs such as hydroxychloroquine, MTX, and LFN) and newer “biological” agents produced through genetic engineering (adalimumab and etanercept).

One of the most well-known drugs is MTX, which is a folic acid analog and an inhibitor of dihydrofolate reductase, the enzyme responsible for conversion of dihydrofolate to tetrahydrofolate. This action inhibits production of thymidylate, which is essential for DNA replication.¹⁸ As such, MTX inhibits rapidly dividing cells, such as leukocytes, producing an anti-inflammatory effect. This drug has been used to treat various ocular inflammatory diseases, including vasculitis,

panuveitis, intermediate uveitis, vitritis, scleritis, orbital pseudotumor, myositis, and sarcoid-associated panuveitis.¹⁹ Another DMARD often used in clinical practice is LFN, which inhibits pyrimidine synthesis by inhibiting dihydroorotate dehydrogenase.²⁰ LFN was initially registered as a monotherapy for the treatment of active RA and several clinical trials, and observational studies have demonstrated that it has equivalent efficacy and tolerability to other DMARDs, resulting in control of disease activity, improvement in functional disability, and retarding radiographic progression.²¹ Also, a recent study by Hodkinson et al²² indicated that combination of LFN/MTX was effective in most patients in this cohort who failed other combination synthetic DMARDs, concluding that in a setting where biologic DMARDs are not readily accessible, combination of LFN/MTX is a cost-effective approach.

Azathioprine and Endothelial Cell Damage

In our study, patients using azathioprine had decreased endothelial cell count in both eyes. This association may infer a toxic effect in the corneal endothelium in patients; however, much information is still unknown in relation to azathioprine toxicity. Additional studies with dose-dependent factors and therapy duration may be recommended. Given that other alternatives exist to treat the disease, ocular toxicity of this drug should be considered when treating RA with corneal involvement.

Azathioprine is a purine nucleoside analog. Its mechanism of action is to interfere with adenine and guanine ribonucleotides by suppression of inosinic acid, which interferes with DNA replication. It is commonly used as an immunosuppressant after organ transplantation and in patients with autoimmune disease. In ophthalmology, this drug has been used for the treatment of uveitis. A common side effect of azathioprine includes bone marrow suppression. Another serious adverse effect reported is hepatotoxicity, which is believed to occur in less than 2% of patients. For this reason, liver function tests should be performed every 12 weeks.²³

Liver toxicity is considered to be secondary to hepatocyte or endothelial cell damage. Microscopic studies of the liver have demonstrated alteration to sinusoidal endothelial cells. Deleve et al²⁴ showed how azathioprine has been linked to liver lesions on long-term immunosuppression after kidney or liver transplantation. Their study explained the role of glutathione and its function as a cofactor for detoxification of toxic compounds. Azathioprine depletes glutathione, which causes cell death and mitochondrial injury.²⁵ Corneal endothelium is in charge of transporting water from the stroma to the anterior chamber. This is necessary to maintain nutrient homeostasis and a transparent cornea. These cells are metabolically very active and have large numbers of mitochondria, consistent with their need to move water efficiently.²⁶

Biologic DMARD Therapy and Tear Osmolarity

This study showed that the use of abatacept and tocilizumab had statistically significant association with better

values of tear osmolarity. Tear osmolarity is considered normal between 280 and 300 mOsm/L. Patients using either of these 2 drugs had more normal osmolarity compared with patients receiving another type of medication. One of the most important ocular manifestations of RA is KCS, which usually presents with high tear osmolarity. KCS may be considered an extra-articular manifestation inherent to the disease, even when we rule out SS, which may confound our results.²⁷ Good control of KCS using this type of medication may mean better control of the systemic disease.

The immune response in RA is mediated by factors of innate immunity [increase of HLA-DR molecules and costimulators in professional APCs (dendritic cells) and conjunctival epithelial cells] and factors of adaptive immunity [tumor necrosis factor alpha (TNF-alpha), interferon gamma, interleukin-6 (IL-6) and IL-1 β , and metalloproteinases]. Current treatments are directed toward these factors. The treatment of RA includes nonsteroidal anti-inflammatory drugs, corticosteroids, and DMARDs. Clinical evidence supports newer drugs called biologic DMARDs. The most commonly used biologic DMARDs are infliximab, etanercept, abatacept, adalimumab, and tocilizumab. The mechanism of action of infliximab, adalimumab, and etanercept is through TNF inhibition. Abatacept prevents T-cell activation, and tocilizumab is an IL-6 inhibitor. Abatacept is a fusion protein produced by recombinant DNA. It inhibits T-cell activation by binding to cluster differentiation CD-80 and CD-86, inhibiting a costimulatory pathway required for full activation of T lymphocytes. Adalimumab is a human monoclonal antibody that binds to the inflammatory cytokine TNF, neutralizing its biological function and modifying the inflammatory process. Tocilizumab is a monoclonal humanized, antihuman IL-6 receptor (IL-6R) antibody; it binds to IL-6R, inhibiting IL-6-mediated signaling. The use of biologic DMARDs is superior to placebo in treating systemic manifestations of RA.²⁸ Adalimumab, etanercept, and tocilizumab had comparable efficacy toward juvenile idiopathic arthritis.²⁹ Anti-TNF treatment is highly effective in refractory inflammatory uveitis. Infliximab and adalimumab seem to be equivalent in terms of efficacy.³⁰ Evidence from observational studies suggests that biologic DMARDs can improve uveitis, and adalimumab seems to be more effective than etanercept in improving intraocular inflammation.²⁸

RA and Keratoconus

Unlike previous reports, there was no clear association between RA NPI and positive keratoconus indices such as ART-Max. One possible reason was that our patients received optimal pharmacological treatment, and in general had a controlled systemic disease, and were strictly followed by their rheumatologist. Another possibility is that by excluding patients with overlapping SS and SLE, we are also filtering additional risk factors that may contribute to the development of KCS (ie, dry eye and vasculitis).

Keratoconus is a noninflammatory, progressive, thinning disorder of the cornea, which leads to progressive mixed myopic and irregular astigmatism. The immune system has been implicated in the pathogenesis of KC because thinning

of the cornea seems to be associated with increased levels of intracorneal inflammatory mediators such as IL-1.^{31,32} Moreover, allergic conjunctivitis, which results in chronic inflammation of the ocular surface, has long been associated with KC.³³ On the other hand, in a retrospective study by Nemet et al,⁷ a strong association between RA and KC was reported. They point out that chronic epitheliopathy associated with RA might be the cause of the increased risk of KC reported.⁷

Strengths of this study are that we included patients with RA without other overlapping autoimmune disorders. Another strength is that we were able to do a very specific type of analysis that takes into account each eye as a dependent variable (permutational MANOVA), taking care of the issue that both eyes of each patient are highly correlated. Limitations include its retrospective nature. Although we did collection and classification of the medications the patients were using, therapies recorded and used in the analysis were the ones taken by the patient for the past year. During this period, patients had multiple flare-ups as shown by the DAS28, and these medications were used to control the disease during this period. Nonetheless, the data of the whole duration of the therapy during the disease lifetime and the exact time of usage before this last year were not considered reliable and for that reason were not taken into account.

The rationale of our study was to determine whether there is clinical correlation between rheumatologic variables and ophthalmic findings. This kind of approximation is unique to this study considering the number of variables that were analyzed from each area and how patients with only RA were included. Although we did not find any correlation between NPI of RA and pathologic findings on the cornea, we did find a possible protective effect of some of the medications. This study demonstrated the importance of the use of DMARDs to control corneal disease in patients with several NPI. Proper and timely treatment may help maintain corneal integrity in patients with collagenolytic manifestations of RA. Our findings also support a possible toxic effect of azathioprine on the corneal endothelium. However, additional studies with pharmacodynamic information are needed to investigate further. Exciting new discoveries have shown promise in the treatment of patients with RA and ocular surface disease. For this reason, we are encouraged to keep searching for small manifestations in different types of population.

ACKNOWLEDGMENTS

The authors thank all the patients who participated in this study and their colleagues Sergio Antonio Arrascue, Alicia Montoya, Ana Paola Arciniegas, Gisella Santaella, and Clara Lopez de Mesa for their fruitful contributions.

REFERENCES

1. Villani E, Galimberti D, Viola F, et al. Corneal involvement in rheumatoid arthritis: an in vivo confocal study. *Invest Ophthalmol Vis Sci.* 2008;49:560–564.
2. Hamideh F, Prete PE. Ophthalmologic manifestations of rheumatic diseases. *Semin Arthritis Rheum.* 2001;30:217–241.
3. Riley GP, Harrall RL, Watson PG, et al. Collagenase (MMP-1) and TIMP-1 in destructive corneal disease associated with rheumatoid arthritis. *Eye (Lond).* 1995;9:703–718.

4. Yagci A. Update on peripheral ulcerative keratitis. *Clin Ophthalmol*. 2012;6:747–754.
5. Michels ML, Cobo LM, Caldwell DS, et al. Rheumatoid arthritis and sterile corneal ulceration. Analysis of tissue immune effector cells and ocular epithelial antigens using monoclonal antibodies. *Arthritis Rheum*. 1984;27:606–614.
6. Foster CS, Forstot SL, Wilson LA. Mortality rate in rheumatoid arthritis patients developing necrotizing scleritis or peripheral ulcerative keratitis. Effects of systemic immunosuppression. *Ophthalmology*. 1984;91:1253–1263.
7. Nemet AY, Vinker S, Bahar I, et al. The association of keratoconus with immune disorders. *Cornea*. 2010;29:1261–1264.
8. Skapenko A, Prots I, Schulze-Koops H. Prognostic factors in rheumatoid arthritis in the era of biologic agents. *Nat Rev Rheumatol*. 2009;5:491–496.
9. Arnett FC, Edworthy SM, Bloch DA, et al. The American Rheumatism Association 1987 revised criteria for the classification of rheumatoid arthritis. *Arthritis Rheum*. 1988;31:315–324.
10. Aletaha D, Neogi T, Silman AJ, et al. 2010 rheumatoid arthritis classification criteria: an American College of Rheumatology/European League against Rheumatism collaborative initiative. *Ann Rheum Dis*. 2010;69:1580–1588.
11. Daniels TE, Fox PC, Fox RI, et al. Classification criteria for Sjögren's syndrome: a revised version of the European criteria proposed by the American-European Consensus Group. *Ann Rheum Dis*. 2002;61:554–559.
12. Gunes A, Inal EE, Tok L, et al. Evaluation of central and peripheral corneal thicknesses in patients with rheumatoid arthritis. *Arq Bras Oftalmol*. 2015;78:236–240.
13. Anderson MJ. A new method for non-parametric multivariate analysis of variance. *Austral Ecol*. 2001;26:32–46.
14. Kennedy RH, Bourne WM, Dyer JA. A 48-year clinical and epidemiologic study of keratoconus. *Am J Ophthalmol*. 1986;101:267–273.
15. Gokhale NS. Epidemiology of keratoconus. *Indian J Ophthalmol*. 2013;61:382–383.
16. Özcura F, Aktaş S, Özkan Y, et al. Central corneal thickness and corneal curvature in patients with rheumatoid arthritis. *Int Ophthalmol*. 2016;37:159–163.
17. Jayaraj K, Alvin TG, Charles KS, et al. Correlation of ocular manifestations with the duration and activity of disease in patients with rheumatoid arthritis. *Int J Med Sci Public Health*. 2017;6:34–37.
18. Kremer JM. Methotrexate and emerging therapies. *Rheum Dis Clin North Am*. 1998;24:651–658.
19. Shah SS, Lowder CY, Schmitt MA, et al. Low-dose methotrexate therapy for ocular inflammatory disease. *Ophthalmology*. 1992;99:1419–1423.
20. Pinto P, Dougados M. Leflunomide in clinical practice. *Acta Reumatol Port*. 2006;31:215–224.
21. Li EK, Tam L-S, Tomlinson B. Leflunomide in the treatment of rheumatoid arthritis. *Clin Ther*. 2004;26:447–459.
22. Hodkinson B, Magomero KR, Tikly M. Combination leflunomide and methotrexate in refractory rheumatoid arthritis: a biologic sparing approach. *Ther Adv Musculoskelet Dis*. 2016;8:172–179.
23. Jabs DA, Rosenbaum JT, Foster CS, et al. Guidelines for the use of immunosuppressive drugs in patients with ocular inflammatory disorders: recommendations of an expert panel. *Am J Ophthalmol*. 2000 Oct;130:492–513.
24. DeLeve LD, Wang X, Kuhlenkamp JF, et al. Toxicity of azathioprine and monocrotaline in murine sinusoidal endothelial cells and hepatocytes: the role of glutathione and relevance to hepatic venoocclusive disease. *Hepatology*. 1996;23:589–599.
25. Lee AU, Farrell GC. Mechanism of azathioprine-induced injury to hepatocytes: roles of glutathione depletion and mitochondrial injury. *J Hepatol*. 2001;35:756–764.
26. Bourne WM. Biology of the corneal endothelium in health and disease. *Eye (Lond)*. 2003;17:912–918.
27. Tong L, Thumboo J, Tan YK, et al. The eye: a window of opportunity in rheumatoid arthritis? *Nat Rev Rheumatol*. 2014;10:552–560.
28. Shepherd J, Cooper K, Harris P, et al. The clinical effectiveness and cost-effectiveness of abatacept, adalimumab, etanercept and tocilizumab for treating juvenile idiopathic arthritis: a systematic review and economic evaluation. *Health Technol Assess*. 2016;20:1–222.
29. Horneff G, Klein A, Klotsche J, et al. Comparison of treatment response, remission rate and drug adherence in polyarticular juvenile idiopathic arthritis patients treated with etanercept, adalimumab or tocilizumab. *Arthritis Res Ther*. 2016;18:272.
30. Vallet H, Seve P, Biard L, et al. Infliximab versus adalimumab in the treatment of refractory inflammatory uveitis: a multicenter study from the French uveitis network. *Arthritis Rheumatol*. 2016;68:1522–1530.
31. Wilson SE, He YG, Weng J, et al. Epithelial injury induces keratocyte apoptosis: hypothesized role for the interleukin-1 system in the modulation of corneal tissue organization and wound healing. *Exp Eye Res*. 1996;62:325–327.
32. Galvis V, Sherwin T, Tello A, et al. Keratoconus: an inflammatory disorder? *Eye*. 2015;29:843–859.
33. Rahi A, Davies P, Ruben M, et al. Keratoconus and coexisting atopic disease. *Br J Ophthalmol*. 1977;61:761–764.