



## Case report

## Corneal thickness in the case of familial lecithin-cholesterol acyltransferase deficiency

Shinsuke Kinoshita<sup>a,c,\*</sup>, Seiichiro Sugita<sup>b</sup>, Akihiro Yoshida<sup>c</sup><sup>a</sup> MIE Eye Clinic Yokkaichi, 4F Yokkaichi Suwamachi Building, 4-5 Suwamachi, Yokkaichi, Mie, Japan<sup>b</sup> Sugita Eye Hospital, 5-1-30, Sakae, Nagoya Naka-ku, Aichi, Japan<sup>c</sup> National Health Insurance Sakashita Hospital, 722-1, Sakashita, Nakatsugawa, Gifu, Japan

## ARTICLE INFO

## Keywords:

Familial lecithin-cholesterol acyltransferase deficiency  
 Lecithin-cholesterol acyltransferase  
 Corneal opacities  
 Central corneal thickness  
 Optical coherence tomography

## ABSTRACT

**Purpose:** We report our findings of a patient with a definitive diagnosis of familial lecithin-cholesterol acyltransferase deficiency (FLD), whose corneal thickness was measured using swept-source optical coherence tomography (OCT) and who underwent an ophthalmologic therapeutic intervention.

**Observations:** The patient was a 78-year-old Japanese man diagnosed with FLD at the age of 52 years. This was his first ever visit to an ophthalmology clinic. Slit lamp microscopy revealed bilateral diffuse corneal opacities and cataracts, angioid streaks of the retina, and macular atrophy in the fundus. The central corneal thickness, measured with swept-source OCT, was within the normal range in both eyes. Deep lamellar keratoplasty, phacoemulsification, and intraocular lens insertion were performed simultaneously for the left eye. The right eye was treated only using deep lamellar keratoplasty.

**Conclusions and importance:** As seen in patients with fish-eye disease, the central corneal thickness in this patient with FLD was within the normal range. Since FLD is a rare disease, it is essential to collect and examine further data on corneal thickness.

## 1. Introduction

Lecithin-cholesterol acyltransferase (LCAT) is an enzyme found in the blood that plays a role in the esterification of free cholesterol (FC) in lipoproteins.<sup>1</sup> Almost all the cholesterol ester present in the serum is thought to be produced by LCAT; therefore, this protein plays a very important role in lipid metabolism.<sup>1</sup> Familial LCAT deficiency (FLD) (MIM # 245900) and fish-eye disease (FED) (MIM # 136120), which causes corneal opacities, are known as congenital diseases caused by abnormalities in the *LCAT* gene.<sup>1</sup> FLD is a rare disease that has been documented in approximately 30 families worldwide, including some in Japan, since its first report by Gjone and Norum<sup>2</sup> in 1968. The main symptoms of this disease are accumulation of abnormal lipids in various organs, corneal opacities, normochromic anemia, and renal impairment caused by abnormal LCAT function.<sup>3</sup>

Although opacities are present throughout the cornea, they are concentrated near the corneal limbus.<sup>4</sup> The cornea of patients with FLD contains large amounts of FC and phospholipids, as confirmed in corneas extracted from patients with FLD.<sup>5</sup> Both FLD and FED are genetic abnormalities of the *LCAT* gene, which is located on the long arm of

chromosome 16 (16q22); the phenotype differs, depending on differences in LCAT activity.<sup>1</sup> Specifically, LCAT activity is roughly divided into  $\alpha$ -LCAT, which acts on high-density lipoproteins (HDLs), and  $\beta$ -LCAT, which acts on very low- and low-density lipoproteins. Patients with FLD have both  $\alpha$ -LCAT and  $\beta$ -LCAT deficiency, whereas those with FED have selective deficiency of  $\alpha$ -LCAT.<sup>1</sup> Therefore, LCAT activity is partially retained in individuals with FED compared to those with FLD. Furthermore, the characteristic normochromic anemia and renal impairment observed in FLD are not observed in FED.<sup>1</sup> Corneal thickness in FED, measured with optical coherence tomography (OCT), is known to be within the normal range.<sup>6–8</sup> Reports on corneal thickness in FLD indicate that the corneal thickness is within the normal range when measured with slit lamp microscopy<sup>4</sup> but increased when measured with ultrasound pachymetry.<sup>9</sup>

As far as we could ascertain, there are no reports that have evaluated the corneal thickness in FLD using OCT. Therefore, the effect of LCAT activity on corneal thickness is unknown. In this study, we used swept-source OCT to measure corneal thickness in a patient<sup>10</sup> who was definitively diagnosed with FLD, following which we performed ophthalmologic therapeutic intervention. Herein, we provide a report of

\* Corresponding author. MIE Eye Clinic Yokkaichi 4F Yokkaichi Suwamachi Building, 4-5 Suwamachi, Yokkaichi, Mie, 510-0085, Japan.

E-mail address: [s.kinoshita@mie-eyeclinic.com](mailto:s.kinoshita@mie-eyeclinic.com) (S. Kinoshita).

<https://doi.org/10.1016/j.ajoc.2021.101211>

Received 3 August 2020; Received in revised form 14 May 2021; Accepted 20 September 2021

Available online 21 September 2021

2451-9936/© 2021 The Authors.

Published by Elsevier Inc.

This is an open access article under the CC BY-NC-ND license

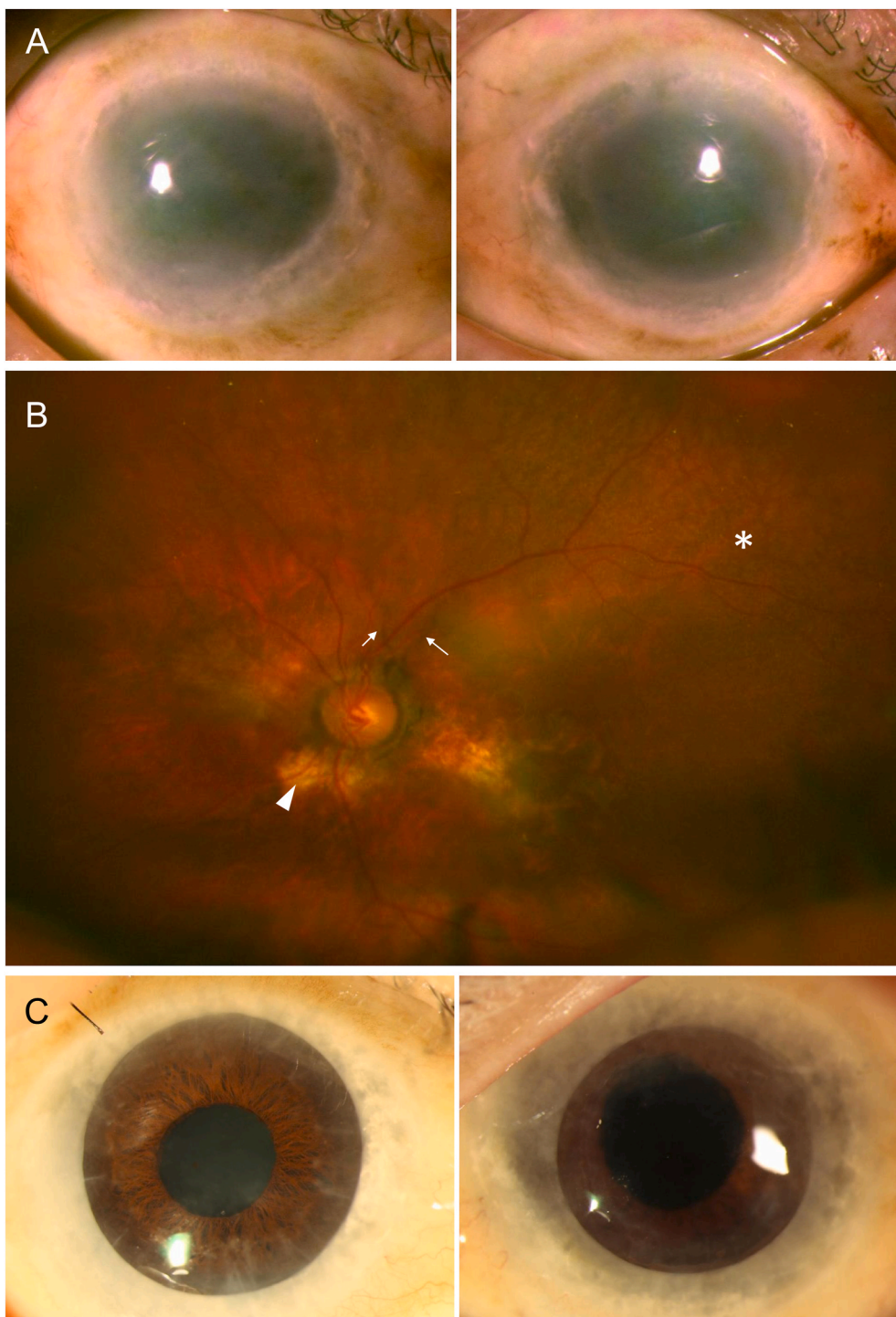
(<http://creativecommons.org/licenses/by-nc-nd/4.0/>).

our findings. This is the first study to report on the corneal thickness in a patient with FLD using OCT. Corneal thickness in FLD is still uncertain, and this necessitates its evaluation.

## 2. Case report

This study was approved by the Institutional Review Board of Sakashita Hospital and conducted according to the Helsinki Declaration of 1964 and its later amendments. Written informed consent to undergo the procedure described here was obtained from the patient. The patient was a 78-year-old Japanese man who was diagnosed with FLD at the age

of 52 years.<sup>10</sup> He had a missense mutation in exon 6 of the *LCAT* gene (p. Thr321Met).<sup>11</sup> In their previous study,<sup>10</sup> internal examination was performed to confirm the diagnosis of FLD; however, ophthalmologic evaluation was not performed. The patient visited the internal medicine department as an outpatient until 54 years of age; thereafter, he discontinued the outpatient visits of his own accord. A detailed family history had already been taken<sup>10</sup> and revealed that the patient's brother had undergone bilateral corneal transplantation.<sup>12</sup> This time, the patient visited the Department of Ophthalmology at Sakashita Hospital after becoming aware of reduced visual acuity. This was his first ever visit to an ophthalmology clinic. His counting fingers visual acuity was



**Fig. 1.** Ophthalmological examinations findings of a 78-year-old Japanese man with FLD. a) Slit lamp microscopy findings revealed diffuse corneal opacities in both eyes, with a particularly high concentration of opacities near the corneal limbus. b) Fundus findings (left eye) showed irregular radial lines spreading from the optic nerve head (arrow), chorioretinal atrophy (arrow-head), and peau d'orange (\*). c) Post-operative findings 20 months after surgery. Corneal transparency was maintained in both eyes. (For interpretation of the references to colour in this figure legend, the reader is referred to the Web version of this article.)

15 cm in the right eye and 20 cm in the left eye. The intraocular pressure was 12 mmHg in the right eye and 14 mmHg in the left eye. Slit lamp microscopy revealed diffuse corneal opacities in both eyes and a particularly high concentration of opacities near the corneal limbus (Fig. 1a). It was not possible to measure the number of corneal endothelial cells due to severe corneal opacities. The severity of cataracts in both the eyes was grade III according to the Emery-Little classification; moreover, angioid streaks of the retina and macular atrophy were observed in the fundus of both eyes (Fig. 1b). Deep lamellar keratoplasty, phacoemulsification, and intraocular lens insertion were performed simultaneously for the left eye. The right eye was treated only with deep lamellar keratoplasty (Fig. 1c). Corrected visual acuity (logarithm of the minimum angle of resolution [logMAR] 20 months after the surgery was 1.7 for the right eye and 1.0 for the left eye.

### 3. Anterior segment optical coherence tomography findings

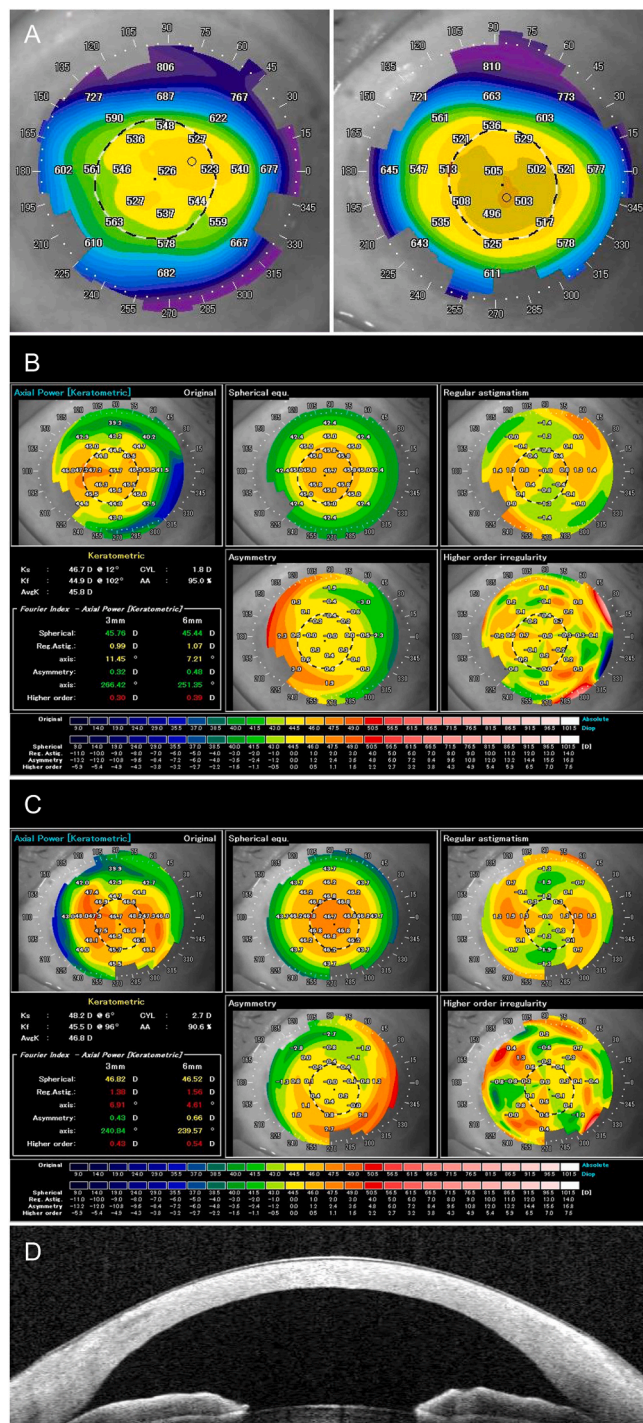
Corneal thickness mapping using swept-source OCT (SS-1000 CASIA, axial/transverse resolution of 6 mm/16 mm, respectively, with a scanning speed of 30,000 A-scans/second and a scan beam wavelength of 1.310 nm; Tomey Corporation, Aichi, Japan) revealed a central corneal thickness of 526 μm for the right eye and 505 μm for the left eye (Fig. 2a). Upon Fourier analysis, a higher-order abnormality, specifically an irregular astigmatism index, was observed in both eyes (Fig. 2b and c). Neither eye had defects in the Bowman membrane or the corneal stroma, and a uniformly high reflection was observed across the entire corneal stroma (Fig. 2d).

### 4. Discussion

This report describes the case of a patient with FLD whose corneal thickness measurements were evaluated using swept-source OCT. Although the patient had corneal opacities and angioid retinal streaks, the corneal thickness measurements were within the normal limits.

When using ultrasound pachymetry and OCT to compare the corneal thickness in normal eyes in Japanese people, ultrasound pachymetry tends to measure the cornea as approximately 10 μm thicker than OCT does<sup>13</sup>; however, the reason for this phenomenon is unclear.<sup>14</sup> Corneal thickness measured with ultrasound pachymetry in a patient with FLD ranged from 623 to 629 μm<sup>9</sup>. This result was not caused by differences in the measuring equipment between ultrasound pachymetry and OCT,<sup>13</sup> by racial differences,<sup>6</sup> or by the uncertainty of the exact speed of sound in corneal tissue,<sup>15</sup> but by an actual increase in corneal thickness. However, ultrasound pachymetry uses a contact measuring device.<sup>9</sup> Hence, this method may be prone to human measurement errors due to the patient's involuntary eye movement and the skill level of the examiner.<sup>13,16,17</sup> In contrast, OCT uses non-contact, automatic inspection performed under monitor supervision, which makes it less prone to such human measurement errors compared with ultrasound pachymetry. Therefore, swept-source OCT measurements are considered more accurate than measurements made with ultrasound pachymetry or conventional anterior segment OCT. The central corneal thickness in the patient with FLD in this case was 526 μm for the right eye and 505 μm for the left eye, which was within the normal range, as seen in those with FED.<sup>13,16,17</sup> The peripheral corneal thickness, where the concentration of opacities was highest, was also within the normal range.<sup>18</sup> The results of this case suggest that it is unlikely that differences in LCAT activity would affect the corneal thickness.

Penetrating keratoplasty is often the treatment of choice for patients with FLD with corneal opacities.<sup>5,9,19</sup> However, a study of corneal tissue after penetrating keratoplasty for FLD found that deposits were present in the corneal stroma, but not in the Descemet membrane or corneal endothelium.<sup>9,19</sup> Thus, this condition could theoretically be treated with deep lamellar keratoplasty. The advantage of deep lamellar keratoplasty over penetrating keratoplasty is that there is very little decrease in corneal endothelial cells, and the rejection reaction can be avoided.<sup>20</sup>



**Fig. 2.** Swept-source optical coherence tomography (SS-OCT), Fourier maps, corneal pachymetry, and images of a patient with FLD. a) The central corneal thickness was 526 μm for the right eye and 505 μm for the left eye with corneal thickness mapping on a swept-source OCT image. b) Fourier maps of the right eye. The original map (upper left) was decomposed into spherical equivalent (upper middle), regular astigmatism (upper right), asymmetry (lower middle), and higher-order irregularity (lower right) components. c) Fourier maps of the left eye, divided as for the right eye. d) SS-OCT image of the left eye. A uniform high reflection was observed across the entire corneal stroma.

Therefore, we opted for deep lamellar keratoplasty rather than penetrating keratoplasty in the present case. Since FED corneal opacities have the same histological findings as those in FLD, a deep lamellar keratoplasty is theoretically possible. Technically, however, deep

lamellar keratoplasty cannot remove all the deposits.<sup>7</sup> Hence, some researchers argue that penetrating keratoplasty is the best surgical procedure for FED.<sup>7</sup> Nonetheless, we have achieved favorable postoperative outcomes with deep lamellar keratoplasty. The patient's brother also underwent deep lamellar keratoplasty with good postoperative results.<sup>12</sup> Therefore, we consider deep lamellar keratoplasty a better surgical procedure for FLD with corneal opacities than penetrating keratoplasty.

To the best of our knowledge, two cases of angioid streaks of the retina in patients with FLD have been reported.<sup>12,21</sup> One of these cases was that of brother of the present patient.<sup>12</sup> Our patient had irregular radial lines spreading from the optic nerve head, which is a characteristic feature of angioid streaks of the retina,<sup>22</sup> and chorioretinal atrophy and peau d'orange appearance in both eyes. Angioid streaks are known to be associated with various systemic diseases.<sup>22</sup> In particular, they occur with a high frequency in patients with pseudoxanthoma elasticum.<sup>22</sup> No obvious signs of skin lesions or systemic disease were found in this case or in the case of the patient's brother<sup>12</sup>; however, skin biopsy and detailed examination might have revealed a disease associated with angioid streaks. In addition, the angioid streak in this case might have been coincidental, although the medical and ophthalmic findings are suggestive of genetic involvement. Thus, it is important to consider the possibility that FLD may be associated with angioid streaks of the retina.

Several papers have reported on LCAT deficiency<sup>9,14</sup>; however, LCAT deficiency includes both FLD and FED.<sup>1</sup> In other words, LCAT deficiency is a broad diagnostic term for pathologies with abnormalities of the *LCAT* gene. Although one study<sup>6</sup> distinguished LCAT deficiency and FED as separate diseases, this was inaccurate. Similarly, FLD and LCAT deficiency are not interchangeable terms.<sup>9</sup> Specifically, the patient findings described in the study by Palmiero et al.<sup>14</sup> are not indicative of FLD, because the patient had only a family history and corneal opacities, and lacked normochromic anemia and renal impairment. Furthermore, even if the case was diagnosed as FED, there was no description of the results of an *LCAT* gene test and LCAT activity measurement, which are necessary for a definitive diagnosis. Therefore, it is unclear how the disease was differentiated from diseases with low-HDL cholesterolemia accompanied by corneal opacities such as FED and apolipoprotein A deficiency, and it is difficult to estimate the accuracy of that patient's diagnosis.<sup>14</sup> Accordingly, the terms "FLD" or "FED" should be used rather than "LCAT deficiency" to avoid misunderstanding.

Since corneal opacities in FLD occur before normochromic anemia and renal impairment, ophthalmologic assessment is important for the early detection of FLD.<sup>4</sup> Diseases that need to be differentiated from FLD include FED, apolipoprotein A deficiency, and Tangier disease.<sup>23</sup> As is the case with FLD, FED and apolipoprotein A deficiency have a paucity of physical findings other than low-HDL cholesterolemia and corneal opacities.<sup>23</sup> Therefore, analysis of the *LCAT* gene and measurement of LCAT activity are necessary for a definitive diagnosis after blood, lipid, and urine tests. In the absence of normochromic anemia and renal impairment (proteinuria), FED is suspected; however, in the presence of apoA1 structural abnormality and deficiency, apolipoprotein A deficiency is suspected. In contrast, physical manifestations in patients with Tangier disease include hypertrophy of the tonsils (orange tonsils), hepatosplenomegaly, and sensory and motor deficits due to peripheral neuropathy.<sup>23</sup> Thus, as there are systemic diseases other than FLD where corneal opacities can help with diagnosis, it is important for ophthalmologists to have knowledge about cases where low-HDL cholesterolemia is accompanied by corneal opacities.

There is no effective treatment for FLD other than corneal transplantation once visual acuity deteriorates due to corneal opacities.<sup>4</sup> However, the world's first gene therapy for FLD has recently been introduced in Japan, which enables continuous enzyme replacement.<sup>24</sup> Specifically, in this treatment, a normal *LCAT* gene is introduced into the adipocytes collected from the adipose tissue of patients with FLD, and re-implanted into the patients to continuously replenish normal LCAT protein. Six months after administration, there were persistent changes

suggestive of transplantation safety and improvement in lipid metabolism that had been impaired by LCAT deficiency.<sup>24</sup> The effect of this treatment on corneal opacities is currently unknown. However, if gene therapy improves the lipid profile, it may be possible to prevent FC deposition on the cornea, which is the cause of corneal opacities. Therefore, if gene therapy intervention can be performed at a very early stage, it may be possible to retain corneal transparency. Moreover, if gene therapy is performed while the corneal opacities are still mild, it may prevent their progression and obviate the need for corneal transplantation.

## 5. Conclusions

In this study, we measured the corneal thickness in a patient with FLD using swept-source OCT and used objective data and surgical intervention to achieve a favorable postoperative outcome. Nevertheless, since FLD is a rare disease, it is essential to collect and examine further data on corneal thickness. We also expect the effect of gene therapy on corneal opacities to be clarified in the future.

## Patient consent

Ethics approval: All procedures performed in this study were in accordance with the ethical standards of the institutional and national research committee and with the Helsinki Declaration of 1964 and its later amendments. This study was approved by the Institutional Review Board of Sakashita Hospital.

## Consent to participate

Written informed consent to undergo the procedure described here was obtained from the patient.

## Consent for publication

Not applicable.

## Funding

No funding or grant support.

## Authorship

All authors attest that they meet the current ICMJE criteria for Authorship.

Shinsuke Kinoshita devised the project and the main conceptual ideas and drafted the manuscript outline. All authors contributed to the study conception and design. Material preparation, data collection, and analysis were performed by Seiichiro Sugita and Akihiro Yoshida. The first draft of the manuscript was prepared by Shinsuke Kinoshita, and all authors commented on the previous versions of the manuscript. All authors have read and approved the final manuscript. All authors contributed to the writing of the final manuscript.

## Declaration of competing interest

The authors declare that they have no conflict of interest.

## Acknowledgements

None.

## References

- Saeedi R, Li M, Frohlich J. A review on lecithin: cholesterol acyltransferase deficiency. *Clin Biochem*. 2015;48(7-8):472–475. <https://doi.org/10.1016/j.clinbiochem.2014.08.014>.
- Gjone E, Norum KR. Familial serum cholesterol ester deficiency. Clinical study of a patient with a new syndrome. *Acta Med Scand*. 1968;183(1-6):107–112.
- McIntyre N. Familial LCAT deficiency and fish-eye disease. *J Inherit Metab Dis*. 1988; 11(Suppl 1):45–56. <https://doi.org/10.1007/BF01800570>.
- Barchiesi BJ, Eckel RH, Ellis PP. The cornea and disorders of lipid metabolism. *Surv Ophthalmol*. 1991;36(1):1–22. [https://doi.org/10.1016/0039-6257\(91\)90205-T](https://doi.org/10.1016/0039-6257(91)90205-T).
- Winder AF, Garner A, Sheridah GA, Barry P. Familial lecithin: cholesterol acyltransferase deficiency. *Biochemistry of the cornea. J Lipid Res*. 1985;26(3): 283–287.
- Kanai M, Koh S, Masuda D, Koseki M, Nishida K. Clinical features and visual function in a patient with fish-eye disease: quantitative measurements and optical coherence tomography. *Am J Ophthalmol Case Rep*. 2018;10:137–141. <https://doi.org/10.1016/j.ajoc.2018.02.016>.
- Tateno H, Taomoto M, Jo N, Takahashi K, Uemura Y. Clinical and histopathological features of a suspected case of fish-eye disease. *Jpn J Ophthalmol*. 2012;56(5): 453–457. <https://doi.org/10.1007/s10384-012-0164-1>.
- Ustaoglu M, Solmaz N, Baser B, Kurtulgan HK, Onder F. Ocular and genetic characteristics observed in two cases of fish-eye disease. *Cornea*. 2019;38(3): 379–383. <https://doi.org/10.1097/ICO.0000000000001804>.
- Viestenz A, Schlötzer-Schrehardt U, Hofmann-Rummelt C, Seitz B, Küchle M. Histopathology of corneal changes in lecithin-cholesterol acyltransferase deficiency. *Cornea*. 2002;21(8):834–837. <https://doi.org/10.1097/00003226-200211000-00022>.
- Naito M, Maeda E, Yoshino G, Kasuga M, Iguchi A, Kuzuya F. Japanese family with a deficiency of lecithin: cholesterol acyltransferase (LCAT). *Intern Med*. 1994;33(11): 677–682. <https://doi.org/10.2169/internalmedicine.33.677>.
- Maeda E, Naito M, Murata Y, et al. Gene analysis of familial LCAT deficiency. *Jpn J Atheroscler Soc*. 1995;23:171 (Abstract in Japanese).
- Hirano K, Kachi S, Ushida C, Naito M. Corneal and macular manifestations in a case of deficient lecithin: cholesterol acyltransferase. *Jpn J Ophthalmol*. 2004;48(1): 82–84. <https://doi.org/10.1007/s10384-003-0007-1>.
- Ishibazawa A, Igarashi S, Hanada K, et al. Central corneal thickness measurements with fourier-domain optical coherence tomography versus ultrasonic pachymetry and rotating scheinplflug camera. *Cornea*. 2011;30(6):615–619. <https://doi.org/10.1097/ICO.0b013e3181d00800>.
- Palmiero PM, Sbeity Z, Liebmann J, Ritch R. In vivo imaging of the cornea in a patient with lecithin-cholesterol acyltransferase deficiency. *Cornea*. 2009;28(9): 1061–1064. <https://doi.org/10.1097/ICO.0b013e31819839ae>.
- Kim HY, Budenz DL, Lee PAKS, Feuer WJ, Barton K. Comparison of central corneal thickness using anterior segment optical coherence tomography vs ultrasound pachymetry. *Am J Ophthalmol*. 2008;145(2):228–233. <https://doi.org/10.1016/j.ajo.2007.09.030>.
- Chen S, Huang J, Wen D, Chen W, Huang D, Wang Q. Measurement of central corneal thickness by high-resolution Scheimpflug imaging, Fourier-domain optical coherence tomography and ultrasound pachymetry. *Acta Ophthalmol*. 2012;90(5): 449–455. <https://doi.org/10.1111/j.1755-3768.2010.01947.x>.
- Scotto R, Bagnis A, Papadia M, Cutolo CA, Rizzo D, Traverso CE. Comparison of central corneal thickness measurements using ultrasonic pachymetry, anterior segment OCT and noncontact specular microscopy. *J Glaucoma*. 2017;26(10): 860–865. <https://doi.org/10.1097/LJG.0000000000000745>.
- Martin R, Jonuscheit S, Rio-Cristobal A, Doughty MJ. Repeatability of Pentacam peripheral corneal thickness measurements. *Contact Lens Anterior Eye*. 2015;38(6): 424–429. <https://doi.org/10.1016/j.clae.2015.05.001>.
- Hörven I. Ocular manifestations in familial lecithin: cholesterol acyltransferase deficiency. *Scand J Clin Lab Invest*. 1974;33(Suppl 137):89–91.
- Borderie VM, Sandali O, Bullet J, Gaujoux T, Touzeau O, Laroche L. Long-term results of deep anterior lamellar versus penetrating keratoplasty. *Ophthalmology*. 2012;119(2):249–255. <https://doi.org/10.1016/j.ophtha.2011.07.057>.
- Hörven I, Egge K, Gjone E. Corneal and fundus changes in familial LCAT-deficiency. *Acta Ophthalmol*. 1974;52(2):201–210. <https://doi.org/10.1111/j.1755-3768.1974.tb00368.x>.
- Chatziralli I, Saitakis G, Dimitriou E, et al. Angioid streaks: a comprehensive review from pathophysiology to treatment. *Retina*. 2019;39(1):1–11. <https://doi.org/10.1097/IAE.0000000000002327>.
- von Eckardstein A. Differential diagnosis of familial high-density lipoprotein deficiency syndromes. *Atherosclerosis*. 2006;186(2):231–239. <https://doi.org/10.1016/j.atherosclerosis.2005.10.033>.
- UMIN-CTR clinical trial. Available at [https://upload.umin.ac.jp/cgi-open-bin/ctr\\_e/ctr\\_view.cgi?recptno=R000027343](https://upload.umin.ac.jp/cgi-open-bin/ctr_e/ctr_view.cgi?recptno=R000027343). Accessed July 4, 2020.