

CASE REPORT

A major pain in the . . . Back and epigastrium: an unusual case of spontaneous celiac artery dissection

Kumkum Sarkar Patel, MD, MPH (PGY3 Resident)^{1*}, Orel Benshar, MD², Raluca Vrabie, MD³, Anik Patel, MD³, Marc Adler, MD¹ and George Hines, MD⁴

¹Department of Internal Medicine, Winthrop-University Hospital, Mineola, NY, USA; ²School of Medicine, St. George's University, Great Neck, NY, USA; ³Division of Gastroenterology, Winthrop-University Hospital, Mineola, NY, USA; ⁴Department of Vascular Surgery, Winthrop-University Hospital, Mineola, NY, USA

A 60-year-old woman with mitral valve prolapse, chronic low back pain, and a 30-pack year smoking history presented for a second admission of poorly controlled mid-back pain 10 days after her first admission. She had concomitant epigastric pain, sharp/burning in quality, radiating to the right side and to the mid-back, not associated with food nor improving with pain medications. She denied nausea, vomiting, diarrhea, constipation, dark stools, or blood per rectum. Our purpose was to determine the cause of the patient's epigastric pain. Physical examination revealed epigastric and mid-back tenderness on palpation. Labs were normal except for a hemoglobin drop from 14 to 12.1 g/dL over 2 days. Abdominal ultrasound and subsequent esophagogastroduodenoscopy were normal. Contrast-enhanced abdominal computed tomographic (CT) scan revealed the development of a spontaneous celiac artery dissection as the cause of the epigastric pain. The patient was observed without stenting and subsequent CT angiography 4 days later did not reveal worsening of the dissection. She was discharged on aspirin and clopidogrel with outpatient follow-up. Thus far, less than 100 cases of isolated spontaneous celiac artery dissections have been reported. The advent of CT scans and magnetic resonance imaging has increasingly enabled its detection. Risk factors may include hypertension, arteriosclerosis, smoking, and cystic medial necrosis. There is a 5:1 male to female ratio with an average presenting age of 55. Management of dissections may include surgical repair, endovascular stenting, and selective embolization. Limited dissections can be managed conservatively with anti-platelet and/or anticoagulation agents and strict blood pressure control, as done in our patient.

Keywords: *celiac artery; artery dissection; epigastric pain; celiac trunk; back pain*

*Correspondence to: Kumkum Sarkar Patel, Department of Internal Medicine, Winthrop-University Hospital, 260 First Street, Apt. B13, Mineola, NY 11501, USA, Email: kumkum.sarkar@gmail.com

Received: 13 July 2014; Revised: 13 August 2014; Accepted: 11 September 2014; Published: 25 November 2014

Artery dissection is defined by intimal layer disruption, allowing for blood to enter the media, and separate the intimal and adventitial layers. The dissecting column of blood forms a false lumen, which may extend proximally, distally, or both (1–3). Extra-aortic dissections include – in decreasing order – renal, coronary, cerebral, carotid, vertebral, and visceral arteries (1, 4). Of these isolated dissections of visceral arteries, the superior mesenteric artery accounts for the highest percentage of spontaneous isolated visceral arterial dissection (1, 3, 5). Risk factors for celiac artery dissection may include hypertension, arteriosclerosis, smoking, iatrogenic injury, trauma, fibromuscular dysplasia, cystic medial necrosis, connective tissue disorders, and pregnancy (1, 5–8). Demographically, there is a 5:1 male to female ratio with an average presenting age of 55 for

celiac artery dissection (8). The most common presentation for celiac artery dissection is acute epigastric pain with epigastric tenderness and/or systolic bruits (1, 5, 8). While some cases reported asymptomatic patients, other cases involved patients with chronic postprandial pain, weight loss, chest pain, dyspepsia, obstructive jaundice, intestinal angina, or pancreatitis (3, 9–12). Furthermore, in most of the described cases, the patients are in good health and no exact cause for dissection can be determined (3, 5). We present a unique case of spontaneous celiac artery dissection in a 60-year-old female.

Case presentation

A 60-year-old woman with past medical history of mitral valve prolapse, chronic low back pain, and a 30-pack year

smoking history presented for a second admission of poorly controlled mid-back pain 10 days after her first admission. The back pain was located in the T11 region in the mid-back. She had concomitant epigastric pain, sudden in onset, sharp/burning in quality, radiating to the right side and to the mid-back, not associated with food nor improving with pain medications. She denied nausea, vomiting, diarrhea, constipation, dark stools, or blood per rectum. Her past surgical history included an appendectomy, tonsillectomy, hysterectomy, tubal ligation, and resection of benign breast nodules. Her social history was significant for consuming 2–3 glasses of alcohol a week and smoking two packs per day for 15 years (quit 10 years ago). Her family history was non-contributory. The patient admitted to a 10-pound weight loss in the past 2 weeks secondary to poor appetite due to epigastric pain. Her only allergies were to sulfa drugs. Physical examination revealed normal heart, breath, and bowel sounds. However, she did have epigastric and mid-back tenderness on palpation. Laboratory tests revealed normal liver function tests, coagulation profile, and renal panel. However, complete blood count over 2 days revealed a hemoglobin drop from 14 to 12.1 g/dL. During the patient's hospital stay, she was prescribed hydromorphone for pain control. Magnetic resonance imaging (MRI) and computed tomographic (CT) scans of the thoracolumbar spine from the first admission revealed no organomegaly, normal abdominal aorta, and diffuse degenerative spine changes (see Fig. 1).

Abdominal ultrasound from the current admission showed no gallstones, wall thickening, or pericholecystic fluid. Subsequent esophagogastroduodenoscopy performed by the gastroenterology team during the current

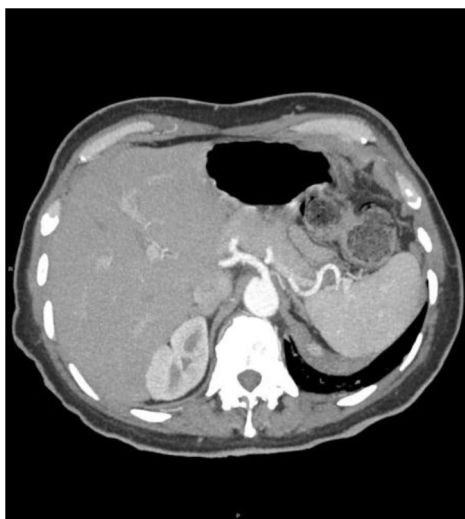

Fig. 1. Computed tomography – chest, abdomen, and pelvis from the first admission: No organomegaly, normal abdominal aorta, and diffuse degenerative spine changes.

admission revealed normal z-line, antrum, body of the stomach, cardia, fundus, duodenal bulb, and second portion of the duodenum. A hiatal hernia was found in the esophagus. Thus, the patient was started on pantoprazole 40 mg twice a day. However, the patient's epigastric pain had not improved since the day of admission. Hence, a contrast-enhanced abdominal CT scan was obtained, which revealed a normal abdominal aorta and a severely narrowed celiac artery with surrounding soft tissue density, consistent with celiac artery dissection. The common hepatic, splenic, left gastric, superior mesenteric, renal, and inferior mesenteric arteries were patent (see Fig. 2). It was determined that the development of a spontaneous celiac artery dissection was the cause of the epigastric pain. Thus, the vascular surgery team was called. The patient was observed and subsequent CT angiography (CTA) 4 days later did not reveal worsening of the dissection or formation of a pseudoaneurysm (see Fig. 3). Thus, there was no need for endovascular stenting or surgical repair. The patient was discharged on aspirin and clopidogrel with outpatient follow-up.

Discussion

Isolated spontaneous celiac artery dissection is a very rare entity. To date, there have been less than 100 reported cases (2, 5, 12). The majority of cases have been reported in the past decade, which can be attributed to the increased use of CT scans and other more advanced radiologic imaging modalities. A few reports from the late 1950s and 1960s were described in post-mortem autopsies

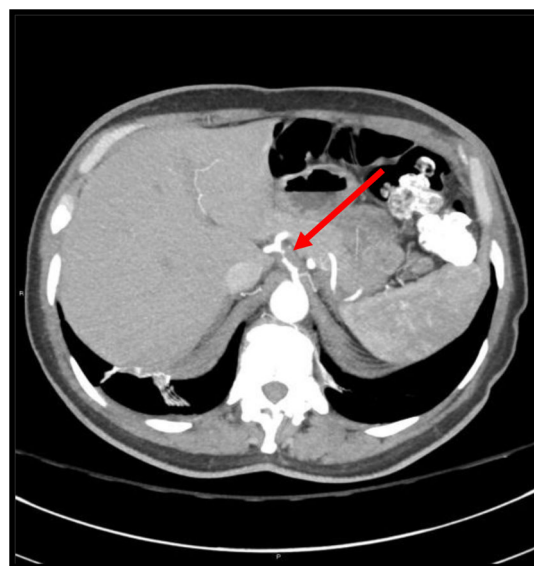


Fig. 2. Computed tomography – chest, abdomen, and pelvis from the second admission: The celiac artery is now severely narrowed with surrounding soft tissue density, consistent with celiac artery dissection, as shown by the arrow. The soft tissue density represents infiltration of fat.

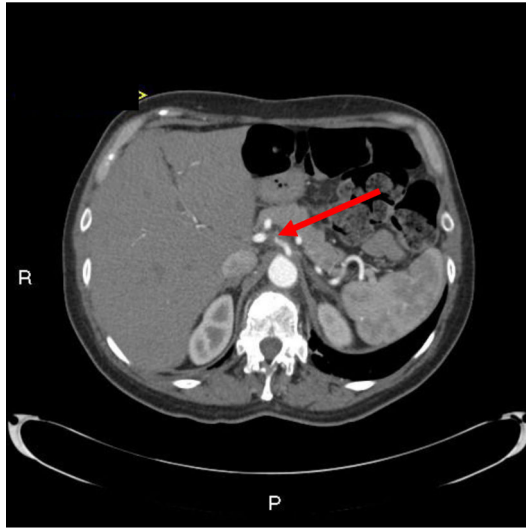


Fig. 3. Computed tomographic angiography (CTA) 4 days after diagnosis: The CTA confirmed celiac arterial dissection. No major change in the appearance of this process compared with previous CT, as shown by the arrow. No pseudoaneurysm formation. There is no evidence for hepatic or splenic infarction. The aorta is unremarkable and unchanged.

(3). Overall, the total number of isolated celiac artery dissections is under-reported and although it is one of the rarer vascular causes of epigastric pain, clinicians should be increasingly cognizant of this presentation and should selectively consider it as a differential diagnosis.

While MRI and conventional angiography may be used, ultrasound and CT are sensitive enough to suggest celiac artery dissection; hence, they are most often the first imaging modalities used for acute abdominal pain (1, 5, 6). CTA is the gold standard for definitive diagnosis of celiac artery dissection (1, 5, 8). CTA depicts the extent of the involvement in the artery. Therefore, potential sequelae can be averted and management decisions for surgical interventions can be expedited. A few possible consequences of dissection have been described, which include complete spontaneous resolution, occlusion of visceral artery, and aneurysmal formation, intestinal ischemia, splenic infarction, and intraperitoneal hemorrhage (1, 5, 8, 13). Moreover, if dissections are minor and non-progressive over time, observation and medical management may be considered.

In the acute setting, symptomatic patients with a complicated presentation – unstable vital signs, dropping hemoglobin levels, concerning radiological findings, or worsening pain – may require urgent invasive interventions such as endovascular stenting or surgical repair. Glehen et al. suggested urgent surgical intervention for the following radiographic findings: fusiform or saccular aneurysms, signs of imminent rupture, hemorrhaging, profound organ ischemia, or artery dilation of 1.5–2.0 cm or greater (1). Silvestre et al. suggested that surgical or

endovascular treatment should be carried out only when there is aneurysm formation with progressive growth to a transverse diameter of more than 20 or 24 mm, which represents 2.5–3.0 times the normal artery diameter (4).

Poor surgical candidates who cannot undergo proper radiology imaging or any anatomical abnormalities may undergo selective embolization or endovascular stent placement (8, 14–17). While there are no studies comparing the effectiveness of endovascular stenting versus surgical repair, endovascular stenting may provide shorter hospital stays and decreased need for anticoagulation, thus decreasing future potential bleeds (5).

Patients, such as ours, with limited dissections can be treated conservatively with medical management and continued surveillance. Medical management consists of anti-platelet and/or anticoagulation agents along with strict blood pressure control (3, 4, 6, 12). Use of anti-platelet agents such as clopidogrel and anticoagulation agents such as warfarin may prevent thromboembolic events secondary to possible exposure of the subendothelium. Patients benefit from anticoagulation for up to 6 months with INR goals between 2 and 3 (4, 5, 15, 16). If signs of organ ischemia are evident despite anti-platelet or anticoagulation therapy, surgical repair or endovascular stenting would be subsequently considered. Strict blood pressure with anti-hypertensive agents aid in decreasing potential for propagation of the dissection. In addition, patients with limited dissections should undergo surveillance with serial's CTA to look for evidence of rupture or expansion.

Of note, the patient in our case was quite interesting, as her new diagnosis of celiac artery dissection prompted us to speculate whether she may have an underlying connective tissue disorder. One such disorder under consideration was Marfan's disease, as the patient has long, thin fingers, a history of mitral valve prolapse, and now a newly diagnosed celiac artery dissection. The patient will get tested for the Fibrillin-1 gene as an outpatient. In conclusion, celiac artery dissection is a rare but upcoming clinical entity to consider in the differential for causes of pain in the back and epigastrium.

Conflict of interest and funding

The authors have not received any funding or benefits from industry or elsewhere to conduct this study.

References

- Glehen O, Feugier P, Aleksic Y, Delannoy P, Chevalier JM. Spontaneous dissection of the celiac artery. *Ann Vasc Surg* 2001; 15(6): 687–92.
- Foord AG, Lewis RD. Primary dissecting aneurysms of peripheral and pulmonary arteries: Dissecting hemorrhage of media. *Arch Pathol* 1959; 68: 553–77.

3. Ozturk TC, Yaylaci S, Yesil O, Cevik SE, Guneyzel O. Spontaneous isolated celiac artery dissection. *J Res Med Sci* 2011; 16(5): 699–702.
4. Silvestre J, Sardinha WE, Piazzalunga M, Fernandes B, Motto F, Silvestre G. Isolated dissection of the celiac artery: A case report. *J Vasc Bras* 2010; 9(3): 152–5.
5. Obon-Dent M, Shabaneh B, Dougherty KG, Strickman NE. Spontaneous celiac artery dissection case report and literature review. *Tex Heart Inst J* 2012; 39(5): 703–6.
6. Amabile P, Ouaiissi M, Cohen S, Piquet P. Conservative treatment of spontaneous and isolated dissection of mesenteric arteries. *Ann Vasc Surg* 2009; 23(6): 738–44.
7. Fenoglio L, Allione A, Scalabrino E, Alberto G, Benedetti V, Pomero F, et al. Spontaneous dissection of the celiac artery: A pitfall in the diagnosis of acute abdominal pain. Presentation of two cases. *Dig Dis Sci* 2004; 49(7–8): 1223–7.
8. D'Ambrosio N, Friedman B, Siegel D, Katz D, Newatia A, Hines J. Spontaneous isolated dissection of the celiac artery: CT findings in adults. *AJR Am J Roentgenol* 2007; 188(6): W506–11.
9. Batsis JA, Arora AS. Celiac artery dissection: An uncommon cause of abdominal pain and weight loss. *Clin Gastroenterol Hepatol* 2005; 3(10): A30.
10. Chaillou P, Moussu P, Noel SF, Sagan C, Pistorius MA, Langlard JM, et al. Spontaneous dissection of the celiac artery. *Ann Vasc Surg* 1997; 11(4): 413–5.
11. Wang JL, Hsieh MJ, Lee CH, Chen CC, Hsieh IC. Celiac artery dissection presenting with abdominal and chest pain. *Am J Emerg Med* 2010; 28(1): 111, e3–5.
12. Schrijvers R, Van De Mierop F, De Schepper B, Sprengers D, Dero I, D'Archambeau O, et al. Spontaneous dissection of the celiac trunk: A rare cause of abdominal pain – Case report and review of the literature. *Acta Gastroenterol Belg* 2013; 76(3): 335–9.
13. Takach TJ, Madjarov JM, Holleman JH, Robicsek F, Roush TS. Spontaneous splanchnic dissection: Application and timing of therapeutic options. *J Vasc Surg* 2009; 50(3): 557–63.
14. Takeda H, Matsunaga N, Sakamoto I, Obata S, Nakamura S, Hayashi K. Spontaneous dissection of the celiac and hepatic arteries treated by transcatheter embolization. *AJR Am J Roentgenol* 1995; 165(5): 1288–9.
15. Zhang T, Zhang X, Zhang X, Jiang J, Zhou B. Endovascular treatment of isolated spontaneous celiac artery dissection. *Vascular* 2012; 20(2): 118–20.
16. Woolard JD, Ammar AD. Spontaneous dissection of the celiac artery: A case report. *J Vasc Surg* 2007; 45(6): 1256–8.
17. Nordanstig J, Gerdes H, Kocys E. Spontaneous isolated dissection of the celiac trunk with rupture of the proximal splenic artery: A case report. *Eur J Vasc Endovasc Surg* 2009; 37(2): 194–7.