

Are Metaphyseal Sleeves a Viable Option to Treat Bone Defect during Revision Total Knee Arthroplasty? A Systematic Review

Tommaso Bonanzinga¹ Ibrahim Akkawi² Akos Zahar³ Thorsten Gehrke³ Carl Haasper³ Maurilio Marcacci¹

¹ Center for Functional and Biological Reconstruction of the Knee, Humanitas Clinical and Research Center, Milan, Italy

² Orthopaedics and Traumatology Unit, Villa Erbosa Hospital, Bologna, Italy

³ Joint Replacement Department, Helios ENDO-Klinik, Hamburg, Germany

Address for correspondence Ibrahim Akkawi, MD, Orthopaedics and Traumatology Unit, Villa Erbosa Hospital, Bologna 40129, Italy (e-mail: i.akkawi@libero.it).

Joints 2019;7:19–24.

Abstract

Purpose Bone loss is a challenging problem during revision total knee arthroplasty (TKA). Several studies have been published on the use of metaphyseal sleeves during revision TKA. Therefore, the aim of this systematic review was to summarize the clinical and radiographic outcomes of the use of metaphyseal sleeves in the setting of revision TKA.

Methods A comprehensive search of PubMed, MEDLINE, CINAHL, Cochrane, EMBASE, and Google Scholar was performed, covering the period between January 1, 2000, and August 12, 2017. Various combinations of the following key words were used: “metaphyseal,” “sleeves,” “knee,” and “revision.” A total of 10 studies were included in the present systematic review.

Results A total of 904 patients with 928 implants were recorded with a mean age of 69 years. They were evaluated at a mean follow-up of 45 months. Overall 1,413 sleeves, 888 in the tibia and 525 in the femur, were implanted. There were 36 septic re-revisions of the prosthetic components (4%). Five sleeves were found loose during septic re-revision; therefore, the rate of septic loosening of the sleeves was 0.35%. An aseptic re-revision of the prosthetic components was performed 27 times (3%). Ten sleeves were found loose during aseptic re-revision; therefore, the rate of aseptic loosening of the sleeves was 0.7%. Intraoperative fractures occurred 44 times (3.1%). Finally, clinical outcome was improved at final follow-up.

Conclusion Metaphyseal sleeves demonstrate high radiographic signs of osteointegration, low septic loosening rate, low intraoperative fractures rate, and a good-to-excellent clinical outcome. Hence, they are a valid option to treat large metaphyseal bone defect during revision TKA.

Level of Evidence This is a systematic review of level IV studies.

Keywords

- ▶ revision total knee arthroplasty
- ▶ metaphyseal sleeves
- ▶ AORI
- ▶ bone defect

received
December 8, 2017
accepted after revision
August 7, 2019
published online
October 11, 2019

DOI <https://doi.org/10.1055/s-0039-1697611>.
ISSN 2282-4324.

Copyright © 2019 Georg Thieme Verlag
KG Stuttgart · New York

License terms



Introduction

By 2030, in the United States, the demand for primary total knee arthroplasties (TKAs) and revision TKA is projected to grow by 673 and 601%, respectively, from the level in 2005.¹ Bone loss is a challenging problem during revision TKA, which can prevent the correct positioning and alignment of the prosthetic components, and the establishment of a stable bone–implant interface.^{2,3} There are several techniques to address this problem that depend on the location and dimension of bone loss. Small bone defects can be managed with morcellized bone graft, cement, or bone substitutes,⁴ whereas large defects can be addressed by impaction grafting, use of bulk structural allografts, resection prostheses, and allograft–prosthesis composite.^{3,5}

Recently, other techniques have been described to manage large bone defects during revision TKA. The options are trabecular tantalum cones^{6–9} and titanium metaphyseal sleeves.^{10–24} Trabecular tantalum cones are implanted in direct contact with the host bone, and the prosthetic components are then cemented inside the cones.³ Tantalum cones are an effective solution to address bone defects with low incidence of complications at short- to midterm follow-up.^{6–9} Metaphyseal sleeves are another strategy to manage large bone defects in revision TKA. Similarly to tantalum cones, metaphyseal sleeves provide a stable mechanical support for the prosthetic component.³ The prosthetic components are fixed to the sleeve with a Morse taper.¹² Disadvantages of metaphyseal sleeves include the following: first, the elevated costs; second, the difficult extraction during revision TKA of a well-fixed implant after bone growth that could be associated with periprosthetic fracture and significant bone loss^{19,20,25} third, they are implant-specific and are coupled to the revision implant by a Morse taper that limits the surgeon's options with respect to the type of device.¹²

Several studies have been published on the use of metaphyseal sleeves during revision TKA. Therefore, the purpose of this systematic review is to review the available literature to evaluate whether the metaphyseal sleeves are a valid option to address large metaphyseal bone loss in the setting of complex revision TKA.

Methods

A comprehensive search of PubMed, MEDLINE, CINAHL, Cochrane, EMBASE, and Google Scholar was performed, covering the period from January 1, 2000, to August 12, 2017. The following combinations were used: metaphyseal AND sleeves, metaphyseal AND sleeves AND revision arthroplasty, metaphyseal AND sleeves AND revision replacement, metaphyseal AND sleeves AND revision total knee replacement, and metaphyseal AND sleeves AND revision TKA. Two reviewers have independently examined the titles and abstracts from all identified articles to assess their appropriateness to this research. Full-text articles were downloaded or purchased when required. In addition, each reference list from the identified articles was manually checked to verify that relevant articles were not missed. All the studies were in English

language. In vitro studies, case reports, surgical technique papers, or studies assessing the use of metaphyseal sleeves during primary TKA were excluded. Reports on retrieved implants or other studies where it was not possible to collect data of the implants were excluded as well. Furthermore, each study was evaluated in terms of the following variables: the number of patients, patient age, follow-up time (range), the number of implants, level of constraint, type of bone defect according to the Anderson Orthopaedic Research Institute (AORI) classification,²⁶ and the number of metaphyseal sleeves implanted (tibia/femur). Complications such as intraoperative fractures (with or without intraoperative fixation) were collected as well. The included studies were also evaluated in terms of re-revisions and the data classified as septic re-revisions or aseptic re-revisions. Among the re-revision procedures, either septic or aseptic, the status of the involved sleeves was recorded. Finally, the aseptic survival rate of the sleeves was collected.

Results

The quality of reporting of meta-analysis²⁷ flow diagram illustrates the number of studies that have been identified, included, and excluded, along with the reasons for exclusion (► **Fig. 1**). A total of 15 articles^{10–24} that reported the outcome of the use of metaphyseal sleeves for treating large bone defects during revision TKA were identified on the initial literature search. Of these, five were excluded. In particular, Jones et al²¹ and Barrack¹³ analyzed both primary and revision TKA, Dalury and Barrett¹⁶ did not report the number of sleeves, and Gøttsche et al¹⁸ did not specify the status of the sleeves of the re-revised cases. Finally, Nadorfet al²⁴ conducted an in vitro study. Hence, a total of 10 papers^{10–12,14,15,17,19,20,22,23} published from January 1, 2000, to August 12, 2017, that reported clinical data on the management of metaphyseal bone loss using metaphyseal sleeves in the setting of complex revision TKA were included in the present systematic review. All the papers were case series (Level of Evidence IV). Three papers^{19,20,22} were prospective and seven papers^{10–12,14,15,17,23} were retrospective.

Patients' Demographics

In the 10 studies included, the data of 904 patients who received 928 revision TKAs were recorded. They had a mean age of 69 years. The patients were evaluated at a mean follow-up of 45 months (range: 24–115 months) (► **Table 1**).

Surgical Reports

The level of constraint of the implants was clearly specified in all cases: 4 implants were cruciate-retaining (CR), 195 were posterior-stabilized (PS), 686 were varus valgus condylar constrained, and 43 were rotating hinge. A detailed AORI classification of the bone defects was provided in seven studies^{10,15,17,19,20,22,23} with a total of 1,289 defects (including both femoral and tibial). A total of 209 bone defects were type 1, 323 type 2A, 625 type 2B, and 132 type 3. In one study,¹⁴ the number of type 2A and 2B bone defects was not specified, and in other two studies,^{11,12} the number of all types of bone defects was not specified. The number of

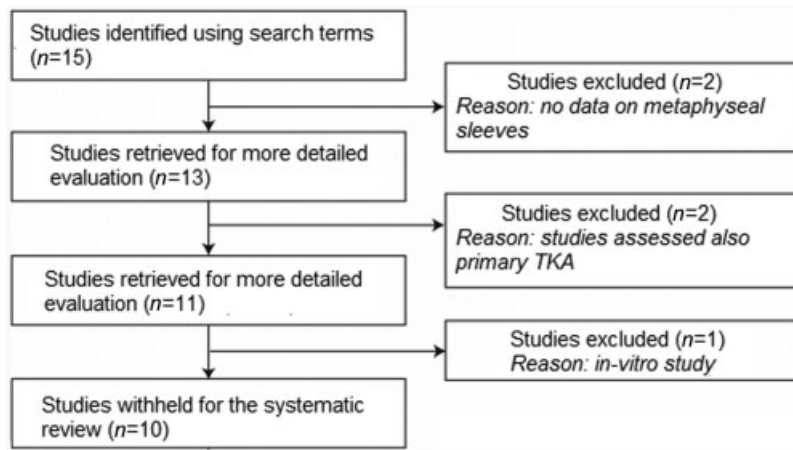


Fig. 1 The quality of reporting of meta-analyses flow diagram of included studies. Studies identified, included, and excluded as well as the reasons for exclusion. TKA, total knee arthroplasty.

Table 1 Demographic data

Author	Year	Type of study	Patients	Age, years	Follow-up months (range)
Graichen et al ¹⁹	2015	Prospective	111	74	42 (24–73)
Huang et al ²⁰	2014	Prospective	79	63.5	28 (24–43)
Alexander ¹¹	2013	Retrospective	28	71	33 (24–52)
Bugler et al ¹⁴	2015	Retrospective	34	72	39 (24–62)
Barnett et al ¹²	2014	Retrospective	34	66	38 (24–62)
Agarwal et al ¹⁰	2013	Retrospective	103	69	43 (30–65)
Martin-Hernandez ²²	2017	Prospective	134	75	71.5 (36–107)
Chalmers et al ¹⁵	2017	Retrospective	227	66	36 (24–96)
Fedorka et al ¹⁷	2017	Retrospective	46	65.6	58.8 (25.8–93)
Watters et al ²³	2017	Retrospective	108	63.7	63.5 (24–115)

sleeves has been reported in all analyzed studies; overall 1,413 sleeves, 888 in the tibia and 525 in the femur, were implanted (► **Table 2**).

Outcomes and Complications

Overall, there were 36 septic re-revisions of the prosthetic components out of 928 procedures (4%). A total of five sleeves were found loose during septic re-revision; therefore, the rate of septic loosening of the sleeves was 0.35% (5/1,413). An aseptic re-revision of the prosthetic components was performed 27 times out of 928 procedures (3%). A total of 10 sleeves were found loose during aseptic re-revision; therefore, the rate of aseptic loosening of the sleeves was 0.7% (10/1,413). Intraoperative fractures occurred 44 times (44/1,413= 3.1%), and 6 (6/1,413= 0.42%) of them required surgical fixation (► **Table 3**). Clinical outcome of metaphyseal sleeves was evaluated with Oxford Knee Score (OKS), Knee Society Score (KSS), Knee Society Function Score (KSFS), Short Form 12 Physical Score (SF 12 PS), Short Form 12 Mental Score (SF 12 MS), Short Form 36 Physical Score (SF 36 PS), Short Form 36 Mental Score (SF 36 MS), and Western Ontario and McMaster Universities Arthritis Index (WOMAC). Chalmers et al¹⁵ and Fedorka et al¹⁷ did not report any clinical outcome, Bugler

et al¹⁴ reported only the postoperative values of OKS and KSS scores, and Watters et al²³ did not report the preoperative OKS score. For the other scores, both pre- and final follow-up values were reported. There was a statistically significant improvement at final follow-up in all these scores, except of the SF 36 MS²⁰ and KSFS scores¹¹ (► **Table 4**).

Discussion

The main finding of this review is that the use of metaphyseal sleeves to treat bone defects encountered during revision TKA is associated with a low septic and aseptic loosening rate, a low intraoperative fracture rate, and a good-to-excellent clinical outcome at a mean follow-up of 45 months.

Metaphyseal sleeves have demonstrated to have a high osteointegration rate that is confirmed by the results of the present review. The aseptic loosening rate of the 1,413 sleeves in all the studies included in this review was 0.7%. The survivorship free of revision for aseptic loosening of the metaphyseal sleeves ranged from 98 to 100%. Alexander et al,¹¹ Barnett et al,¹² Bugler et al,¹⁴ and Martin-Hernandez et al²² reported a survivorship free of revision for aseptic loosening of the metaphyseal sleeves of 100%. These results are

Table 2 Details of the number and type of implants, and the number of bone defects and sleeves

Author	No. of implants	Constraint	Type of bone defect according to AORI (T/F)	No. of sleeves (T/F)
Graichen et al ¹⁹	121	PS 77	2A 77 (77/0)	193 (119/74)
		VVC 27	2B 83 (37/46)	
		RH 17	3 35 (7/28)	
Huang et al ²⁰	83	VVC 73	1 13 (9/4)	119 (83/36)
		RH 10	2A 1 (1/0)	
			2B 93 (86/25)	
			3 12 (5/7)	
Alexander ¹¹	28	VVC 28	2B n.s. (n.s.)	28 (28/0)
			3 n.s. (n.s.)	
Bugler et al ¹⁴	35	VVC 35	1 37 (20/17)	59 (34/25)
			2 29 (13/16)	
			3 2 (2/0)	
Barnett et al ¹²	34	PS 7	2 n.s. (n.s.)	34 (34/0)
		VVC 24	3 n.s. (n.s.)	
		RH 3		
Agarwal et al ¹⁰	104	CR 4	1 2 (0/2)	164 (101/63)
		PS 45	2A 33 (27/6)	
		VVC 55	2B 85 (39/46)	
			3 13 (11/2)	
Martin-Hernandez ²²	134	VVC 134	1 133 (63/70)	268 (134/134)
			2A 62 (32/30)	
			2B 73 (39/34)	
Chalmers et al ¹⁵	227	PS 51	1: 55 (44/11)	322 (199/123)
		VVC 166	2A: 104 (74/30)	
		RH 10	2B: 135 (64/71)	
			3: 28 (17/11)	
Fedorka et al ¹⁷	46	VVC 46	1: 6 (½)	74 (45/29)
			2A: 38 (30/8)	
			2B: 33 (2/31)	
			3: 23 (17/6)	
Watters et al ²³	116	15 PS	2A: 8 (5/3)	152 (111/41)
		98 VVC	2B: 123 (89/34)	
		3 RH	3: 21 (17/4)	

Abbreviations: AORI, Anderson Orthopaedic Research Institute; CR, cruciate retaining; F, femoral; No., number; n.s., not specified; PS, posterior stabilized; RH, rotating hinged; T, tibial; VVC, varus–valgus constrained.

Table 3 Postoperative complications

Author	Septic re-revision of the prosthetic components (loose sleeves)	Aseptic re-revision of the prosthetic components (loose sleeves)	Intraoperative fractures (surgical fixation)	Aseptic survival rate of the sleeves, %
Graichen et al ¹⁹	4 (0)	4 (4)	0	98
Huang et al ²⁰	6 (0)	3 (2)	0	98.3
Alexander ¹¹	0	0	0	100
Bugler et al ¹⁴	0	0	1 (0)	100
Barnett et al ¹²	1 (0)	3 (0)	1 (1)	100
Agarwal et al ¹⁰	2 (2)	0	0	100
Martin-Hernandez ²²	2 (0)	0	11 (0)	100
Chalmers et al ¹⁵	12 (0)	3 (2)	15 (2)	99.4
Fedorka et al ¹⁷	3 (3)	2 (2)	0	97.3
Watters et al ²³	6 (0)	10 (0)	3 (3)	99.3

Table 4 Clinical outcomes

Author	Preop	FU	Preop	FU	Preop	FU	Preop	FU	Preop	FU	Preop	FU	Preop	FU	Preop	FU	p-Value														
	OKS	OKS	KSS	KSS	Preop	FU	KSFS	KSFS	Preop	FU	SF12 PS	SF12 PS	Preop	FU	SF12 MS	SF12 MS	Preop	FU	SF36 PS	SF36 PS	Preop	FU	SF36 MS	SF36 MS	Preop	FU	WOMAC	WOMAC			
Graichenet al ¹⁹			36	78.2	52	68.8																								<0.01	
Huang et al ²⁰							47.9	61.1																						<0.001	
Alexander ¹¹			55.5	92	50	50 ^a																								<0.001	
Bugler et al ¹⁴	n.s.	34	n.s.	81.3	n.s.	58.1					n.s.	38.3																		/	
Barnett et al ¹²			41.6	88.7	41.7	75																								<0.001	
Agarwal et al ¹⁰	23	32	33	78	30	80																								<0.001	
Martin-Hernandez ²²			40	82	45	75					27	44																		<0.001	
Watters et al ²³																															<0.0001

Abbreviations: FU, follow-up; KSS, Knee Society Score; KSFS, Knee Society Function Score; n.s., not specified; OKS, Oxford Knee Score; Preop, preoperative; SF 12 PS, Short Form 12 Physical Score; SF 12 MS; Short Form 12 Mental Score; WOMAC, Western Ontario and McMaster Universities Arthritis Index.
^aNonsignificant.

due to the fact that metaphyseal sleeves have a high-volume porosity (50–80%),¹⁰ and this high porosity facilitates bone ingrowth in the metaphysis that is often preserved in revision TKA.^{16,19}

In the present review, moreover, the overall incidence of septic re-revision of the prosthetic components was 4%, which compares favorably with the infection rate (5–10%) reported when using allografts to fill bone defect in revision TKA.^{28–30} A possible explanation could be that using metaphyseal sleeves may considerably shorten operative times compared with allografting that is a time-consuming procedure.^{31–33}

The results of the present review show that the use of metaphyseal sleeves during revision TKA is associated with a low intraoperative fractures rate (3.1%). These fractures were associated with sleeve preparation and/or insertion, and most of them (86.3%) were not displaced and therefore did not require surgical treatment.^{12,14,15,22,23} Barnett et al¹² stated that broach-only preparation of the metaphysis is familiar to arthroplasty surgeons and easily reproducible; moreover, iatrogenic fracture during broaching is easily avoidable with careful preparation, similar to femoral canal preparation in hip arthroplasty.

Finally, good-to-excellent clinical outcomes at short- to midterm follow-up of patients who underwent revision TKA using metaphyseal sleeves to fill the bone loss has been reported in the studies included in this review (→Table 4). Bugler et al¹⁴ found that KSSs were good or excellent in 83% of patients (20% good, 63% excellent) at short-term follow-up (mean: 39 months, range: 24–62 months). Martin-Hernandez et al²² reported a statistically significant postoperative improvement of KSS, SF 12, SF 36, and WOMAC at a midterm follow-up (mean: 71.5 months, range: 36–107 months). This study has some limitations. First is the small number of patients analyzed in the majority of the published papers with the exceptions of four studies.^{15,19,22,23} Second, all the results reported were at short-term follow-up with a mean of 45 months (range: 24–144), except the studies of Fedorka et al,¹⁷ Martin-Hernandez et al,²² and Watters et al,²³ who reported a midterm outcome. However, as demonstrated by Schroer et al,³⁴ at least 50% of all re-revisions occur in the first 2 to 3 years. Hence, even after a short period of time, a strong tendency of the results can be seen as stated by Graichen et al.¹⁹ Third, all these articles lack a control group and randomized patient selection that reduces the level of evidence of the study.

In conclusion, the use of metaphyseal sleeves to handle large metaphyseal bone defect in the setting of revision TKA has been demonstrated to be a valuable option with a high osteointegration rate, low septic loosening rate, low intraoperative fractures rate, and good-to-excellent clinical outcome, at a mean follow-up of 45 months. Further studies are needed in a larger number of patients with longer follow-up to determine the survivorship and the long-term effectiveness of these titanium metaphyseal sleeves.

Conflict of Interest
None declared.

References

- 1 Kurtz S, Ong K, Lau E, Mowat F, Halpern M. Projections of primary and revision hip and knee arthroplasty in the United States from 2005 to 2030. *J Bone Joint Surg Am* 2007;89(04):780–785
- 2 Radnay CS, Scuderi GR. Management of bone loss: augments, cones, offset stems. *Clin Orthop Relat Res* 2006;446(446):83–92
- 3 Vasso M, Beaufils P, Cerciello S, Schiavone Panni A. Bone loss following knee arthroplasty: potential treatment options. *Arch Orthop Trauma Surg* 2014;134(04):543–553
- 4 Haidukewych GJ, Hanssen A, Jones RD. Metaphyseal fixation in revision total knee arthroplasty: indications and techniques. *J Am Acad Orthop Surg* 2011;19(06):311–318
- 5 Ponzio DY, Austin MS. Metaphyseal bone loss in revision knee arthroplasty. *Curr Rev Musculoskelet Med* 2015;8(04):361–367
- 6 Bonanzinga T, Gehrke T, Zahar A, Zaffagnini S, Marcacci M, Haasper C. Are trabecular metal cones a valid option to treat metaphyseal bone defects in complex primary and revision knee arthroplasty? *Joints* 2017;6(01):58–64
- 7 Brown NM, Bell JA, Jung EK, Sporer SM, Paprosky WG, Levine BR. The use of trabecular metal cones in complex primary and revision total knee arthroplasty. *J Arthroplasty* 2015;30(09(suppl)):90–93
- 8 Derome P, Sternheim A, Backstein D, Malo M. Treatment of large bone defects with trabecular metal cones in revision total knee arthroplasty: short term clinical and radiographic outcomes. *J Arthroplasty* 2014;29(01):122–126
- 9 Kamath AF, Lewallen DG, Hanssen AD. Porous tantalum metaphyseal cones for severe tibial bone loss in revision knee arthroplasty: a five to nine-year follow-up. *J Bone Joint Surg Am* 2015;97(03):216–223
- 10 Agarwal S, Azam A, Morgan-Jones R. Metal metaphyseal sleeves in revision total knee replacement. *Bone Joint J* 2013;95-B(12):1640–1644
- 11 Alexander GE, Bernasek TL, Crank RL, Haidukewych GJ. Cementless metaphyseal sleeves used for large tibial defects in revision total knee arthroplasty. *J Arthroplasty* 2013;28(04):604–607
- 12 Barnett SL, Mayer RR, Gondusky JS, Choi L, Patel JJ, Gorab RS. Use of stepped porous titanium metaphyseal sleeves for tibial defects in revision total knee arthroplasty: short term results. *J Arthroplasty* 2014;29(06):1219–1224
- 13 Barrack RL. Evolution of the rotating hinge for complex total knee arthroplasty. *Clin Orthop Relat Res* 2001;(392):292–299
- 14 Bugler KE, Maheshwari R, Ahmed I, Brenkel IJ, Walmsley PJ. Metaphyseal sleeves for revision total knee arthroplasty: good short-term outcomes. *J Arthroplasty* 2015;30(11):1990–1994
- 15 Chalmers BP, Desy NM, Pagnano MW, Trousdale RT, Taunton MJ. Survivorship of metaphyseal sleeves in revision total knee arthroplasty. *J Arthroplasty* 2017;32(05):1565–1570
- 16 Dalury DF, Barrett WP. The use of metaphyseal sleeves in revision total knee arthroplasty. *Knee* 2016;23(03):545–548
- 17 Fedorka CJ, Chen AF, Pagnotto MR, Crossett LS, Klatt BA. Revision total knee arthroplasty with porous-coated metaphyseal sleeves provides radiographic ingrowth and stable fixation. *Knee Surg Sports Traumatol Arthrosc* 2018;26(05):1500–1505
- 18 Gøttsche D, Lind T, Christiansen T, Schröder HM. Cementless metaphyseal sleeves without stem in revision total knee arthroplasty. *Arch Orthop Trauma Surg* 2016;136(12):1761–1766
- 19 Graichen H, Scior W, Strauch M. Direct, cementless, metaphyseal fixation in knee revision arthroplasty with sleeves-short-term results. *J Arthroplasty* 2015;30(12):2256–2259
- 20 Huang R, Barrazaeta G, Ong A, et al. Revision total knee arthroplasty using metaphyseal sleeves at short-term follow-up. *Orthopedics* 2014;37(09):e804–e809
- 21 Jones RE, Skedros JG, Chan AJ, Beauchamp DH, Harkins PC. Total knee arthroplasty using the S-ROM mobile-bearing hinge prosthesis. *J Arthroplasty* 2001;16(03):279–287
- 22 Martin-Hernandez C, Floria-Arnal LJ, Muniesa-Herrero MP, et al. Mid-term results for metaphyseal sleeves in revision knee surgery. *Knee Surg Sports Traumatol Arthrosc* 2017;25(12):3779–3785
- 23 Watters TS, Martin JR, Levy DL, Yang CC, Kim RH, Dennis DA. Porous-coated metaphyseal sleeves for severe femoral and tibial bone loss in revision TKA. *J Arthroplasty* 2017;32(11):3468–3473
- 24 Nadorf J, Kinkel S, Gantz S, Jakubowitz E, Kretzer JP. Tibial revision knee arthroplasty with metaphyseal sleeves: the effect of stems on implant fixation and bone flexibility. *PLoS One* 2017;12(05):e0177285
- 25 Mason JB, Fehring TK. Removing well-fixed total knee arthroplasty implants. *Clin Orthop Relat Res* 2006;446(446):76–82
- 26 Engh GA, Ammeen DJ. Bone loss with revision total knee arthroplasty: defect classification and alternatives for reconstruction. *Instr Course Lect* 1999;48:167–175
- 27 Moher D, Cook DJ, Eastwood S, Olkin I, Rennie D, Stroup DF. Improving the quality of reports of meta-analyses of randomised controlled trials: the QUOROM statement. *Onkologie* 2000;23(06):597–602
- 28 Clatworthy MG, Ballance J, Brick GW, Chandler HP, Gross AE. The use of structural allograft for uncontained defects in revision total knee arthroplasty. A minimum five-year review. *J Bone Joint Surg Am* 2001;83(03):404–411
- 29 Hilgen V, Citak M, Vettorazzi E, et al. 10-year results following impaction bone grafting of major bone defects in 29 rotational and hinged knee revision arthroplasties: a follow-up of a previous report. *Acta Orthop* 2013;84(04):387–391
- 30 Lotke PA, Carolan GF, Puri N. Impaction grafting for bone defects in revision total knee arthroplasty. *Clin Orthop Relat Res* 2006;446(446):99–103
- 31 Lachiewicz PF, Bolognesi MP, Henderson RA, Soileau ES, Vail TP. Can tantalum cones provide fixation in complex revision knee arthroplasty? *Clin Orthop Relat Res* 2012;470(01):199–204
- 32 Mabry TM, Hanssen AD. The role of stems and augments for bone loss in revision knee arthroplasty. *J Arthroplasty* 2007;22(04, Suppl 1):56–60
- 33 Naim S, Toms AD. Impaction bone grafting for tibial defects in knee replacement surgery. Results at two years. *Acta Orthop Belg* 2013;79(02):205–210
- 34 Schroer WC, Berend KR, Lombardi AV, et al. Why are total knees failing today? Etiology of total knee revision in 2010 and 2011. *J Arthroplasty* 2013;28(08 suppl):116–119