

Cardiac Surgery in a Patient with Implanted Vagal Nerve Stimulator

Abstract

The prevalence of epilepsy worldwide is around 0.5%–2% of the population. Antiepileptic medications are the first line of treatment in most of the cases but approximately 25%–30% epilepsy patients are refractory to the single or combination therapy. The surgical option for temporal lobe epilepsy is temporal lobectomy, which has its inherent risk of neurological deficits after the surgery. Patients who are either refractory to combination therapy or do not want surgical temporal lobectomy are the candidates for electrical stimulation therapy. Refractory cases require implantable device such as vagal nerve stimulator (VNS). We are reporting perioperative management of a patient, with an implanted VNS, posted for pericardiectomy. It is important for the anesthesiologist to be familiar with the mechanism of VNS for proper perioperative care.

Keywords: Cardiac surgery, epilepsy, pericardiectomy, vagal nerve stimulator

Introduction

Patients with seizure disorders, posted for various surgical interventions are not uncommon. Most of the patients are managed with antiepileptic medications as a single or combination therapy and if the patients are refractory to medical treatment or with a history of partial seizures, are considered for surgical temporal lobectomy.^[1] Most of the patients get benefitted by these options. However, as much as 20–30% patients are refractory to combination antiepileptic therapy worldwide and due to the inherent risk of neurological deficits some patients do not want to opt for the surgical option.^[2] These are the patients for electrical nerve stimulation therapy. In 1997, US FDA has approved vagal nerve stimulation (VNS) therapy and it is still being used as only approved device for long-term seizures control in patients who are either refractory to the combination antiepileptic therapy or not willing for surgical options for the seizures control.^[3]

For an anesthetist, these patients are often first encountered during their preanesthetic visit. The anesthetist needs to be familiar with the device functions and its perioperative considerations in such patients. We are reporting a case with a history of seizures on multiple antiepileptic medications. Due to the poor compliance to the antiepileptic medications because of

This is an open access article distributed under the terms of the Creative Commons Attribution-NonCommercial-ShareAlike 3.0 License, which allows others to remix, tweak, and build upon the work non-commercially, as long as the author is credited and the new creations are licensed under the identical terms.

For reprints contact: reprints@medknow.com

his cognitive dysfunctions, he required an implantable VNS device earlier and now posted for pericardiectomy surgery in our institution.

Case Report

A 22-year-old male patient, known case of seizure disorders, cognitive impairment, and hypothyroidism, diagnosed to have constrictive pericarditis. He was on treatment with multiple antiepileptic medications and implanted VNS for seizure control. After a detailed preoperative anesthesia checkup, a neurology, neuropsychiatry consultation was advised to get an advice to deal with a patient on VNS, Cyberonics, Inc., (NASDAQ: CYBX) during the perioperative period. He was posted for an elective pericardiectomy surgery. During the history, tuberculosis, as one of the most common causes for constrictive pericarditis has been ruled out.

His 2D echocardiography revealed, thickened calcific pericardium involving right ventricle free wall and along inferolateral wall, presence of septal bounce, restrictive left ventricular filling, dilated inferior vena cava, central venous pressure approximately 15 mmHg, prominent expiratory diastolic flow reversal in hepatic veins normal right and left ventricle systolic functions and pulsus paradoxus, which supported the diagnosis of constrictive pericarditis. His hematology, biochemistry, and thyroid functions were within normal limits. On

How to cite this article: Jain A, Arora D, Mehta Y. Cardiac surgery in a patient with implanted vagal nerve stimulator. *Ann Card Anaesth* 2018;21:57-9.

**Aashish Jain,
Dheeraj Arora,
Yatin Mehta**

*Medanta Institute of Critical
Care and Anesthesiology,
Medanta The Medicity,
Gurugram, Haryana, India*

Address for correspondence:

*Dr. Aashish Jain,
Institute of Critical Care and
Anesthesiology, Medanta The
Medicity, Gurugram, Haryana,
India.
E-mail: aashishjain29@gmail.
com*

Access this article online

Website: www.annals.in

DOI: 10.4103/aca.ACA_108_17

Quick Response Code:



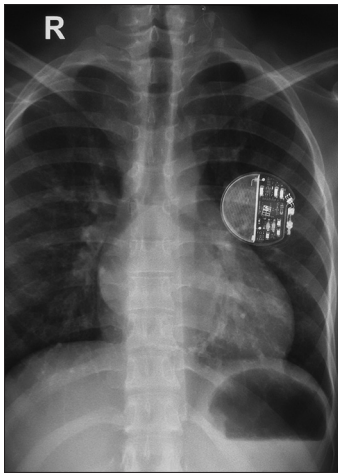


Figure 1: Chest radiograph showing VNS device (VNS= Vagal nerve stimulator)

viewing the chest X-ray along with the cardiopulmonary findings, it was found that the device is located in the left infraclavicular area [Figure 1]. Moreover, to add confusion at a first glance, it was easy to appreciate it as a pacemaker, unless the history and other details were known.

Neuropsychiatry consultation was taken for his mental retardation and it was described as “cognitive dysfunction” in which patient has an incapacity to sign the consent, despite being major from the age, and therefore in this case, all the consents was signed by the relatives.

Neurology consultation was taken, to know the precautions for safe handling of the device during and after surgery. As per the neurologist, the device needed to be reprogrammed and stopped before the surgery so the electromechanical interference with the cautery could have minimized. It was also advised by the neurologist, to consider the use of only bipolar cautery during the surgery. The use of bipolar cautery can be easily accepted in any other surgery but in cardiac surgery, monopolar cautery is required for an effective hemostasis from the sternotomy and intrathoracic sites. The monopolar cautery can disturb the functioning of the vagus nerve stimulator device, and therefore, it is important not only to reprogram the device but also to keep the cautery pads as far as possible from the device implantation site. Similarly, at the end of surgery, the device should be reprogrammed to its preprocedural mode so that it can continue to deliver the benefits to the patient, it is intended for.

Usually, a well-controlled patient on antiepileptic medications can be managed according to a routine protocol but, if a patient is on implanted VNS, it requires familiarity with the device functioning and its perioperative implications. The aim of knowing the mechanism of VNS functioning is to keep the perioperative period uneventful.

In our case, whole perioperative period remained uneventful and after an adequate recovery, the patient was discharged

on the same antiepileptic medications with the VNS mode resumed as it was in the preoperative period.

Discussion

As defined by International League Against Epilepsy and the International Bureau for Epilepsy, epilepsy is now called a disease, rather than a disorder. It is estimated to be present in 0.5%–2% of the world population.^[2] Approximately, one-third of the patients with epilepsy are refractory to even the polytherapy, which is highly devastating to the patients and affects numerous aspects of life. The seriousness of epilepsy as a disease lies often need of multiple antiepileptic medications for seizure control and as much as surgical temporal lobectomy, often a last resort. There is a risk involved in the neurological deficits, postsurgical temporal lobectomy, and therefore, many patients are not willing to opt the surgical option.^[3] Such candidates are often poorly controlled on multiple antiepileptic medications and if patient’s compliance is poor, the risk of irregular intake of medications also increases. For these reasons, other options to treat medically refractory epilepsy have been explored. One of such battery-operated device is VNS. Just like a pacemaker, the device is also implanted for long-term seizures control and currently the only US FDA approved implantable device for long-term seizures control.^[4]

Mechanism of functioning of VNS

Exact mechanism is unknown but most likely mechanism involves amygdala where the limbic system is responsible for spontaneous seizure activity. Stimulation of these areas through vagal afferents reduces spontaneous seizure activity.

Vagus nerve is X cranial nerve and derive its name from a Latin word for wanderer. Vagal nerve contains both afferent and efferent fibers and travels throughout the head, neck, thorax, and abdominopelvic regions. VNS is placed in the neck, at a site, where afferent vagal fibers are most abundant and thereby the VNS device works by stimulation of the vagal afferent fibers.^[5]

The afferent vagal fibers traverse the brain stem and most noticeably synapse with the nucleus tractus solitarius (NTS). The NTS projects to the noradrenergic and serotonergic neuro-modulatory systems. Stimulation of these fibers exerts antiseizure effect mediated by norepinephrine and epinephrine.

The stimulation characteristics as recommended by the FDA describes as follows.

Stimulation frequencies

Stimulation frequencies are kept between 20 and 30 Hz. Lower frequencies are associated with reduced stimulation while higher frequencies are associated with the risk of vagal nerve fibers damage.

Current intensity

The current intensity of the stimulator is effective between 0.8 and 2 mA. Young children require higher current intensity, which can be gradually achieved by increasing the intensity by 0.25 mA every 1–2 week.

Stimulation-induced side effects may increase with rising current delivery. The pulse width increases with increasing current intensity. The usual pulse-width settings include 500 and 250 μ s. Increase of the pulse width leads to increased delivery of current although this increase is not linear.

Stimulation intervals

Consist of a 30 s on and a 5 min off period. Duty cycles should not exceed 50% of the complete stimulation paradigm to prevent nerve injury.

Waveform

Biphasic stimulation with balanced anodal and cathodal waveforms is recommended to avoid accumulation and leakage of current.

Anesthetic implications in a patient with VNS

In a small study, it was found that approximately one-third of the patients on refractory medical therapy for the epilepsy has symptoms of obstructive sleep apnea (OSA). It has been suggested in the study that the VNS therapy may worsen the OSA symptoms during stimulation intervals. The mechanism involved is mediated by both the central respiratory centers and the stimulation of the peripheral vagal afferent fibers by activating motor efferent fibers. As a result of this, there is an altered neuromuscular transmission to the laryngeal and pharyngeal muscles.

Use of opioids in a patient with implanted VNS may lead to exaggerated respiratory depression or severe postoperative apneic episodes.^[6,7] It is therefore important to obtain a thorough history regarding sleep and respiratory patterns. A neurologist's consultation is prudent before preoperative reprogramming or turning off the VNS. This can help in reducing apneic episodes in postoperative period due to the VNS-mediated altered neuromuscular transmission in laryngeal and pharyngeal muscles. In a patient at risk of exaggerated respiratory depression anesthetic technique can be modified by administering titrated doses of opioids rather than the doses commonly used for narcotic induction.

Similar to the pace maker, the VNS device manipulation requires use of a magnet, which is supplied by the manufacturer as a watch or a pager. The device manipulation must involve a neurologist consultation. The magnet delivers 50G force at 1" distance from the device. By keeping the magnet close to the device for 1 s and removed immediately delivers an on-demand stimulus for a preprogrammed time, which reduces the intensity or abort

the ongoing seizure episode. If the magnet is kept for more than 65 s, it turns off the device. The device returns to the normal, once the magnet is removed.^[3]

Similar to a pacemaker, the pulse generator of a VNS may be damaged by electrocautery and cardioversion/defibrillation.^[5] If defibrillation is required, the lowest setting should be used and the pads placed as far away from the generator as possible. In addition, the grounding pad from the electrocautery unit should be placed so that current does not travel through the device.

Summary

Patients with implanted devices pose different anesthetic challenges. The anesthetists need to be familiar with the device mechanism, needs of reprogramming, use of magnet, and considerations related to cautery and the use of defibrillator. Identification of a VNS device also important as it can be easily confused with an implanted pacemaker by seeing its position and appearance in an X-ray film. A thorough history from the patient and a preoperative neurological consultation before device manipulation to prevent the postoperative apneic spells is crucial before delivering anesthesia in such patients.^[3] Anesthesia technique should be modified to avoid postoperative respiratory depression. A postoperative reprogramming of the device is also equally important to make a safe discharge of the patient from the hospital.

Financial support and sponsorship

Nil.

Conflicts of interest

There are no conflicts of interest.

References

1. Kelly KM, Chung SS. Surgical treatment for refractory epilepsy: Review of patient evaluation and surgical options. *Epilepsy Res Treat* 2011;2011:303624.
2. Linda Dalic, Mark J Cook. Managing drug-resistant epilepsy: challenges and solutions. *Neuropsychiatric Disease and Treatment*. 2016; 12:2605–16.
3. David Higgins, David Dix, Michelle E. Gold. Vagal nerve stimulation: A case report. *ANNA Journal*. 2010;78:146-150. Available from: <http://www.aana.com/aanajournalonline.aspx>. [Last accessed on 2017 Sep 20].
4. Peter Widdess-Walsh, Christoph Kaellinghaus, Eric Geller, Frank Bosebeck, Stephan Shuele, Tobias Loddenkemper, *et al.* Efficacy of electrical brain stimulation in epilepsy. *Therapy* 2010;7:481-96.
5. Hatton KW, McLarney JT, Pittman T, Fahy BG. Vagal nerve stimulation: Overview and implications for anesthesiologists. *Anesth Analg* 2006;103:1241-9.
6. Hatton KW, McLarney JT, Pittman T, Fahy BG. Vagal nerve stimulation: Overview and implications for anesthesiologists. *Anesth Analg* 2006;103:1241-9.
7. Malow BA, Levy K, Maturen K, Bowes R. Obstructive sleep apnea is common in medically refractory epilepsy patients. *Neurology* 2000;55:1002-7.