

This is an Open Access article licensed under the terms of the Creative Commons Attribution-NonCommercial 3.0 Unported license (CC BY-NC) ([www.karger.com/OA-license](http://www.karger.com/OA-license)), applicable to the online version of the article only. Distribution permitted for non-commercial purposes only.

# Repeat Descemetopexy after Descemet's Membrane Detachment following Phacoemulsification

Sameer Datar Aditya Kelkar Ashish K. Jain Jai Kelkar  
Shreekant Kelkar Poonam Gandhi Rachna Shah Ruchika Kedia

National Institute of Ophthalmology, Pune, India

## Key Words

Repeat descemetopexy · Descemet's membrane detachment · C3F8 gas

## Abstract

Descemet's membrane detachment (DMD) is an uncommon condition with a wide range of possible etiologies. Probably the commonest cause is a localized detachment occurring after cataract extraction surgery. Descemetopexy gives good anatomic attachment rates and visual outcomes and has become the standard treatment for DMD. However, in cases with failed initial descemetopexy, the next step in the management of such cases remains unclear. Before initiating a complex surgical procedure like keratoplasty, which requires good postoperative care and regular follow-ups, repeat descemetopexy with a long-term tamponade using 14% C3F8 gas for recurrent DMD is definitely a worthwhile attempt.

© 2014 S. Karger AG, Basel

## Introduction

Descemet's membrane detachment (DMD) is an uncommon condition with a wide range of possible etiologies. Probably the commonest cause is a localized detachment occurring after cataract extraction surgery [1]. Nonsurgical factors that could predispose to DMD are traumatic, congenital glaucoma and corneal ectasias, among others. DMD can be classified as: (1) planar: <1 mm separation from the stroma (peripheral detachment only; combined peripheral and central detachment) or (2) nonplanar: >1 mm separation from the stroma (peripheral detachment only; combined peripheral and central detachment) [2].

Several mechanisms have been proposed as the possible causal mechanism for DMD: shallow chambers, complicated or repeated operations, inadvertent insertion of instruments

Dr. Aditya Kelkar  
National Institute of Ophthalmology  
1187/30 Off Ghole Road  
Shivajinagar, Pune 411005 (India)  
E-Mail [adityapune4@gmail.com](mailto:adityapune4@gmail.com)

between the corneal stroma and Descemet's membrane, anterior and shelved incisions, and the use of dull blades [3]. Engaging Descemet's membrane during intraocular lens implantation or with the irrigation/aspiration device (when mistaken as an anterior capsular remnant) can also lead to extensive DMD. Reports of inadvertent injection of viscoelastic material by inserting the cannula between Descemet's membrane and the corneal stroma may be the most common cause of DMD with the current surgical techniques [4].

We report a successful management of a case of recurrent DMD by repeat descemetopexy with 14% C3F8 gas [5, 6].

## Case Report

A 71-year-old hypermetropic woman presented with complaints of diminished vision in her left eye, with a best-corrected visual acuity of 20/40 in her right eye and of 20/200 in her left eye. On slit lamp examination, the patient had nuclear sclerosis (grade II). Corneal status and intraocular pressure were within normal limits in both eyes, and the fundus revealed mild nonproliferative diabetic retinopathy. The anterior chamber depth in her left eye was found to be 2.12 mm.

Under topical anesthesia, a clear corneal 2.8-mm incision and two side ports were made at 3 and 9 o'clock. A peristaltic pump-based (SOVEREIGN® Compact system ELLIPS® FX) phacoemulsification was done. A foldable posterior chamber intraocular lens (TECNIS® 1-piece) was implanted. Hydroxypropyl methylcellulose 2% (Appavisc®) was used during the procedure. Low ultrasound energy (5%) was used with an effective phacoemulsification time of 3 s.

On day 1, the patient came with vision of counting fingers close to the face with diffuse corneal edema. DMD was noted as a continuation of the side port incision extending to involve the visual axis which was confirmed on anterior segment optical coherence tomography (OCT) (fig. 1a). The patient was advised a 100% air injection. Pros and cons of the air injection and other treatment options including no treatment were discussed. After obtaining an informed written consent, 1 drop of 1% pilocarpine was administered preoperatively half an hour before the procedure. 0.3 ml of 100% air was injected with a 26-gauge needle in the operating theater under all aseptic precautions and topical anesthesia. After 10 min, partial air-fluid exchange was done. The patient was advised to lie down in a supine position for the next 1 h. The intraocular pressure on discharge was 26 mm Hg, and the patient was started on acetazolamide 250 mg three times a day for 3 days. The patient was also started on topical 0.5% moxifloxacin eyedrops and 1% prednisolone acetate eyedrops three times a day for 14 days, and monitored for intraocular pressure daily.

On day 1 after air injection, Descemet's membrane was attached with an air bubble in the anterior chamber (fig. 1b). On day 4, the air bubble was reduced significantly and DMD was noted again, involving the visual axis. Considering the recurrent nature of the DMD, a long-term tamponade with 14% C3F8 gas was planned. Pros and cons of the treatment and other treatment options including no treatment were discussed. Written informed consent was obtained. One drop of 1% pilocarpine was administered half an hour before the procedure. 0.1 ml of 14% C3F8 gas was injected with a 26-gauge needle. The patient was advised to lie down in a supine position for the next 1 h. The intraocular pressure on discharge was 28 mm Hg, and the patient was started on acetazolamide 250 mg three times a day for 3 days. The patient was also started on topical 0.5% moxifloxacin eyedrops and 1% prednisolone acetate eyedrops three times a day for 14 days. On day 1 and day 8 after gas injection, her vision was counting fingers close to the face and a gas bubble was noted in the anterior chamber with clear cornea and a completely attached Descemet's membrane.

Datar et al.: Repeat Descemetopexy after Descemet's Membrane Detachment following Phacoemulsification

On day 14 after gas injection, her vision was finger counting at 2 m; Descemet's membrane was completely reattached and the cornea was clear. On the subsequent follow-up, the gas bubble was completely absorbed, the anterior chamber was well formed, the cornea was clear and Descemet's membrane was attached. The vision improved to 20/40 at 2 months and anterior segment OCT (fig. 1c) shows Descemet's membrane being attached.

## Discussion

DMD is a rare but potentially vision-threatening complication of cataract surgery [7]. The incidence of DMD varies between 0.5 and 2.6%, intraoperatively or postoperatively following cataract surgery [2].

Planar detachment involving the periphery does not interfere with the visual acuity and does not require intervention in most cases. However, in nonplanar detachments and those involving the central area, the treatment requires aggressive therapy. The mean time for resolution of DMD with medical treatment alone was reported to be 9.8 weeks with a high failure rate of 46.67% [8]. Thus the spontaneous reattachment with a medical line of treatment is reported to be prolonged, unpredictable, and can lead to fibrosis, shrinkage, and wrinkling of the detached Descemet's membrane, which might prevent reattachment and necessitate endothelial transplantation [3]. Keratoplasty has its own inherent limitations, such as nonavailability of corneal tissue, requirement of a long follow-up, and risk of rejection and infection [4, 9]. On the other hand, descemetopexy gives good anatomic attachment rates and visual outcomes [10]. The success rates with intracameral injections have been reported to be 90–95% [3, 6, 10]. However, in rare cases with failed initial descemetopexy, the next step in the management of such cases remains unclear.

Jain and Mohan [11] reported a high success rate of 12 out of 13 (92.30%) cases with an attached Descemet's membrane who had undergone repeat descemetopexy after a failed initial procedure following cataract surgery DMD. One case developed postoperative pupillary block and one case required endothelial transplantation.

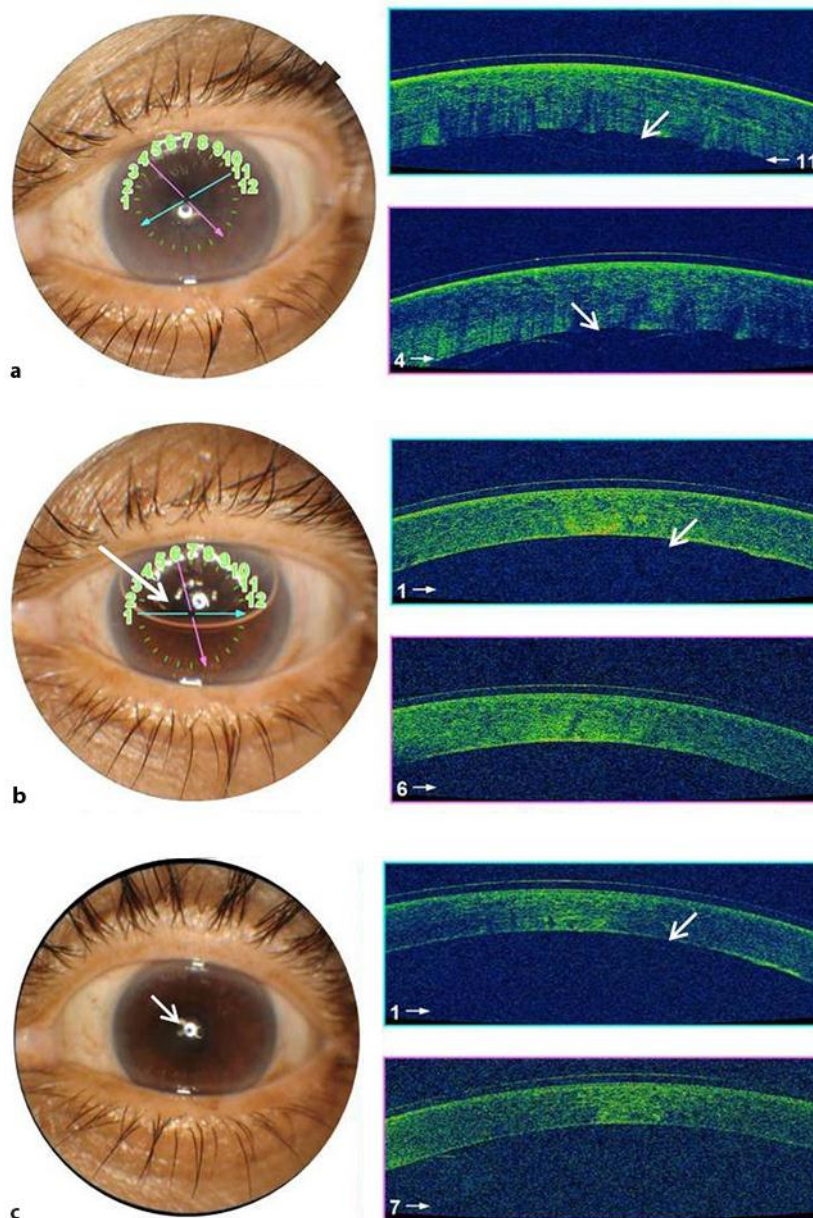
In our patient, the injection of 100% air given on the second postoperative day initially attached Descemet's membrane; however, it got detached again on the 4th postoperative day following absorption of the air bubble. Considering the recurrent nature of the detachment, a long-term tamponade was considered necessary. Hence longer-acting (2–3 weeks) 14% C3F8 gas was injected.

Before initiating a complex surgical procedure like keratoplasty, which requires good postoperative care and regular follow-ups, repeat descemetopexy with a long-term tamponade using 14% C3F8 gas for recurrent DMD is definitely a worthwhile attempt.

## References

- 1 Anderson CJ: Gonioscopy in no-stitch cataract incisions. *J Cataract Refract Surg* 1993;19:620–621.
- 2 Mulhern M, Barry P, Condon P: A case of Descemet's membrane detachment during phacoemulsification surgery. *Br J Ophthalmol* 1996;80:185–186.
- 3 Mahmood MA, Teichmann KD, Tomey KF, al-Rashed D: Detachment of Descemet's membrane. *J Cataract Refract Surg* 1998;24:827–833.
- 4 Suh LH, Yoo SH, Deobhakta A, et al: Complications of Descemet stripping with automated endothelial keratoplasty survey of 118 eyes at one institute. *Ophthalmology* 2008;115:1517–1524.
- 5 Macsai MS, Gainer KM, Chisholm L: Repair of Descemet's membrane detachment with perfluoropropane. *Cornea* 1998;17:129–134.
- 6 Potter J, Zalatimo N: Descemet's membrane detachment after cataract extraction. *Optometry* 2005;76:720–724.
- 7 Makley TA Jr, Keates RH: Detachment of Descemet membrane (an early complication of cataract surgery). *Ophthalmic Surg* 1980;11:189–191.

- 8 Marcon AS, Rapuano CJ, Jones MR, Laibson PR, Cohen EJ: Descemet's membrane detachment after cataract surgery: management and outcome. *Ophthalmology* 2002;109:2325–2330.
- 9 Wu EI, Ritterband DC, Yu G, Shields RA, Seedor JA: Graft rejection following Descemet stripping automated endothelial keratoplasty: features, risk factors, and outcomes. *Am J Ophthalmol* 2012;153:949–957.
- 10 Jain R, Murthy SI, Basu S, Ali MH, Sangwan VS: Anatomic and visual outcomes of descemetopy in post-cataract surgery. Descemet membrane detachment. *Ophthalmology* 2013;120:1366–1372.
- 11 Jain R, Mohan N: Outcomes of repeat descemetopy in post-cataract surgery Descemet membrane detachment. *Am J Ophthalmol* 2014;157:571–575.



**Fig. 1.** **a** Anterior segment OCT done on day 1 after cataract surgery showing DMD. **b** Anterior segment OCT done on day 1 after injection showing Descemet's membrane attachment with an air bubble in the anterior segment. **c** Two months postoperatively, anterior segment OCT showing Descemet's membrane attached with no corneal edema.