

A Case of Takayasu Arteritis with Thrombotic Microangiopathy Secondary to Malignant Hypertension Due to Bilateral Renal Artery Stenosis

Ege Sinan Torun¹, Nevzat Koca², Yasemin Yalçınkaya², Bahar Artım Esen², Ahmet Gül², Murat İnanç²

¹Division of Rheumatology, Department of Internal Medicine, Prof. Dr. Cemil Taşcıoğlu City Hospital, Istanbul, Turkey; ²Division of Rheumatology, Department of Internal Medicine, Istanbul Faculty of Medicine, Istanbul University, Istanbul, Turkey

Correspondence: Ege Sinan Torun, Prof. Dr. Cemil Taşcıoğlu City Hospital, Kaptan Paşa, SSK Okmeydanı Hst. No: 25, Şişli, İstanbul, 34384, Turkey, Tel +90-537 229 17 99, Email egesinantorun@hotmail.com

Abstract: A 20 year old woman presented with right arm pain. Pulses of right upper extremity were weak, acute phase reactants were elevated and MR angiography demonstrated total occlusion of subclavian artery and right axillary artery with collaterals. The diagnosis was Takayasu arteritis and she was treated with prednisolone, azathioprine and acetylsalicylic acid. During follow up, azathioprine was switched to methotrexate. Three years later, patient presented with elevated blood pressure. CT angiography demonstrated reduced calibration of the aorta and almost total occlusion of the lumen of proximal parts of left and right renal arteries. C-reactive protein was elevated. Steroid dose was increased, methotrexate was discontinued and IV tocilizumab and antihypertensive medications were initiated. One month later, she presented to emergency department with elevated blood pressure and blurred vision in the left eye. Fundoscopic examination revealed bilateral grade 3 hypertensive retinopathy and serous detachment of retina in the left eye. Laboratory results revealed normal CRP, elevated creatinine, elevated lactate dehydrogenase, thrombocytopenia, low hemoglobin and low haptoglobin. Peripheral blood smear revealed 2–3 schistocytes in every field. She was admitted to rheumatology department with the diagnosis of thrombotic microangiopathy secondary to malignant hypertension. IV tocilizumab was administered, and methylprednisolone was maintained at a dose of 20 mg/day. Despite treatment with maximum dose of six antihypertensive medications, her blood pressure was not controlled adequately and she became hypervolemic. After undergoing ultrafiltration, balloon dilation was performed in the left renal artery, and a stent was placed there. After stent placement, creatinine and platelet count normalized, hemoglobin increased and hypertension was controlled. In this case, malignant hypertension which was triggered by bilateral renal artery stenosis due to Takayasu arteritis had caused acute kidney injury and advanced stage hypertensive retinopathy. In addition, unlike other Takayasu arteritis cases with malignant hypertension, thrombotic microangiopathy was also detected.

Keywords: Takayasu arteritis, malignant hypertension, thrombotic microangiopathy

Introduction

Takayasu arteritis (TA) is an idiopathic, granulomatous, large-vessel arteritis that predominantly involves the aorta and its major branch arteries.¹ It can cause a wide variety of clinical manifestations depending on the involved vessels. When renal arteries are involved patients may present with renal failure or renovascular hypertension.² We hereby present a case of Takayasu arteritis that caused bilateral renal artery stenosis. This bilateral renal artery stenosis caused the patient to present with malignant hypertension. The clinical picture was further complicated by thrombotic microangiopathy that developed secondary to malignant hypertension.

Case

A 20 year old woman presented with pain in the right arm that increased with movement. Her physical examination demonstrated weak pulses in the right radial artery and right brachial artery. Her complete blood count was normal, creatinine was 0.8 mg/dl, but erythrocyte sedimentation rate was 50 mm/hour and C-reactive protein was 35 mg/l. MR

angiography revealed total occlusion of a 15 cm segment extending from the distal part of subclavian artery to right axillary artery and to the proximal part of right brachial artery, and collaterals extending to the distal part of right brachial artery. Presence of these findings together with the other test results ruled out other pathologies that were in the differential diagnosis and a diagnosis of Takayasu arteritis was established. She was treated with prednisolone, azathioprine and acetylsalicylic acid. During follow up, pancytopenia occurred, which rapidly normalized upon discontinuation of azathioprine. After discontinuation of azathioprine, she was treated with methotrexate, which did not cause any cytopenias.

Three years later, patient presented to our department with elevated blood pressure. Blood pressure was 170/110 mm Hg in the left arm and 130/100 mm Hg in the right arm. Fundoscopic examination revealed bilateral grade 1 hypertensive retinopathy. Her creatinine was 1.1 mg/dl and C-reactive protein was 30 mg/l. Abdominal CT angiography demonstrated reduced calibration of the aorta and increased wall thickness at the level of renal arteries, almost total occlusion of the lumen of proximal 1.5 cm segment of left renal artery starting from the level of ostium (Figure 1) and almost total occlusion of the lumen of proximal 3 cm segment of right renal artery starting from the level of ostium (Figure 2). She received 32 mg methylprednisolone (with a gradual tapering regimen). Methotrexate was discontinued and she received the first dose of IV tocilizumab (at a dose of 8 mg/kg/month). She received nebivololol, amlodipine and doxazosin as antihypertensive medications and was discharged from the hospital.

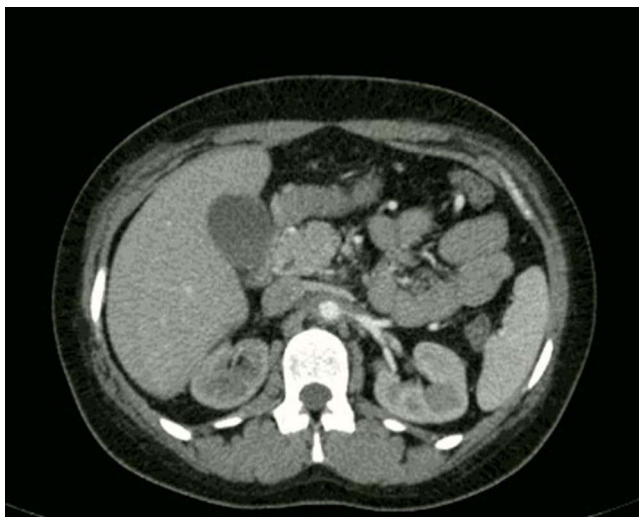


Figure 1 Almost total occlusion of the lumen of proximal 1.5 cm segment of left renal artery, starting from the level of ostium.

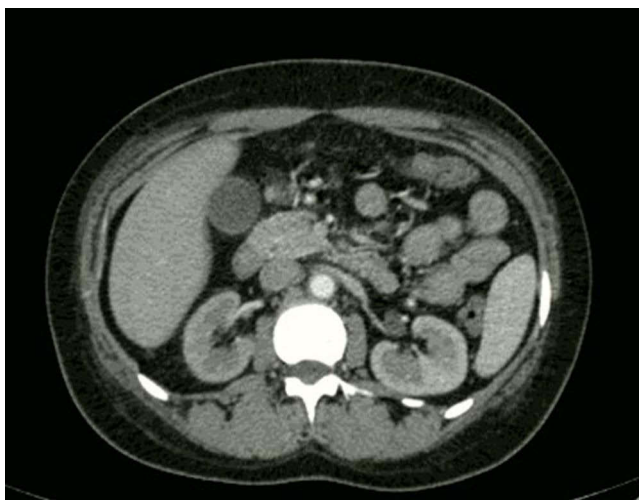


Figure 2 Almost total occlusion of the lumen of proximal 3 cm segment of right renal artery, starting from the level of ostium.

One month after discharge, she presented to the emergency department with blurred vision in the left eye. Blood pressure was 190/100 in the left arm and 150/90 in the right arm. Fundoscopic examination revealed bilateral grade 3 hypertensive retinopathy and serous detachment of retina in the left eye. Laboratory results revealed normal C-reactive protein, elevated creatinine (1.4 mg/dl), elevated lactate dehydrogenase (706 U/l), thrombocytopenia ($88,000/\text{mm}^3$), low hemoglobin (9.82 g/dl) and low haptoglobin (<10 mg/dl). Peripheral blood smear revealed 2–3 schistocytes in every field. She was admitted to the rheumatology department with the diagnosis of thrombotic microangiopathy secondary to malignant hypertension.

Due to the presence of overt bilateral renal artery stenosis secondary to Takayasu arteritis, additional workup for secondary hypertension (such as aldosterone levels and plasma renin activity) was not performed. In order to adequately control the disease activity, second dose of IV tocilizumab was administered and methylprednisolone dose was maintained at a dose of 20 mg/day. Tocilizumab was not switched to another biologic agent because it was only the second dose of tocilizumab and disease progression which caused bilateral renal artery stenosis had occurred under methotrexate treatment. Dose of the antihypertensives was increased and new antihypertensives were initiated. Despite treatment with maximum doses of carvedilol, doxazosin, amlodipine, IV furosemide, isosorbide mononitrate and moxonidine her blood pressure was not controlled adequately. Her creatinine increased to 1.8 mg/dl, and hypervolemia developed. Her hemoglobin decreased to 7.65 g/dl, and platelet count decreased to $58,000/\text{mm}^3$. In order to break the vicious cycle of malignant hypertension, an intervention to treat renal artery stenosis was planned. Until the intervention, she had undergone 7 sessions of ultrafiltration in 10 days in our hemodialysis department. This modality had effectively removed the excess fluid from the patient, causing her weight to drop from 87 to 77 kg. Interventional radiology department considered the right renal artery inappropriate for intervention. Balloon dilation was performed in the left renal artery and a stent was placed there. Figure 3 demonstrates the conventional angiography image of the left renal artery after balloon dilation was performed. After the intervention her blood pressure was under control with carvedilol, amlodipine and 4 mg/day of doxazosin. Creatinine level dropped to 0.7 mg/dl, her platelet count increased to $173,000/\text{mm}^3$ and hemoglobin increased to 8.81 g/dl. She was discharged from the hospital.

Two years after the discharge, patient is normotensive on carvedilol, amlodipine and low dose doxazosin. Her blood count, CRP, creatinine and LDH levels are normal. She continues to receive tocilizumab (which was converted to subcutaneous form after the COVID-19 pandemic), 4 mg/day methylprednisolone and acetylsalicylic acid.

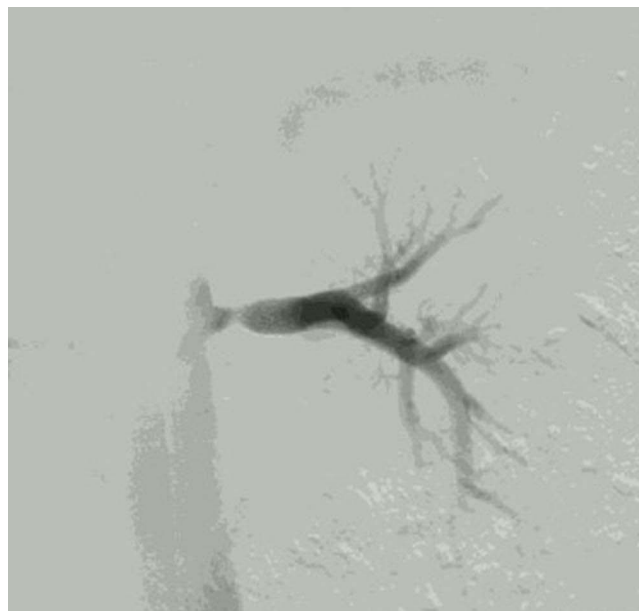

Figure 3 Conventional angiography image of the left renal artery after balloon dilation was performed.

Discussion

Malignant hypertension is the most severe presentation of hypertension. Original definition includes coexistence of severely elevated blood pressure and signs of advanced stages of hypertensive retinopathy at the time of diagnosis. New definitions emphasize the presence of damage in organs such as eye, kidney and heart together with uncontrolled elevation in blood pressure.³ Thrombotic microangiopathy secondary to malignant hypertension has been reported.⁴ It is a well established fact that Takayasu arteritis can cause renovascular hypertension by its renal artery involvement.⁵ Takayasu's involvement of the renal arteries is often bilateral and frequently ostial and proximal, usually with coexistent stenosis of the perirenal aorta.⁵ Cases of malignant hypertension secondary to Takayasu arteritis have also been reported.^{6,7} In our case, malignant hypertension which was triggered by the bilateral renal artery stenosis due to Takayasu arteritis caused acute kidney injury and advanced stage hypertensive retinopathy. In addition, unlike the other Takayasu arteritis cases with malignant hypertension, thrombotic microangiopathy was also detected. Treatment of both the underlying condition (Takayasu arteritis) and its complication (renal artery stenosis) was an important aspect of the management of malignant hypertension and its complications. In our case, patient received her monthly dose of IV tocilizumab and received an adequate dose of methylprednisolone to control the Takayasu arteritis disease activity. Interventional radiology department's utilization of balloon dilation and stent to treat renal artery stenosis broke the vicious cycle of malignant hypertension and treated the thrombotic microangiopathy.

Informed Consent

Signed informed consent for publication was obtained from the patient.

Institutional Approval

Institutional approval was not required to publish the case details.

Disclosure

The authors report no conflicts of interest in this work.

References

1. Russo RAG, Katsicas MM. Takayasu arteritis. *Front Pediatr*. 2018;6:265. doi:10.3389/fped.2018.00265
2. Chaudhry MA, Latif F. Takayasu's arteritis and its role in causing renal artery stenosis. *Am J Med Sci*. 2013;346(4):314–318. doi:10.1097/MAJ.0b013e31827e5dad
3. Domek M, Gumprecht J, Lip GYH, Shantsila A. Malignant hypertension: does it still exist? *J Hum Hypertens*. 2020;34:1–4. doi:10.1038/s41371-019-0267-y
4. Shigabaki Y, Fujita T. Thrombotic microangiopathy in malignant hypertension and hemolytic uremic syndrome (HUS)/ thrombotic thrombocytopenic purpura (TTP): can we differentiate one from the other? *Hypertens Res*. 2005;28(1):89–95. doi:10.1291/hypres.28.89
5. Li Cavoli G, Mulè G, Vallone MG, Caputo F. Takayasu's disease effects on the kidneys: current perspectives. *Int J Nephrol Renovasc Dis*. 2018;11:225–233. doi:10.2147/IJNRD.S146355
6. Wolak T, Szendro G, Golcman L, Paran E. Malignant hypertension as a presenting symptom of Takayasu arteritis. *Mayo Clin Proc*. 2003;78(2):231–236. doi:10.4065/78.2.231
7. Patel B, Tiwari A, Dubey SR, Bhatt GC, Tiwari P, Bhan BD. Takayasu arteritis presenting with malignant hypertension; a rare manifestation of a rare disease: a case report and review of literature. *Trop Doc*. 2017;47(1):60–63. doi:10.1177/0049475516648062

Open Access Rheumatology: Research and Reviews

Dovepress

Publish your work in this journal

Open Access Rheumatology Research and Reviews is an international, peer-reviewed, open access journal publishing original research, reports, editorials, reviews and commentaries on all aspects of clinical and experimental rheumatology in the clinic and laboratory including the following topics: Pathology, pathophysiology of rheumatological diseases; Investigation, treatment and management of rheumatological diseases; Clinical trials and novel pharmacological approaches for the treatment of rheumatological disorders. The manuscript management system is completely online and includes a very quick and fair peer-review system, which is all easy to use. Visit <http://www.dovepress.com/testimonials.php> to read real quotes from published authors.

Submit your manuscript here: <https://www.dovepress.com/open-access-rheumatology-research-and-reviews-journal>