

Available online at [www.sciencedirect.com](http://www.sciencedirect.com)

ScienceDirect

journal homepage: [www.elsevier.com/locate/radcr](http://www.elsevier.com/locate/radcr)

## Case Report

# Acute appendiceal diverticulitis: a case report<sup>☆</sup>

James M. Williams, MD, Daniel A. Adamo, MD, Michael C. Olson, MD\*

Department of Radiology, Mayo Clinic College of Medicine, Mayo Clinic, 200 First Street SW, Rochester, MN, 55905 USA

### ARTICLE INFO

#### Article history:

Received 17 January 2021

Revised 13 February 2021

Accepted 13 February 2021

#### Keywords:

Appendiceal diverticulitis

Appendicitis

Ultrasound

Abdominal pain

### ABSTRACT

Acute appendiceal diverticulitis is a difficult prospective diagnosis due to both its rarity and clinical overlap with other ileocecal diseases, such as acute appendicitis. Few preoperative radiological images of acute appendiceal diverticulitis have been presented in the literature. We report a case of acute appendiceal diverticulitis initially diagnosed with outpatient ultrasound and confirmed with contrast-enhanced computed tomography in an 85-year-old male who presented with right lower quadrant pain. Appendiceal diverticulitis is an often overlooked diagnosis, and given its association with appendiceal neoplasms and relatively high rate of perforation, it is important to consider this entity in patients with right lower quadrant pain in order to ensure that they are managed appropriately. The addition of high quality ultrasound and computed tomography (CT) images to the literature may heighten awareness of this rare condition and facilitate accurate preoperative diagnosis and management in these patients.

© 2021 The Authors. Published by Elsevier Inc. on behalf of University of Washington.

This is an open access article under the CC BY-NC-ND license (<http://creativecommons.org/licenses/by-nc-nd/4.0/>)

## Introduction

Diverticula of the appendix are a rare radiographic and pathologic finding. The reported pathologic incidence of appendiceal diverticulosis ranges from approximately 0.014%–1.9%, with appendiceal diverticulitis believed to account for 0.004%–2.1% of cases of presumed appendicitis [1,2]. Preoperative diagnosis is challenging, as its clinical presentation can closely resemble that of acute appendicitis [3,4]. An accurate distinction between appendiceal diverticulitis and acute appendicitis is important due to the unique risks associated with the former. Yamana et al showed that the rate of perforation in cases of appendiceal diverticulitis is more than 3 times

higher than that from cases of acute appendicitis [5]. Furthermore, diverticulitis of the appendix is associated with an increased risk of concomitant appendiceal neoplasms, particularly mucinous adenomas and carcinoid tumors [1]. Therefore, surgical excision is recommended in cases of appendiceal diverticulitis with or without concurrent acute appendicitis due to its high rates of perforation and associated morbidity and mortality. There are few imaging depictions of appendiceal diverticulitis in the literature, and diagnosis usually occurs retrospectively after appendectomy due to significant imaging overlap with other ileocecal pathologies, such as cecal diverticulitis and acute appendicitis [6]. Several authors have suggested that ultrasound (US) could be beneficial in the preoperative diagnosis of appendiceal

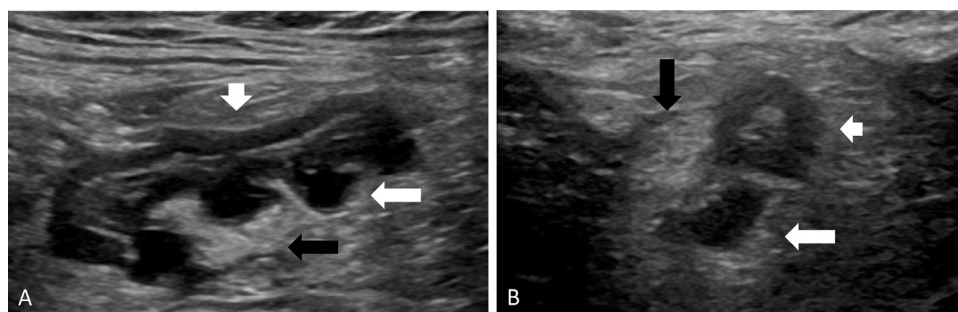
<sup>☆</sup> Competing interest: None of the authors have any disclosures.

\* Corresponding author.

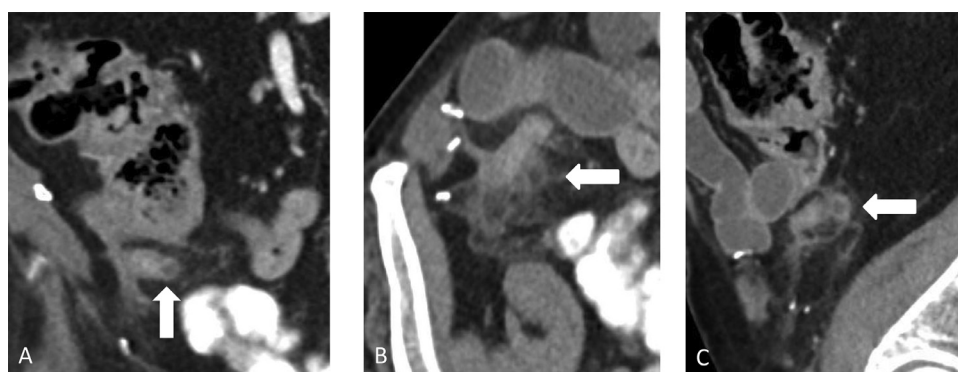
E-mail address: [olson.michael2@mayo.edu](mailto:olson.michael2@mayo.edu) (M.C. Olson).

<https://doi.org/10.1016/j.radcr.2021.02.034>

1930-0433/© 2021 The Authors. Published by Elsevier Inc. on behalf of University of Washington. This is an open access article under the CC BY-NC-ND license (<http://creativecommons.org/licenses/by-nc-nd/4.0/>)



**Fig. 1** – Longitudinal (A) and transverse (B) grayscale US images of the right lower quadrant demonstrate a mildly dilated appendix (short white arrow) with multiple small diverticular outpouchings (long white arrow) along the mesenteric border and increased echogenicity of the adjacent fat (black arrow).



**Fig. 2** – Coronal (A), axial (B), and sagittal (C) contrast-enhanced CT images of the right lower quadrant demonstrate multiple appendiceal diverticula (arrows) with inflammatory infiltration of the periappendiceal fat. Surgical clips related to prior inguinal hernia repair are seen.

diverticulitis [7,8]. Here, we report a case of acute appendiceal diverticulitis initially diagnosed sonographically and confirmed with contrast-enhanced computed tomography (CT).

### Case report

An 85-year-old male presented to the family medicine department at our institution with complaints of sharp right lower quadrant pain that began approximately 36 hours prior to his clinical appointment. He described the pain as position-dependent and as exacerbated by movement and direct palpation of the right lower quadrant, noting that it was comparable to pain he had previously experienced with an inguinal hernia prior to a remote repair. His vital signs were within normal limits, with a blood pressure of 121/77, a pulse of 78, and a temperature of 36.9°C. Physical examination revealed a tender, mildly protuberant abdomen without significant guarding or rebound.

Given initial clinical concern for inguinal hernia or musculoskeletal abdominal wall pain, the patient was referred for an outpatient US of the right lower quadrant. This failed to demonstrate a ventral or inguinal hernia but was notable for a mildly dilated appendix measuring 7–8 mm in diameter,

with multiple small, fluid-filled outpouchings arising from the mesenteric border (Fig. 1). The appendix was noncompressible with transducer pressure, with increased echogenicity of the surrounding fat in the right lower quadrant but no associated abscess or discrete, drainable fluid collection. Because the sonographic findings were concerning for either appendiceal diverticulitis or acute appendicitis, a contrast-enhanced CT of the abdomen and pelvis was obtained for further evaluation and confirmed mild dilation of the appendix and the presence of numerous small appendiceal diverticula with inflammatory infiltration of the adjacent periappendiceal fat (Fig. 2). The CT was otherwise unremarkable without additional findings to account for the patient's right lower quadrant pain. Due to the presence of multiple appendiceal diverticula and the concentration of inflammatory changes about the diverticula, the patient was diagnosed with appendiceal diverticulitis rather than acute appendicitis, and surgical referral was recommended. Following evaluation of the patient's clinical presentation, age, and medical comorbidities, the general surgery service opted to manage the patient nonoperatively, electing instead for a strategy of "watchful waiting." The patient's pain resolved over the course of several days, and he was symptom-free at a follow-up appointment with his family practitioner later in the week. No operative intervention was undertaken.

---

## Discussion

First described in 1893, diverticular disease of the appendix can be either congenital or acquired [9]. Congenital appendiceal diverticula are associated with chromosomal abnormalities, such as trisomy 13 (Patau syndrome), while risk factors for development of acquired diverticula include male sex, cystic fibrosis, and Hirschsprung's disease [1,3,9]. Congenital diverticula are characterized by herniation of all three layers of the appendix through a normal appendiceal wall, while acquired diverticula are believed to result from elevated intraluminal pressure (pulsion diverticula) and may be better classified as pseudodiverticula, with herniation of the mucosal and submucosal layers through a muscular defect [1]. Phillips further stratified appendiceal diverticulitis into 4 distinct subtypes: the classic form, type 1, consists of diverticular inflammation in the setting of an otherwise normal appendix; type 2 is characterized by diverticular inflammation on a background of acute appendicitis; type 3 is acute appendicitis with incidental diverticula; and type 4 is defined as appendiceal diverticulosis without either diverticular or appendiceal inflammation [9]. Differentiation of appendiceal diverticulitis from potential mimics, such as cecal diverticulitis and acute appendicitis, is clinically relevant, given its relatively high rate of perforation and association with appendiceal neoplasms. Conventional treatment of the disorder consists of surgical excision with careful histologic analysis of the resected specimen.

To our knowledge, only a few reports have highlighted imaging characteristics that may facilitate confident preoperative diagnosis of appendiceal diverticulitis, including the presence of discrete appendiceal diverticula and adjacent inflammatory change, and there is a dearth of high-quality US and CT images of appendiceal diverticulitis in the literature. This case is unique in that the diagnosis of appendiceal diverticulitis was made prospectively on the basis of the sonographic findings and corroborated on contrast-enhanced CT.

In patients with acute right lower quadrant pain, appendiceal diverticulitis remains an important diagnostic consideration.

---

## Patient consent

Not applicable, as no patient-specific identifying information was used in this case report.

---

## REFERENCES

- [1] Altieri ML, Piozzi GN, Salvatori P, Mirra M, Piccolo G, Olivari N. Appendiceal diverticulitis, a rare relevant pathology: presentation of a case report and review of the literature. *Int J Surg Case Rep* 2017;33:31–4.
- [2] Kabiri H, Clarke LE, Tzarnas CD. Appendiceal diverticulitis. *Am Surg* 2006;72(3):221–3.
- [3] Albeeshi MZ, Alwanyan AA, Salim AA, Albabtain IT. Appendiceal diverticulitis presenting as acute appendicitis diagnosed postoperatively. *J Surg Case Rep* 2019;2019(12):rjz332.
- [4] Seker D, Seker G, Kahramanca S, Gurler M, Turker A, Kulacoglu H. A rare but distinctive cause of acute abdomen: appendiceal diverticulitis. *J Emerg Med* 2013;44(1):e61–2.
- [5] Yamana I, Kawamoto S, Inada K, Nagao S, Yoshida T, Yamashita Y. Clinical characteristics of 12 cases of appendiceal diverticulitis: a comparison with 378 cases of acute appendicitis. *Surg Today* 2012;42(4):363–7.
- [6] Place RJ, Simmang CL, Huber PJ Jr. Appendiceal diverticulitis. *South Med J* 2000;93(1):76–9.
- [7] Macheiner P, Hollerweger A, Gritzmann N. Sonographic features of diverticulitis and diverticulosis of the vermiform appendix. *J Clin Ultrasound* 2002;30(7):456–7.
- [8] Kubota T, Omori T, Yamamoto J, Nagai M, Tamaki S, Sasaki K. Sonographic findings of acute appendiceal diverticulitis. *World J Gastroenterol* 2006;12(25):4104–5.
- [9] Phillips BJ, Perry CW. Appendiceal diverticulitis. *Mayo Clin Proc* 1999;74(9):890–2.