

Combined photodynamic therapy and intravitreal bevacizumab for idiopathic polypoidal choroidal vasculopathy: one-year follow-up

Mario R Romano¹
Ugo Cipollone²
Francesco Semeraro³
Michele Rinaldi⁴
Ciro Costagliola¹

¹Dipartimento di Scienze per la Salute, Università degli Studi del Molise, Campobasso; ²Dipartimento di Oftalmologia, Ospedale G Vietri, Larino, Campobasso; ³Clinica Oculistica, Università degli Studi di Brescia, Brescia; ⁴Clinica Oculistica, Il Università degli Studi di Napoli, Napoli, Italy

Objective: To report the efficacy and safety of combined photodynamic therapy (PDT) and intravitreal bevacizumab (IVB) injection in the treatment of idiopathic polypoidal choroidal vasculopathy (IPCV).

Material and methods: A prospective case series of 10 eyes of 10 consecutive patients affected by IPCV with subfoveal involvement. PDT plus IVB (1.25 mg/0.05 mL) injection two weeks later was performed in all patients. Two adjunctive injections of bevacizumab were scheduled at four and eight weeks after the initial treatment. Best-corrected visual acuity (BCVA), fluorescein and indocyanine green angiographies, and optical coherence tomography were obtained at baseline, and at one, three, six, nine, and 12 months.

Results: The combined treatment led to an improvement of both neurosensory detachment and pigmented epithelial detachment in all eyes, with a decrease of exudation and regression of macular thickness, which remained stable to the end of follow-up. However, BCVA remained stable over the 12 months of follow-up.

Conclusion: These findings demonstrate that PDT/IVB combined therapy is able to achieve morphologic stabilization of the IPCV lesion, through a rapid decrease of macular thickness and regression of the size of polypoidal vascular lesion.

Keywords: combined treatment, idiopathic polypoidal choroidal vasculopathy, age-related macular degeneration, intravitreal bevacizumab, photodynamic therapy

Introduction

The term “idiopathic polypoidal choroidal vasculopathy” (IPCV) was coined by Yannuzzi et al to describe a disease of the choroidal circulation characterized by branching choroidal vessels with polyp-like terminal aneurysmal dilations, and recognized as a clinical entity separate from age-related macular degeneration.¹ The vascular abnormalities are frequently located in the peripapillary area or within the macula, where they may be responsible for serious visual loss. Large serous-hemorrhagic pigmented epithelial detachments (PEDs) are another clinical characteristic of the disease.³ IPCV is not a rare condition among patients presumptively diagnosed with exudative age-related macular degeneration (7.9% of 167 patients in a mixed population).² Both sexes are equally affected, but a predilection for more darkly pigmented patients has been observed, although white patients still represent the majority of polypoidal choroidal vasculopathy patients in clinical practice.^{1,2}

Treatment for IPCV is not yet well established. A conservative approach is recommended, unless the lesion is associated with persistent or progressive exudative change, threatening central vision.⁴ In this case, conventional thermal laser treatment of the

Correspondence: Mario R Romano
Dipartimento di Scienze per la Salute, Via
F de Sanctis, 86100 Campobasso, Italy
Tel +44 079 6019 2539
Fax +44 015 1706 5905
Email romanomario@email.it

leaking polypoidal choroidal vascular abnormality may be successful in causing resolution of the serous-hemorrhagic manifestations. In the more compromised varieties, photodynamic therapy (PDT) with verteporfin has demonstrated promising results,^{5,6} although definitive outcomes to confirm these anecdotal observations are not yet available. We herein report the clinical course of 10 consecutive patients affected by IPCV in whom the efficacy and safety of PDT plus intravitreal bevacizumab (IVB) injection has been analyzed.

Materials and methods

Our series consisted of 10 eyes of 10 consecutive patients (aged 68.7 ± 13 years, male to female ratio 7:3) diagnosed with IPCV and subfoveal involvement, who were refractory to previous treatment with photodynamic therapy alone. Demographic characteristics for the patients are summarized in Table 1. The diagnosis of IPCV was based on clinical examination and on multiple areas of PED seen on indocyanine green angiograms (ICGA) as a network of branching vessels and polypoidal lesions in the macular area located at the margin of the PEDs. All patients underwent a complete ophthalmic examination including fluorescein angiography, ICGA, and optical coherence tomography (OCT) at baseline and at one, three, six, nine, and 12 months of follow-up. Best-corrected visual acuity (BCVA) was measured with Early Treatment Diabetic Retinopathy Study (ETDRS) charts.

PDT followed by IVB (1.25 mg/0.05 mL) injection two weeks later were performed in all cases. Two adjunctive injections of bevacizumab were scheduled at four and eight weeks after the initial treatment. The patients were given detailed information about the natural course of the disease and about the results of alternative therapeutic and surgical approaches for IPCV before being offered IVB. Written informed consent was obtained from all subjects after a description of the procedure to be used. The local human

subjects review committees (Brescia, Campobasso, Larino, Napoli) approved the project.

Results

Five patients were phakic and five were pseudophakic. Baseline BCVA ranged from 20/400 to 20/100. BCVA, macular thickness, and angiographic variations during the 12 months of follow-up are detailed in Table 2. A neurosensory retinal detachment and at least one PED were observed at baseline in all recruited patients.

After the third IVB injection, angiography showed a regression in size of the polypoidal vascular lesions and a reduction in leakage. OCT scans documented an improvement in neurosensory retinal detachment and a reduction of PED (Figures 1 and 2). In five cases (patients 2, 5, 6, 8, and 10), both retinal and choroidal angiograms did no longer show signs of vascular activity. In four cases (patients 1, 4, 7, and 9), the PED was no longer visible at slit-lamp examination or fluorescein angiography, and the choroidal neovascularization also seemed to have decreased, with involution of the choroidal polyp-like structure, together with a minimal residual leakage (area of leakage occupying <50% of the area noted at baseline). In one case (patient 3), no signs of regression, in terms of reduction in leakage or size of the lesion, could be seen at 12-month follow-up after combined therapy.

Regression of macular thickness, assessed by OCT examination, occurred in all the patients and remained stable over the entire follow-up period. In fact, after one month of PDT, the mean reduction in macular thickness was about 30%. At the end of the 12-month follow-up, a modest further increase of about 40% was documented (Table 2). The treatment was not able to ameliorate VA significantly, which remained unwaivering at each assessment. No side effects were reported due to the combined treatment.

Discussion

Polypoidal choroidal vasculopathy seems to be a distinct clinical entity that should be differentiated from other types of occult choroidal neovascularization associated with age-related macular degeneration and other known choroidal degenerative, inflammatory, and ischemic disorders. The principal abnormality seen in IPCV, notably the branching vascular network and polypoidal structures at the borders of the lesion, seem to be unique to the disorder.

In this prospective interventional case series, the combination of PDT and IVB has been able to treat the lesion in patients affected by IPCV. A potential benefit in terms of stabilization of leakage and lesion size was documented, but it

Table 1 Baseline patient characteristics undergoing intravitreal bevacizumab treatment for a polypoidal choroidal vascular lesion

Patient	Gender	Age	Eye	Lens status	Visual acuity
1	M	54	Right	Phakic	20/120
2	M	63	Left	Phakic	20/100
3	F	77	Right	Pseudophakic	20/120
4	M	88	Right	Pseudophakic	20/400
5	M	80	Left	Pseudophakic	20/200
6	M	78	Right	Pseudophakic	20/400
7	F	57	Right	Phakic	20/400
8	M	53	Left	Phakic	20/200
9	F	65	Right	Phakic	20/120
10	M	71	Right	Pseudophakic	20/200

Table 2 Best-corrected visual acuity and macular thickness variation during 12 months of follow-up after intravitreal bevacizumab treatment for a polypoidal choroidal vascular lesion

Patient number	Visual acuity						Macular thickness						Last FA
	Baseline	1	3	6	9	12	Baseline	1	3	6	9	12	
1	20/120	20/80	20/80	20/80	20/100	20/100	380	210	220	210	210	210	Min
2	20/100	20/100	20/100	20/100	20/100	20/100	410	240	230	230	220	220	No leakage
3	20/120	20/80	20/100	20/100	20/120	20/120	460	320	300	285	280	280	Prev*
4	20/400	20/100	20/200	20/100	20/120	20/100	370	320	320	290	260	260	Min+
5	20/200	20/100	20/80	20/80	20/80	20/80	380	290	210	210	220	220	No leakage
6	20/400	20/200	20/200	20/100	20/80	20/80	320	240	220	220	215	215	No leakage
7	20/400	20/100	20/100	20/80	20/100	20/80	340	260	230	230	230	230	Min
8	20/200	20/80	20/60	20/80	20/80	20/80	350	210	230	230	220	220	No leakage
9	20/120	20/120	20/100	20/80	20/80	20/80	440	300	260	240	210	210	Min
10	20/200	20/200	20/200	20/120	20/120	20/100	390	270	260	260	290	280	No leakage

Note: *Prev = area of leakage occupying >50% of the area noted at baseline; + Min = area of leakage occupying <50% of the area noted at baseline.

Abbreviation: FA, fluorescein angiography.

was not associated with significant recovery of visual acuity. The PDT-IVB combination led to a rapid decrease in macular thickness, with a significant regression in terms of retinal edema and subretinal fluid, being successful in stabilizing the lesion. IPCV has been reported in 85% of patients with PED, subretinal hemorrhages, and exudation in the macular area on ICGA in patients with hemorrhagic AMD.³ The most frequent clinical complication after treatment could be the exudative retinal detachments, retinal pigment epithelium tears, and massive bleeding.

In patients with serous-sanguineous detachment of the pigment epithelium, particularly those with increased risk factors, such as African-American or Asian race, ICGA should be performed to evaluate the choroidal vascular abnormality in an attempt to establish a more definitive

diagnosis. If the characteristic vascular lesion of IPCV is seen, a conservative approach should be entertained unless there is a persistent or progressive exudative change that is threatening the central macula. In that event, there may be a rationale for photocoagulation treatment of leaking aneurysmal or polypoidal components within the vascular lesion, but not the entire vascular complex.⁴

Several experimental treatments, such as focal laser photocoagulation, thermal laser, and PDT have demonstrated only a potential success rate with several complications. Laser photocoagulation and thermal laser are advised for the treatment of IPCV if the lesion does not involve the fovea. This treatment is actually considered a palliative treatment for IPCV, and the final vision achieved is poor and relapse is frequent.^{4,5} PDT with verteporfin for IPCV involving the fovea appears to be a viable option, but the treatment could be complicated by iatrogenic bullous exudative retinal detachments that resemble rhegmatogenous detachments⁶ or by the risk of massive bleeding. Moreover, as demonstrated in the Verteporfin in Photodynamic Therapy study, the visual outcome of PDT for occult choroidal neovascularization in age-related macular degeneration was generally compromised, because more than 50% of

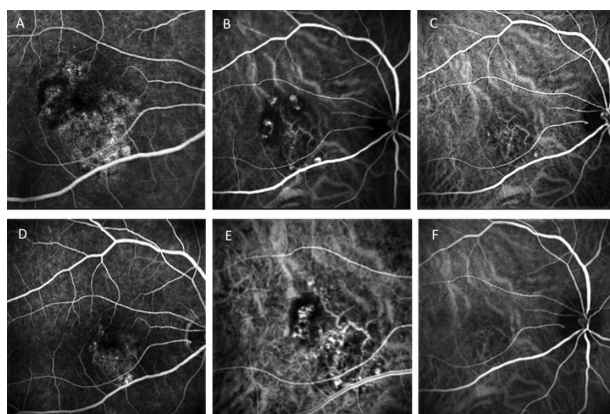


Figure 1 **A** fluorescein, **B** indocyanine green, early phase, **C** indocyanine green, later phase baseline angiographic characteristics. The angiograms showed choroidal polyp-like structure together with subfoveal leakage. **D** fluorescein angiography, **E** indocyanine green, early phase, **F** indocyanine green, later phase at 12-months follow-up. The angiograms showed a regression in size of the polypoidal vascular lesions and a reduction in leakage.

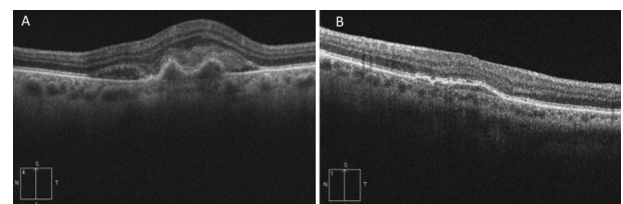


Figure 2 At 12-month follow-up, the optical coherence tomography scans showed an improvement of neurosensory retinal detachment and a reduction of pigment endothelial detachment **B** from baseline **A**.

verteporfin-treated eyes developed visual loss of three or more lines after one year.⁷

Bevacizumab is a mouse-derived monoclonal antibody designed to neutralize the effects of all isoforms of vascular endothelial growth factor (VEGF). It plays a role as a chorioidal survival factor for the choriocapillaris, maintaining the permeability and fenestration of the vessels. This antigen-binding monoclonal antibody has never been tested before for the treatment of occult choroidal neovascularization characterized by polyp-like vessels.

One of the reasons for the less favorable outcome in treating an occult lesion such as IPCV might be the collateral damage to adjacent structures, such as choriocapillaris hypoperfusion and retinal pigment epithelium atrophy, due to the effect of PDT.⁸ The associated damage results in retinal edema and release of angiogenic factors, with reduction of retinal function demonstrated by multifocal electroretinography.⁹

Therefore, after an unsuccessful single treatment with PDT alone, we thought that adding anti-VEGF treatment might increase the efficacy of PDT in the treatment of this particular kind of choroidal neovascularization. Because the antiangiogenic effects of PDT with verteporfin are usually transient, a combination of PDT with an intermediate-acting antiangiogenic agent like IVB may be a promising treatment option by creating a longer lasting and possibly synergistic effect on choroidal neovascularization.

The first case report described the clinical course of a patient treated with IVB, who had received prior treatments with PDT and intravitreal pegaptanib with a poor therapeutic response.¹⁰ Within four weeks of follow-up after a single IVB, an improvement of VA for hand motion to 20/400 coincident with resolution of subretinal fluid was achieved. Moreover, the macula remained without exudation for 12 months post treatment.

The first reported series consisted of 11 IPCV patients treated with IVB and a three-month follow-up.¹¹ An additional injection was administered in five of 11 eyes. The main outcomes were changes in the polypoidal vessels, foveal height, and BCVA, evaluated before and three months after treatment. At month 3, a resolution of polyps had occurred in one eye, whereas residual or enlarged lesions were recorded in the other 10 eyes. The foveal height decreased significantly one month after IVB, but at three months no significant decrease was observed, although an additional injection had been performed. The BCVA did not improve significantly. The conclusion of the study was that IVB may reduce the fluid from choroidal vasculopathy but seems to be ineffective for diminishing its choroidal vascular changes.

Sato et al described 12-month follow-up results for 29 treatment-naïve IPCV patients who received combined therapy (IVB-PDT-verteporfin). The mean number of treatments with combined therapy averaged 1.59. Polypoidal lesions recurred in six eyes (21%). The authors concluded that the combined treatment seemed to be effective for improving visual acuity and reducing retreatment rates and complications.¹² In contrast, Lim et al showed 12-month results for 10 eyes affected by IPCV and randomized to either IVB or combined treatment. IVB alone had similar efficacy and safety to IVB plus PDT for treatment of patients, including those who were treatment-naïve.¹³

In our study, the combined treatment led to morphologic stabilization of IPCV lesions, seen as a rapid decrease in macular thickness together with a regression of the size of polypoidal vascular lesions, but this was not accompanied by an increase in BCVA.

There are several important limitations to this study, including lack of a control group, a small number of patients, and inadequate low functional changes measurement. The encouraging results obtained in these patients emphasize the need for further randomized clinical studies of combined treatment for IPCV lesions.

Disclosure

The authors indicate no conflicts of interest in this work.

References

1. Yannuzzi LA, Sorenson J, Spaide RF, et al. Idiopathic polypoidal choroidal vasculopathy (PCV). *Retina*. 1990;10:1–8.
2. Yannuzzi LA, Wong D, Scassellati-Sforzolini B, et al. Polypoidal choroidal vasculopathy and neovascularized age-related macular degeneration. *Arch Ophthalmol*. 1999;117:1503–1510.
3. Tsujikawa A, Sasahara M, Otani A, et al. Pigment epithelial detachment in polypoidal choroidal vasculopathy. *Am J Ophthalmol*. 2007;143:102–111.
4. Costa RA, Navajas EV, Farah ME, et al. Polypoidal choroidal vasculopathy: Angiographic characterization of the network vascular elements and a new treatment paradigm. *Prog Retin Eye Res*. 2005;24:560–586.
5. Spaide RF, Donsoff I, Lam DL, et al. Treatment of polypoidal choroidal vasculopathy with photodynamic therapy. *Retina*. 2002;22:529–535.
6. Quaranta M, Maget-Faysse M, Coscas G. Exudative idiopathic polypoidal choroidal vasculopathy and photodynamic therapy with verteporfin. *Am J Ophthalmol*. 2002;134:277–280.
7. Verteporfin in Photodynamic Therapy Report 2. Verteporfin therapy of subfoveal choroidal neovascularization in age-related macular degeneration: Two-year results of a randomized clinical trial including lesions with occult with no classic choroidal neovascularisation. *Am J Ophthalmol*. 2001;131:541–560.
8. Moshfeghi DM, Kaiser PK, Grossniklaus HE, et al. Clinicopathologic study after submacular removal of choroidal neovascular membranes treated with verteporfin ocular photodynamic therapy. *Am J Ophthalmol*. 2003;135:343–350.
9. Lai TY, Chan WM, Lam DS. Transient reduction in retinal function revealed by multifocal electroretinogram following photodynamic therapy. *Am J Ophthalmol*. 2004;137:826–833.

10. Ghajarnia M, Kurup S, Eller A. The therapeutic effects of intravitreal bevacizumab in a patient with recalcitrant idiopathic polypoidal choroidal vasculopathy. *Semin Ophthalmol.* 2007;22:127–131.
11. Gomi F, Sawa M, Sakaguchi H, et al. Efficacy of intravitreal bevacizumab for polypoidal choroidal vasculopathy. *Br J Ophthalmol.* 2008; 92:70–73.
12. Sato T, Kishi S, Matsumoto H, Mukai R. Combined photodynamic therapy with verteporfin and intravitreal bevacizumab for polypoidal choroidal vasculopathy. *Am J Ophthalmol.* 2010;149:947–954.
13. Lim JY, Lee SY, Kim JG, Lee JY, Chung H, Yoon YH. Intravitreal bevacizumab alone versus in combination with photodynamic therapy for the treatment of neovascular maculopathy in patients aged 50 years or older: 1-year results of a prospective clinical study. *Acta Ophthalmol.* Mar 16, 2010. [Epub ahead of print.]

Clinical Ophthalmology

Publish your work in this journal

Clinical Ophthalmology is an international, peer-reviewed journal covering all subspecialties within ophthalmology. Key topics include: Optometry; Visual science; Pharmacology and drug therapy in eye diseases; Basic Sciences; Primary and Secondary eye care; Patient Safety and Quality of Care Improvements. This journal is indexed on

Submit your manuscript here: <http://www.dovepress.com/clinical-ophthalmology-journal>

PubMed Central and CAS, and is the official journal of The Society of Clinical Ophthalmology (SCO). The manuscript management system is completely online and includes a very quick and fair peer-review system, which is all easy to use. Visit <http://www.dovepress.com/testimonials.php> to read real quotes from published authors.

Dovepress