

Received: 2012.03.17
Accepted: 2012.04.07

Rhombencephalosynapsis – isolated anomaly or complex malformation?

Monika Bekiesińska-Figatowska¹, Elżbieta Jurkiewicz², Sylwia Szkudlińska-Pawlak¹, Katarzyna Malczyk², Katarzyna Nowak²

¹ Department of Diagnostic Imaging, Institute of Mother and Child, Warsaw, Poland

² Department of Diagnostic Imaging, The Children's Memorial Health Institute, Warsaw, Poland

Author's address: Monika Bekiesińska-Figatowska, Diagnostic Imaging Department, Institute of Mother and Child, Kasprzaka Str. 17a, 01-211 Warsaw, Poland, e-mail: zaklad.rtg@imid.med.pl

Summary

Background:

Rhombencephalosynapsis (RES) is a rare malformation of the posterior cranial fossa, characterized by fusion of the cerebellar hemispheres, medial cerebellar peduncles and dentate nuclei. Over the period of 7 years 8 cases of this anomaly have been diagnosed in two pediatric centers in Warsaw including one on the prenatal magnetic resonance imaging (MRI).

Material/Methods:

Material consists of involves one fetus examined at the gestational age of 27 and 33 weeks and 7 children (5 girls and 2 boys) aged 8 months – 16 years. All of them underwent brain MRI with the use of 1.5T scanners.

Results:

In 1 case RES was an isolated anomaly, in 1 case it was accompanied by hydrocephalus only, in the remaining 6 cases RES was an element of a complex malformation. The additional anomalies were as follows: callosal hypoplasia in 3 children, abnormalities of gyration in 2, brainstem hypoplasia in 2, isolated fourth ventricle in 1, abnormal white matter signal intensity in 4 (in 2 cases in supratentorial compartment, in 1 in the cerebellum and in 1 in the pons), abnormally dilated extraaxial fluid collections in 2, syringohydromyelia in 2. In 5 cases RES was total, in 3 – partial.

Conclusions:

Rhombencephalosynapsis has a very characteristic appearance on magnetic resonance imaging which allows diagnosis of this malformation at any age, including prenatal period.

Key words:

congenital anomalies • rhombencephalosynapsis (RES) • magnetic resonance imaging (MRI)

PDF file:

<http://www.polradiol.com/fulltxt.php?ICID=883372>

Background

Rhombencephalosynapsis (RES) is a rare malformation of the posterior cranial fossa, characterized by fusion of the cerebellar hemispheres, medial cerebellar peduncles and dentate nuclei [1,2]. The fusion results from the underdevelopment of the cerebellar vermis. In the second case there is no anterior (cephalic) part of the vermis and the posterior (caudal) part is deficient [3]. The incidence rate of this anomaly is about 0,13% [4]. There is only one description of this anomaly in Polish literature [5]. Over the period of 7 years 8 cases of rhombencephalosynapsis have been diagnosed in two pediatric centers in Warsaw, including the one diagnosed during prenatal magnetic resonance imaging (MRI).

Material and Methods

The material consists of involves one fetus examined at the gestational age of 27 and 33 weeks and 7 children (5 girls and 2 boys) aged 8 months – 16 years. All of them underwent brain MRI with the use of 1.5T scanners.

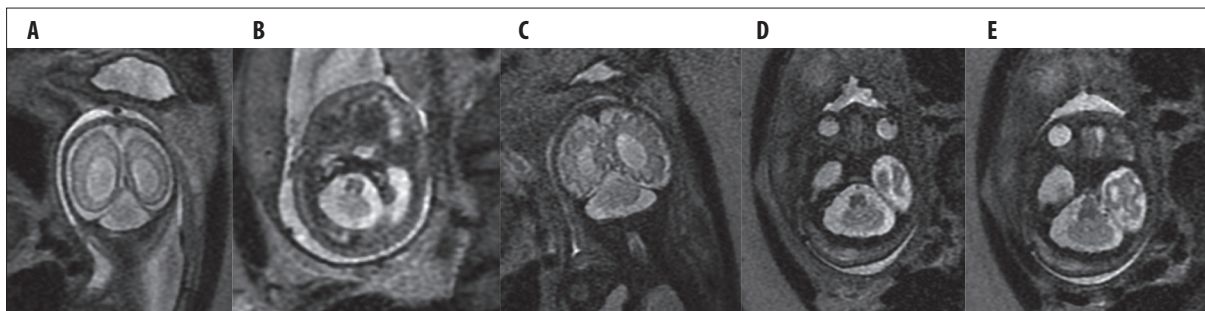
Results

In the fetus MRI was performed after prenatal ultrasonography during which ventriculomegaly and unclear, malformed appearance of the cerebellum were identified. MR enabled recognition of RES.

In 1 out of 8 cases RES was an isolated malformation, in 1 it was accompanied by hydrocephalus alone, and in

Table 1. MRI of the examined children: RES and accompanying anomalies.

No.	Age (in years)	Sex	RES – total/partial	Widening of the ventricular system	Other anomalies
1	27, 33 hbd		total	+	–
2	8/12	F	total	+	Brainstem hypoplasia; abnormal signal from the cerebellum; isolated fourth ventricle; syringohydromyelia
3	16	F	total	+	Corpus callosum hypoplasia; abnormal white matter signal intensity; brainstem hypoplasia; syringohydromyelia
4	5	F	total	-	–
5	2 and 8/12	M	total	+	Aprosencephaly/atelencephaly; abnormal signal of the pons; abnormally dilated extraaxial fluid collections
6	2 and 2/12	F	partial	+	Microcephaly; polymicrogyria; corpus callosum hypoplasia; abnormal white matter signal intensity;
7	2 and 5/12	F	partial	+	Mega cisterna magna, cerebellar hypoplasia
8	2 and 5/12	M	partial	-	Pachy-/polymicrogyria

**Figure 1.** Case 1. Prenatal MRI, SSFSE/T2-weighted images, axial and coronal plane. The suspicion of RES was raised because of the small cerebellum with flat base and cerebellar folia continuing through the midline. Follow-up study performed 6 weeks later confirmed this suspicion. Hydrocephalus. (A,B) MRI at the gestational age of 27 weeks; (C–E) Follow-up study at GA of 33 weeks.

the remaining 6 cases RES was an element of a complex malformation.

In 5 cases the malformation was expressed in its full form.

The changes identified during MR are presented in Table 1.

Discussion

MR appearance of rhombencephalosynapsis is very characteristic and thus easy to identify – even in the prenatal period (Figure 1). Fusion of the cerebellar hemispheres results in continuous cerebellar folia visible in axial and coronal planes. Furthermore, flat-based cerebellum without cerebellar vallecule and diamond-shaped fourth ventricle, instead of the normal crescent shape are visible [3].

Ultrasound examination usually reveals lack of the cerebellar vermis. Additional feature suggesting RES is small cerebellum [6]. Reports on the prenatal RES diagnosis are rather rare and identification of the anomaly is usually confirmed by MRI [6,7], as was in our case (Figure 1). Another feature of our patient was a dilated supratentorial ventricular system that is often associated with RES and results from the stenosis of aqueduct of Sylvius [3,8]. Only one child in our group

did not show a dilated ventricular system and it was the only case of the isolated malformation – as in the case described by Paprocka et al. [5]. The remaining 7 patients described in this paper had other accompanying anomalies: underdevelopment of corpus callosum in 3 cases, abnormalities of gyration in 2, brainstem hypoplasia in 2, isolated fourth ventricle in 1, abnormal white matter signal intensity in 4 (in 2 cases in supratentorial compartment, in 1 in the cerebellum and in 1 in the pons – Figure 2), abnormally dilated extraaxial fluid collections in 2, syringohydromyelia in 2.

On the one hand, it is consistent with the literature which describes RES as an anomaly often accompanied by other congenital abnormalities [2,9]. On the other hand, it is opposite to the findings of some researchers who observed extremely rare coexistence of RES and brainstem abnormalities [2]. In our material the brainstem hypoplasia was found in 2 children and an incorrect signal of the pons in another one and that amounts to 37.5% of patients. In the most extensive article from the Pubmed database describing 42 cases of RES, brainstem malformations were recognized in 10 cases (23.8%) [9].

In 1 case MRI showed a very complex malformation: a serious prosencephalic hypoplasia with the features of

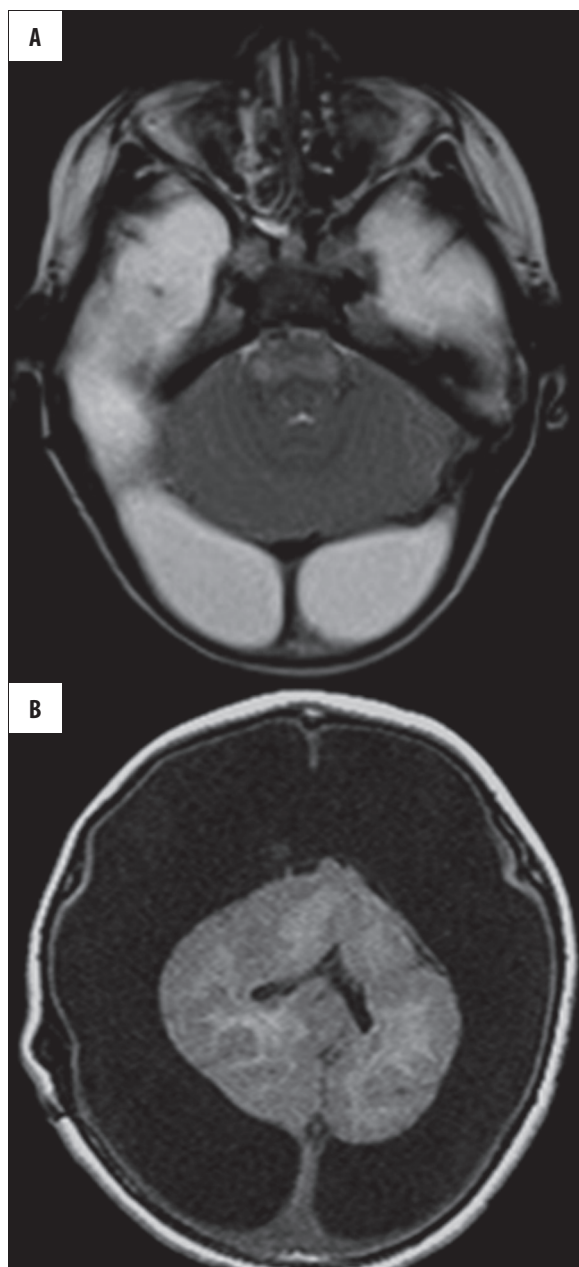


Figure 2. Case 5. Total RES with aprosencephaly/atelencephaly, abnormal signal intensity of the pons and wide extraaxial fluid collections. (A) FSE/T2-weighted image, axial plane; (B) SE/T1-weighted image, axial plane.

lobar holoprosencephaly and RES (Figure 2). Supratentorial anomaly in this patient may suggest aprosencephaly/atelencephaly as there is a connection between this malformation and holoprosencephaly [9,10]. Aprosencephaly/atelencephaly is a very rare prosencephalic malformation. Aprosencephaly means the lack of prosencephalon. In atelencephaly the prosencephalon is a rudimentary medial vesicle resembling diencephalon, but without lateral vesicles of telencephalon. A combination of both above-described rare anomalies is even more infrequent [11].

In most of our patients (5=62.5%) the RES was manifested in its full form with total fusion of cerebellar hemispheres

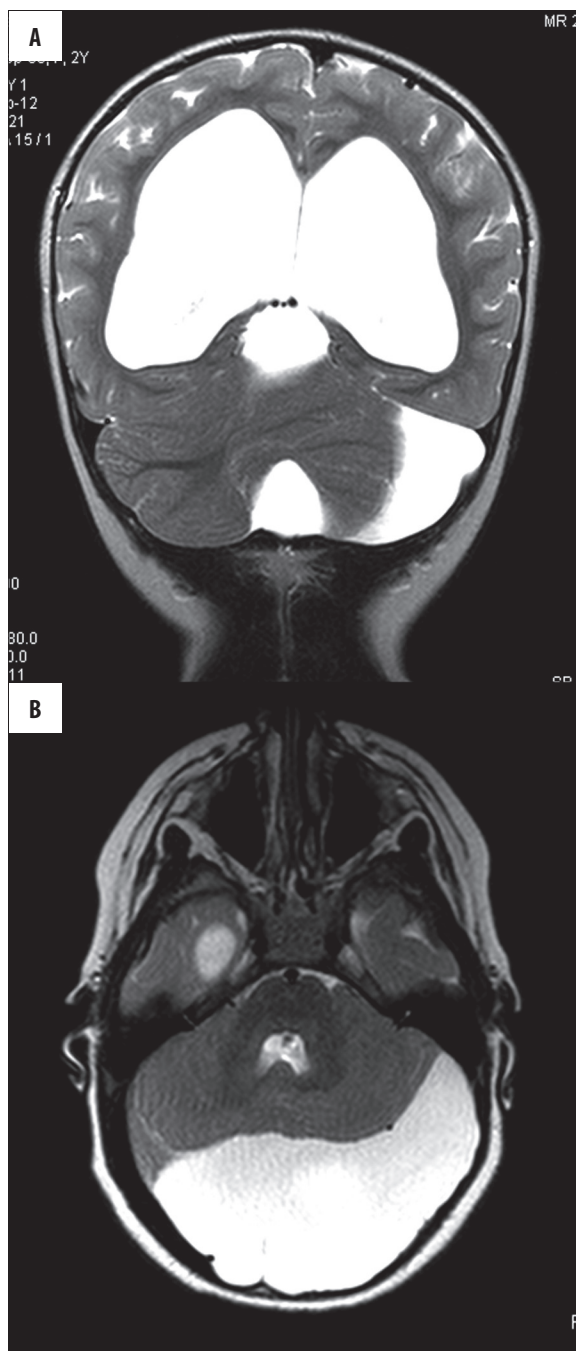


Figure 3. Case 7. Arachnoid cyst in the posteriori cranial fossa compressing the cerebellum. Cerebellar hypoplasia, especially of the left hemisphere. Partial RES. Hydrocephalus. FSE/T2-weighted images. (A) Coronal plane; (B) Axial plane.

and lack of vermis (Figures 1, 2). In the other patients (3=37.5%), the malformation was partial (Figures 3, 4). In 2 of those 3 children the upper parts of cerebellar hemispheres were fused and in 1 the fusion was visible in the bottom parts. The most comprehensive RES review mentioned above presents a wide range of anomalies connected with the different degree of the fusion [9].

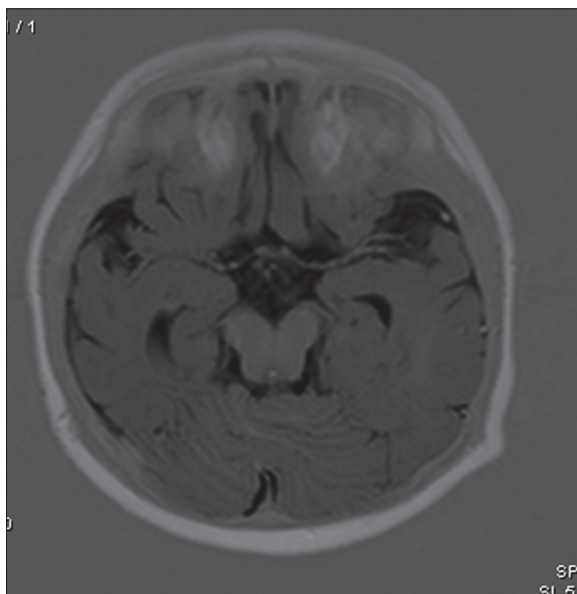


Figure 4. Case 6. Partial RES with fused upper parts of the cerebellum.

RES can appear as an isolated anomaly or may accompany complex malformations, such as Gomez-Lopez-Hernandez syndrome characterized by oxycephaly (turricephaly) and other dysmorphic features, parietal and temporal alopecia, trigeminal anesthesia, VACTREL association (vertebral anomalies, anal atresia, cardiovascular anomalies, trachea-oesophageal fistula, renal anomalies, limb defects [9]. As this anomaly is usually accompanied by hydrocephalus (H), the term VACTERL-H association is used [2].

Rhombencephalosynapsis itself is not connected with any characteristic set of neurological symptoms [12,13]. It may be not associated with intellectual deficits and disorders preventing normal everyday functioning and thus it may be incidentally diagnosed in adults [14].

Conclusions

MR appearance of rhombencephalosynapsis is very characteristic and thus the malformation can be easily diagnosed at any age including the prenatal period.

References:

- Altman NR, Naidich TP, Braffman BH: Posterior fossa malformations. *Am J Neuroradiol*, 1992; 13(2): 691-724
- Pasquier L, Marcorelles P, Loget P et al: Rhombencephalosynapsis and related anomalies: a neuropathological study of 40 fetal cases. *Acta Neuropathol*, 2009; 117(2): 185-200
- Utsunomiya H, Takano K, Ogasawara T et al: Rhombencephalosynapsis: cerebellar embryogenesis. *Am J Neuroradiol*, 1998; 19(3): 547-49
- Sener RN: Unusual MRI findings in rhombencephalosynapsis. *Comput Med Imaging Graph*, 2000; 24(4): 277-82
- Paprocka J, Jamroz E, Ścieszka E et al: Isolated rhombencephalosynapsis – a rare cerebellar anomaly. *Pol J Radiol*, 2012; 77(1): 47-49
- McAuliffe F, Chitayat D, Halliday W et al: Rhombencephalosynapsis: prenatal imaging and autopsy findings. *J Neurosurg Pediatr*, 2008; 2(6): 435-37
- Napolitano M, Righini A, Zirpoli S et al: Prenatal magnetic resonance imaging of rhombencephalosynapsis and associated brain anomalies: report of 3 cases. *J Comput Assist Tomogr*, 2004; 28: 762-65
- Truwit CL, Barkovich AJ, Shanahan R et al: MR imaging of rhombencephalosynapsis: report of three cases and review of the literature. *Am J Neuroradiol*, 1991; 12(5): 957-65
- Ishak GE, Dempsey JC, Shaw DWW et al: Rhombencephalosynapsis: a hindbrain malformation associated with incomplete separation of midbrain and forebrain, hydrocephalus and a broad spectrum of severity. *Brain*, 2012; 135(5): 1370-86
- Pasquier L, Dubourg C, Gonzales M et al: First occurrence of aprosencephaly/atelencephaly and holoprosencephaly in a family with a SIX3 gene mutation and phenotype/genotype correlation in our series of SIX3 mutations. *J Med Genet*, 2005; 42(1): e4
- Takano T, Kinoshita N, Narumiya S et al: Aprosencephaly with rhombencephalosynapsis and hamartomatous midbrain dysplasia. *Neuropathol Appl Neurobiol*, 2010; 36(4): 353-55
- Mendonca JL, Natal MR, Viana SL et al: Rhombencephalosynapsis: CT and MRI findings. *Neurology India*, 2004; 52: 118-20
- Toelle SP, Yalcinkaya C, Kocer N et al: Rhombencephalosynapsis: clinical findings and neuroimaging in 9 children. *Neuropediatrics*, 2002; 33: 209-14
- Beli BD, Stanko HA, Levine RL: Normal IQ in a 55-year-old with newly diagnosed rhombencephalosynapsis. *Arch Clin Neuropsychol*, 2005; 20: 613-21