



Original research

# Implantation of multiple suprachoroidal electrode arrays in rabbits

Walid Abdallah<sup>a</sup>, Wen Li<sup>b</sup>, James Weiland<sup>a</sup>, Mark Humayun<sup>a</sup>, Hossein Ameri<sup>a,\*</sup>

<sup>a</sup> Department of Ophthalmology, USC Roski Eye Institute, Keck School of Medicine of the University of Southern California, Los Angeles, CA, USA

<sup>b</sup> Department of Electrical and Computer Engineering, Michigan State University, East Lansing, MI, USA

Received 22 May 2017; revised 6 November 2017; accepted 10 November 2017

Available online 9 December 2017

## Abstract

**Purpose:** Epiretinal and subretinal prosthesis have been shown to be a valid way to provide some vision to patients with advanced outer retinal degeneration and profound vision loss. However, the field of vision for these patients is markedly limited by the area occupied by the electrode array. In this study, we aimed to evaluate the feasibility of implantation of multiple suprachoroidal electrode arrays in a single eye in order to increase the field of vision in patients implanted with retinal prosthesis.

**Methods:** The right eye of seventeen Dutch rabbits (age range, 5–6 months) was used for the study. Multiple inactive custom-made electrode arrays were inserted into the suprachoroidal space (SCS) and animals were followed up for up to 6 months using fundus photography, optical coherence tomography (OCT), and fluorescein angiography (FA).

**Results:** It was possible to surgically implant up to 8 electrode arrays in a single eye. None of the rabbits showed any major complications. The electrodes were well tolerated and remained in position in all rabbits. There was no evidence of retinal damage on follow-up exams and FA throughout the study.

**Conclusion:** Multiple suprachoroidal electrode array implantation is feasible and may provide a novel approach to increase the field of vision in subjects implanted with retinal prosthesis.

Copyright © 2018, Iranian Society of Ophthalmology. Production and hosting by Elsevier B.V. This is an open access article under the CC BY-NC-ND license (<http://creativecommons.org/licenses/by-nc-nd/4.0/>).

**Keywords:** Suprachoroidal; Electrodes; Array; Retinal prosthesis; Retinal implant

## Introduction

Retinitis pigmentosa (RP) is an inherited degenerative retinal disease that leads to specific loss of photoreceptors and retinal pigment epithelium (RPE) ending with severe vision impairment.<sup>1</sup> Using the existing visual pathway to create visual percepts ('phosphenes') by electrical stimulation of the surviving inner retinal neural elements can restore some vision in these patients.<sup>2,3</sup>

Different locations have been proposed for implanting a stimulating array currently under development. These arrays may be placed on the surface of the retina,<sup>4–11</sup> in the subretinal space,<sup>12–15</sup> within the suprachoroidal space (SCS),<sup>16–19</sup> within the scleral tissue,<sup>20</sup> or on the surface of the sclera. With all approaches, the visual field is limited by the surface area of the implanted array.<sup>21</sup> Implantation of a large electrode array can increase visual field; however, this requires large scleral incision and associated complications. A wide-field, round, epiretinal electrode array, 10 mm in diameter, that can be implanted through a similar size sclerotomy as that for Argus II implantation, has been developed and successfully implanted in canines.<sup>22</sup> Similarly, a wide-field suprachoroidal electrode array, 19 × 8 mm, has been successfully implanted in cats.<sup>19</sup> However, even with these wide-field electrode arrays, a large portion of the retina remains uncovered. Implantation of multiple electrode arrays could potentially allow

**Financial disclosure:** Drs Ameri, Weiland, and Humayun have intellectual property on retinal prosthesis.

\* Corresponding author. USC Roski Eye Institute, 1450 San Pablo Street, Los Angeles, CA 90033, USA.

E-mail address: [Ameri@med.usc.edu](mailto:Ameri@med.usc.edu) (H. Ameri).

Peer review under responsibility of the Iranian Society of Ophthalmology.

<https://doi.org/10.1016/j.joco.2017.11.007>

2452-2325/Copyright © 2018, Iranian Society of Ophthalmology. Production and hosting by Elsevier B.V. This is an open access article under the CC BY-NC-ND license (<http://creativecommons.org/licenses/by-nc-nd/4.0/>).

placement of electrode arrays in all quadrants of the eye, dramatically increasing the visual field in patients implanted with retinal prosthesis.

The purpose of this study is to evaluate the feasibility of implantation of multiple electrode arrays in the SCS in rabbits.

## Methods

All animal experiments were conducted in accordance with the Association for Research in Vision and Ophthalmology (ARVO) Statement for the Use of Animals in Ophthalmic and Vision Research.

For all animal procedures, the rabbits were anesthetized with a subcutaneous injection of a mixture of ketamine hydrochloride (25 mg/kg) and xylazine hydrochloride (6 mg/kg).

### Animal groups

Seventeen Dutch rabbits, weighing 2–3 kg, (age range, 5–6 months) were used in the study. Only the right eye of each animal was used for the study, and the follow-up period was 6 months. The pupils were dilated with topical application of phenylephrine hydrochloride 2.5% and tropicamide 0.5% eye drops.

### Test material

Inactive custom-made electrode arrays of 15–25  $\mu\text{m}$  thick, 2 mm wide and 8 mm long, attached to a cable of the same width were used for implantation. The arrays were made of parylene (Fig. 1).

### Surgical procedure

A speculum was used to hold the eyelid open and the periorbital area of one eye was cleaned with a drop of 5% povidone-iodine solution instilled into the fornix.

A limited fornix-based conjunctival peritomy was created using Westcott scissors in the quadrant planned for the implantation. A sclerotomy 2 mm in width, 4 mm behind the limbus, was created using Beaver Blade No. 15 (Beaver-Visitec International Inc, Waltham, MA). Counter-traction was provided by gripping or supporting the limbus, directly opposite to the incision. In some cases, in which there was bulging of the choroid following scleral incision, anterior chamber paracentesis was required to prevent choroidal rupture using a 30° supersharp blade (Katena Products, Inc., Denville, NJ).

The SCS was opened up by injection of Goniosol GONAK<sup>®</sup> (Hypromellose ophthalmic solution 2.5%, Alcon, Inc., Lake Forst, IL), immediately under the sclera followed by advancing the array in the created space for 8–10 mm using blunt conjunctival forceps. The redundant array cable was then cut about 2 mm from the sclerotomy site. Each electrode array was inserted through a separate scleral incision. Fundus exam was then performed to ensure that the array was not misplaced in the subretinal space or perforating into the vitreous cavity. Then the sclerotomy site and the conjunctival peritomy were closed with 6/0 vicryl and 8/0 nylon sutures, respectively.

Analgesia in the form of buprenorphine (Buprenex) IM injection of 0.01–0.05 mg/kg was administered immediately after surgery and 24 h later followed by test article. Gentak (Gentamicin Sulfate Ophthalmic ointment USP, 0.3%,

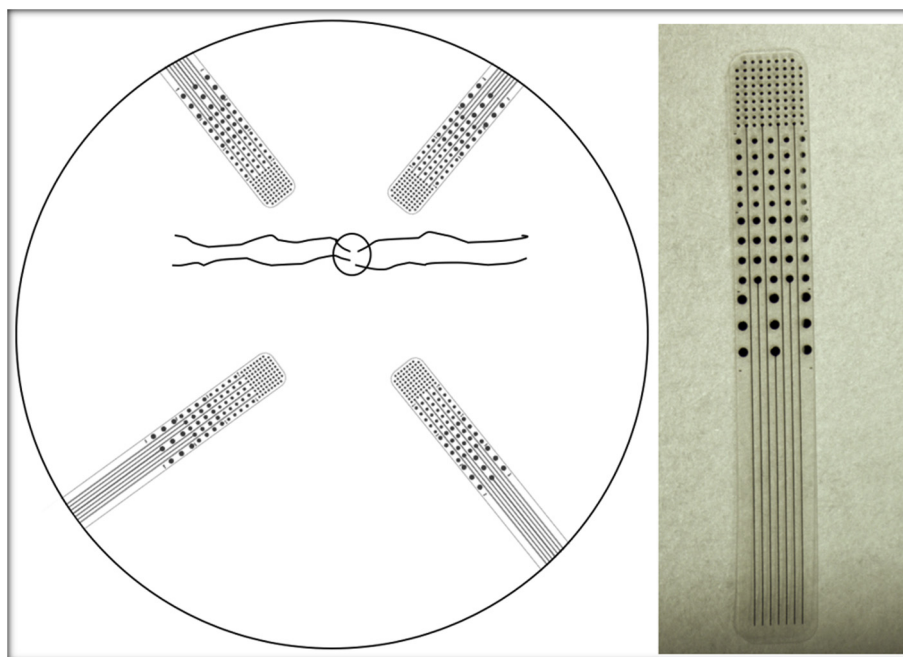


Fig. 1. Suprachoroidal electrode array. Left: Schematic illustration of the posterior segment of a rabbit eye with 4 electrode arrays in 4 different quadrants. Right: Microphotograph of the electrode array.

Perrigo® Minneapolis, MN) topical application was administered 30 min after surgery to reduce the risk of infection.

### Ocular examination

Examinations included intraocular pressure (IOP) measurements using Tonopen-AVIVA (TPA, Reichert Inc., Depew, NY), examination under the surgical microscope, optical coherence tomography (OCT), fundus photography, and fluorescein angiography (FA). Before each session, the rabbits were anesthetized, and the pupils were dilated as described earlier. Baseline examinations were performed right before surgery, and follow-up examinations were performed monthly thereafter until the end of follow-up period.

### Optical coherence tomography

Using time-domain OCT system (Stratus system; ver. 4.0 software; Carl Zeiss Meditec, Inc., Dublin, CA), 5 mm single line scans were taken at the areas of array implantation.

### Fundus photography and fluorescein angiography

The same digital fundus camera system used for fundus photography and FA (model FF 450 IR; Carl Zeiss, Jena, Germany). A marginal ear vein was used to establish an intravenous line. Then 0.2 mL of AK-Fluor® (fluorescein injection 10% – Akorn, Abit Springs, LA) was injected followed by 1 mL of normal saline flush. Sequential fundus photographs were taken immediately after fluorescein injection and up to 5 min after injection. Evaluation included assessment for the presence of areas of retinal ischemia, necrosis, or leakage.

## Results

### Clinical examination and ancillary tests

Table 1 shows the number of implanted arrays in the study animals.

IOP measurements did not show any clinically significant changes from the baseline readings over the 6-month follow-up period in all the study animals. Eye exam revealed minimal conjunctival chemosis overlying the sclerotomy sites that persisted for the first week and decreased gradually thereafter.

Table 1  
Number and site of implants in the test animals.

| Number of electrodes | Number of rabbits | Site of implant   |
|----------------------|-------------------|---|
| 2                    | 3                 | 5, 7 o'clock locations  |
| 3                    | 5                 | 4:30, 7:30, 10:30 o'clock locations in 2<br>4:30, 6, 7:30 o'clock locations in 3    |
| 4                    | 7                 | 1, 11, 7, 5 o'clock locations in 2<br>4:30, 5:30, 6:30, 7:30 o'clock locations in 5 |
| 6                    | 1                 | 3:30, 4:30, 5:30, 6:30, 7:30, 8:30 o'clock locations                                |
| 8                    | 1                 | 3:30, 4:30, 5:30, 6:30, 7:30, 8:30, 11,<br>12 o'clock locations                     |

Fundus examination revealed no abnormal findings in any of the study animals. The implants were easily seen in the albino rabbits compared with the pigment ones. None of the implants was seen to show any signs of displacement or migration from the SCS in any of the study animals over the follow-up period.

On the other hand, FA did not reveal any abnormal vascular leakage or retinal pigment epithelial changes. The implants were hard to detect on the FA images (Fig. 2).

OCT imaging could reveal the actual location of the implant in the SCS. The overlying choroid and retina did not reveal any layer interruption in any of the study animals. No evidence of array migration from the SCS was seen on the OCT imaging (Fig. 3).

No clinical evidence of lateral or axial displacement of the implanted arrays was found in any of the implanted animals after postoperative month-six-fundus images compared to month-one-images.

## Discussion

Dysfunctional photoreceptors are the main marker of retinal degeneration, a worldwide leading cause of vision loss.<sup>23,24</sup> For decades, researchers have been investigating the way to the restore some level of functional vision in these blind people. Despite outer retinal layer reorganization and cell loss in patients with RP and age-related macular degeneration (AMD), it seems that the inner retinal neurons keep the capacity for signal transmission.<sup>2</sup>

Previous studies have found that the density of the ganglion cell in dry AMD does not differ significantly from that in normal eyes, even in retinal areas with virtually no remaining photoreceptors,<sup>25,26</sup> with modest preservation of the inner retinal neurons in patients with severe RP.<sup>27,28</sup>

Electric stimulation of the inner retina has been a well-known method of eliciting neuronal activity at a site within the visual pathway that remains functional regardless of the underlying cause of blindness.<sup>29</sup> This activity then propagates along the remaining intact visual pathway to the visual cortex, resulting in some form of visual perception.<sup>30</sup>

Although different retinal prosthesis systems share similar basic architecture, their specific designs diversify, depending on where the array is intended to be implanted and the complexity of the implanted electronics.

Regardless of the array location, phosphenes are the typical response to such an electrical stimulation, and these phosphenes, when achieving a certain threshold regards the character and number, can be utilized to provide a blind person with useful information about the surroundings.<sup>5,31</sup>

Among various approaches, epiretinal and subretinal prostheses have been commercialized. Both epiretinal and subretinal prostheses have enabled patients to recognize objects, detect motion and have helped them with mobility and activity of daily living.<sup>14,32</sup> Both epiretinal and subretinal prostheses, as well as other experimental approaches, provide a limited field of vision. Although improving central vision could potentially enable these patients in object recognition and

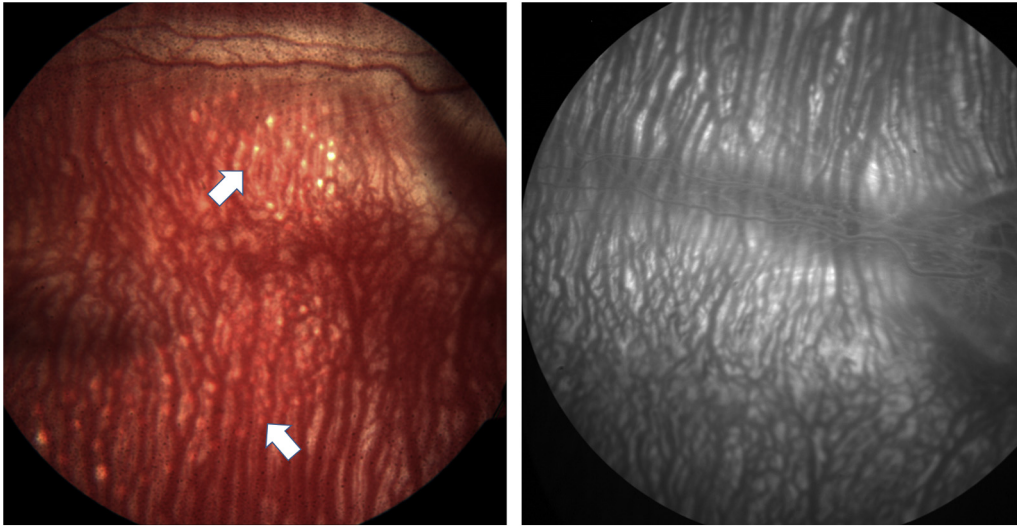


Fig. 2. Fundus photography of rabbit eye with implanted electrode arrays. Color fundus photograph (Left) and fluorescein angiography (FA) (Right) of the right eye of an albino rabbit showing 2 adjacent electrode arrays (indicated by the white arrows). Note difficulty of seeing electrode arrays on fluorescein angiogram and lack of any staining or leakage in the late phase.

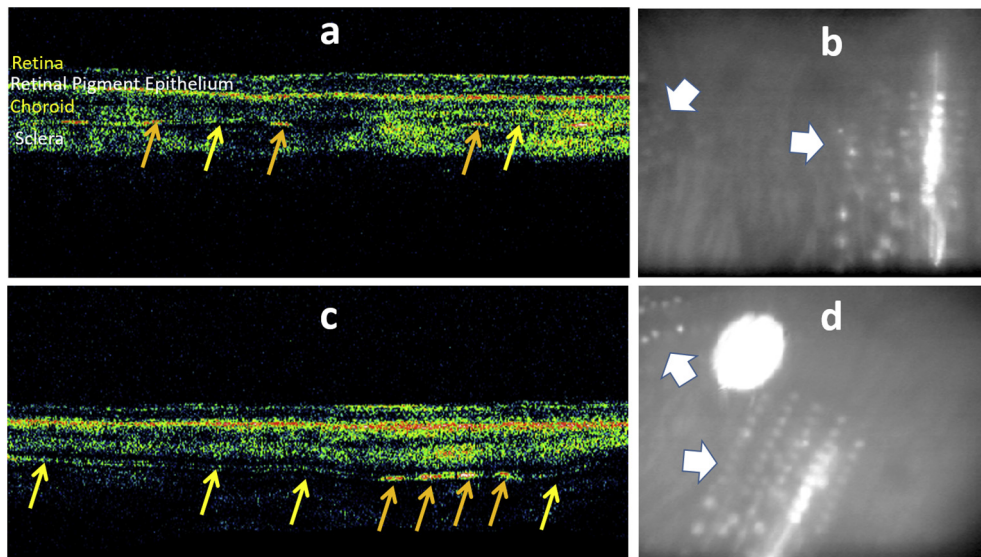


Fig. 3. Fundus imaging of rabbit eyes with implanted electrode arrays. Optical coherence tomography (OCT) of the right eye of 2 rabbits (Top Left, Top Right) with the corresponding fundus picture (Bottom Left, Bottom Right). White arrows on the fundus pictures show adjacent electrode arrays. Yellow arrows show the electrode array on the OCT images located between the choroid and sclera. Hyperreflective spots (orange arrows) show individual electrodes.

reading large prints, increasing the field of vision could significantly increase their mobility. Because of limitations of implantation of a large electrode array, implanting multiple electrode arrays to cover all quadrants of the eye may be a more practical approach. While implantation of multiple epiretinal or subretinal electrode array is challenging and may not be practical, suprachoroidal approach may provide this opportunity. The suprachoroidal approach has been previously shown in both animal and human studies to be a safe technique for the implantation.<sup>16–19,33–41</sup> The main advantage of the suprachoroidal surgical approach is the ease and safety of the surgical procedure. Although because of longer distance of electrodes from the target cells in the suprachoroidal approach,

electrical stimulation may not be as efficient and could further limit the resolution of the vision. Peripheral retina is predominantly used for crude vision and mobility.<sup>42</sup>

One option to provide higher resolution central vision as well as larger field of vision would be to use a prosthesis with combination of approaches.<sup>43</sup> For example, implantation of multiple suprachoroidal electrode arrays with a central epiretinal or subretinal electrode array. In our study, we implanted multiple arrays in the SCS and showed that it is technically feasible and stable over time. To our knowledge, this is the largest animal study showing the feasibility of the surgical implantation of multiple suprachoroidal arrays in the same subject. A prior limited study performed by Lohmann et al<sup>44</sup>

implanted two electrode arrays in two rabbits for two weeks. While implantation of a larger array remains an option, implantation of multiple arrays at the same time can be much easier requiring smaller incision with a faster healing period.

The main difficulties that we faced during this study were the great variability of the anatomy of the posterior segment and low scleral rigidity in rabbits. However, no major complications occurred in any rabbit during the surgery. One of the major concerns that we had at the start of the study was the risk of extrusion or array migration given the number of the arrays and the disturbance of the SCS. However, none of these complications happened in our study indicating that the risk of migration and extrusion is not increased by implanting multiple arrays.

Limitations of the study include the small number of the animals, different anatomy between the rabbit and human eye, and the use of inactive arrays. However, the main aim of this study was to test the possibility of implanting multiple arrays in the same subject and the stability of the arrays over time. Further studies are needed to explore the bioelectrical effects of retinal stimulation by multiple arrays.

In summary, our experimental work points to the feasibility of the implantation of multiple electrode arrays in the SCS to supplement the visual field in patients with retinal degenerative disorders. This can be a way to improve the patient mobility and functionality.

## Acknowledgments

This work was supported by USC James H. Zumberge Research and Innovation Fund and an unrestricted grant from Research to Prevent Blindness.

## References

- Bunker CH, Berson EL, Bromley WC, Hayes RP, Roderick TH. Prevalence of retinitis pigmentosa in Maine. *Am J Ophthalmol*. 1984;97(3):357–365.
- Humayun MS, Prince M, de Juan Jr E, et al. Morphometric analysis of the extramacular retina from postmortem eyes with retinitis pigmentosa. *Invest Ophthalmol Vis Sci*. 1999;40(1):143–148.
- Chai X, Li L, Wu K, Zhou C, Cao P, Ren Q. C-sight visual prostheses for the blind. *IEEE Eng Med Biol Mag*. 2008;27(5):20–28.
- Duncan JL, Richards TP, Arditi A, et al. Improvements in vision-related quality of life in blind patients implanted with the Argus II epiretinal prosthesis. *Clin Exp Optom*. 2017;100(2):144–150.
- Olmos de Koo LC, Gregori NZ. The Argus II retinal prosthesis: a comprehensive review. *Int Ophthalmol Clin*. 2016;56(4):39–46.
- Humayun MS, de Juan Jr E, Dagnelie G. The bionic eye: a quarter century of retinal prosthesis research and development. *Ophthalmology*. 2016;123(10S):S89–S97.
- Castaldi E, Cicchini GM, Cinelli L, Biagi L, Rizzo S, Morrone MC. Visual BOLD response in late blind subjects with Argus II retinal prosthesis. *PLoS Biol*. 2016;14(10):e1002569.
- Rachitskaya AV, Yuan A, Marino MJ, Reese J, Ehlers JP. Intraoperative OCT imaging of the Argus II retinal prosthesis system. *Ophthalmic Surg Lasers Imaging Retina*. 2016;47(11):999–1003.
- Dagnelie G, Christopher P, Arditi A, et al. Performance of real-world functional vision tasks by blind subjects improves after implantation with the Argus(R) II retinal prosthesis system. *Clin Exp Ophthalmol*. 2017;45(2):152–159.
- Dorn JD, Ahuja AK, Caspi A, et al. The detection of motion by blind subjects with the epiretinal 60-electrode (Argus II) retinal prosthesis. *JAMA Ophthalmol*. 2013;131(2):183–189.
- Stronks HC, Dagnelie G. The functional performance of the Argus II retinal prosthesis. *Expert Rev Med Devices*. 2014;11:23–30.
- Gerhardt M, Groeger G, Maccarthy N. Monopolar vs. bipolar subretinal stimulation—an in vitro study. *J Neurosci Methods*. 2011;199(1):26–34.
- Stingl K, Bartz-Schmidt KU, Gekeler F, Kusnyerik A, Sachs H, Zrenner E. Functional outcome in subretinal electronic implants depends on foveal eccentricity. *Invest Ophthalmol Vis Sci*. 2013;54(12):7658–7665.
- Stingl K, Bartz-Schmidt KU, Besch D, et al. Subretinal visual implant alpha IMS—clinical trial interim report. *Vis Res*. 2015;111(PtB):149–160.
- Stingl K, Bartz-Schmidt KU, Braun A, et al. Transfer characteristics of subretinal visual implants: corneally recorded implant responses. *Doc Ophthalmol*. 2016;133(2):81–90.
- Nayagam DA, Williams RA, Allen PJ, et al. Chronic electrical stimulation with a suprachoroidal retinal prosthesis: a preclinical safety and efficacy study. *PLoS One*. 2014;9(5):e97182.
- Fujikado T, Kamei M, Sakaguchi H, et al. Testing of semichronically implanted retinal prosthesis by suprachoroidal-transretinal stimulation in patients with retinitis pigmentosa. *Invest Ophthalmol Vis Sci*. 2011;52(7):4726–4733.
- Villalobos J, Fallon JB, Nayagam DA, et al. Cortical activation following chronic passive implantation of a wide-field suprachoroidal retinal prosthesis. *J Neural Eng*. 2014;11(4):046017.
- Villalobos J, Nayagam DA, Allen PJ, et al. A wide-field suprachoroidal retinal prosthesis is stable and well tolerated following chronic implantation. *Invest Ophthalmol Vis Sci*. 2013;54(5):3751–3762.
- Nakauchi K, Fujikado T, Kanda H, et al. Transretinal electrical stimulation by an intrascleral multichannel electrode array in rabbit eyes. *Graefes Arch Clin Exp Ophthalmol*. 2005;243(2):169–174.
- Rizzo 3rd JF, Wyatt J, Loewenstein J, Kelly S, Shire D. Methods and perceptual thresholds for short-term electrical stimulation of human retina with microelectrode arrays. *Invest Ophthalmol Vis Sci*. 2003;44(12):5355–5361.
- Ameri H, Ratanapakorn T, Ufer S, Eckhardt H, Humayun MS, Weiland JD. Toward a wide-field retinal prosthesis. *J Neural Eng*. 2009;6(3):035002.
- Fariss RN, Li ZY, Milam AH. Abnormalities in rod photoreceptors, amacrine cells, and horizontal cells in human retinas with retinitis pigmentosa. *Am J Ophthalmol*. 2000;129(2):215–223.
- Friedman DS, O'Colmain BJ, Munoz B, et al. Prevalence of age-related macular degeneration in the United States. *Arch Ophthalmol*. 2004;122(4):564–572.
- Kim SY, Sadda S, Pearlman J, et al. Morphometric analysis of the macula in eyes with disciform age-related macular degeneration. *Retina*. 2002;22(4):471–477.
- Medeiros NE, Curcio CA. Preservation of ganglion cell layer neurons in age-related macular degeneration. *Invest Ophthalmol Vis Sci*. 2001;42(3):795–803.
- Weiland JD, Cho AK, Humayun MS. Retinal prostheses: current clinical results and future needs. *Ophthalmology*. 2011;118(11):2227–2237.
- Santos A, Humayun MS, de Juan Jr E, et al. Preservation of the inner retina in retinitis pigmentosa. A morphometric analysis. *Arch Ophthalmol*. 1997;115(4):511–515.
- Eckhorn R, Wilms M, Schanze T, et al. Visual resolution with retinal implants estimated from recordings in cat visual cortex. *Vis Res*. 2006;46(17):2675–2690.
- Margalit E, Thoreson WB. Inner retinal mechanisms engaged by retinal electrical stimulation. *Invest Ophthalmol Vis Sci*. 2006;47(6):2606–2612.
- Yue L, Weiland JD, Roska B, Humayun MS. Retinal stimulation strategies to restore vision: fundamentals and systems. *Prog Retin Eye Res*. 2016;53:21–47.
- Ho AC, Humayun MS, Dorn JD, et al. Long-term results from an epiretinal prosthesis to restore sight to the blind. *Ophthalmology*. 2015;122(8):1547–1554.

33. Barnes N, Scott AF, Lieby P, et al. Vision function testing for a suprachoroidal retinal prosthesis: effects of image filtering. *J Neural Eng.* 2016; 13(3):036013.
34. Yan Y, Sui X, Liu W, et al. Spatial characteristics of evoked potentials elicited by a MEMS microelectrode array for suprachoroidal-transretinal stimulation in a rabbit. *Graefes Arch Clin Exp Ophthalmol.* 2015; 253(9):1515–1528.
35. Shivdasani MN, Sinclair NC, Dimitrov PN, et al. Factors affecting perceptual thresholds in a suprachoroidal retinal prosthesis. *Invest Ophthalmol Vis Sci.* 2014;55(10):6467–6481.
36. Terasawa Y, Tashiro H, Nakano Y, Osawa K, Ozawa M. Safety assessment of semichronic suprachoroidal electrical stimulation to rabbit retina. *Conf Proc IEEE Eng Med Biol Soc.* 2013;2013:3567–3570.
37. John SE, Shivdasani MN, Williams CE, et al. Suprachoroidal electrical stimulation: effects of stimulus pulse parameters on visual cortical responses. *J Neural Eng.* 2013;10(5):056011.
38. Cicione R, Shivdasani MN, Fallon JB, et al. Visual cortex responses to suprachoroidal electrical stimulation of the retina: effects of electrode return configuration. *J Neural Eng.* 2012;9(3):036009.
39. Morimoto T, Kamei M, Nishida K, et al. Chronic implantation of newly developed suprachoroidal-transretinal stimulation prosthesis in dogs. *Invest Ophthalmol Vis Sci.* 2011;52(9):6785–6792.
40. Saunders AL, Williams CE, Heriot W, et al. Development of a surgical procedure for implantation of a prototype suprachoroidal retinal prosthesis. *Clin Exp Ophthalmol.* 2014;42(7):665–674.
41. Fujikado T, Morimoto T, Kanda H, et al. Evaluation of phosphenes elicited by extraocular stimulation in normals and by suprachoroidal-transretinal stimulation in patients with retinitis pigmentosa. *Graefes Arch Clin Exp Ophthalmol Albrecht von Graefes Archiv fur klinische und Exp Ophthalmol.* 2007;245(10):1411–1419.
42. Palanker D, Vankov A, Huie P, Baccus S. Design of a high-resolution optoelectronic retinal prosthesis. *J Neural Eng.* 2005;2(1):S105–S120.
43. Ameri H. Retinal prosthesis, potential future approaches. *Clin Exp Ophthalmol.* 2014;42(7):599–600.
44. Lohmann TK, Kanda H, Morimoto T, et al. Surgical feasibility and biocompatibility of wide-field dual-array suprachoroidal-transretinal stimulation prosthesis in middle-sized animals. *Graefes Arch Clin Exp Ophthalmol.* 2016;254(4):661–673.