

Evaluation of sagittal alignment and range of motion of the cervical spine using multi-detector-row computed tomography in asymptomatic subjects

Akinori Kobayakawa¹, Fumihiko Kato², Keigo Ito², Masaaki Machino¹, Shunsuke Kanbara¹, Daigo Morita¹, and Taro Matsumoto²

¹Department of Orthopedic Surgery, Nagoya University Graduate School of Medicine, Nagoya, Japan
²Department of Orthopedic Surgery, Chubu Rosai Hospital, Japan Labor Health and Welfare Organization, Nagoya, Japan

ABSTRACT

To evaluate the sagittal alignment and range of motion (ROM) of the cervical spine during cervical flexion and extension, using multi-detector-row-computed tomography (MDCT) in asymptomatic subjects. Understanding the normal alignment and range of motion of the cervical spine is very important while evaluating patients with cervical spine instability and abnormal alignment. Several reports using plain radiographic data have assessed the alignment and ROM of the cervical spine during flexion and extension. However, there has been no such report using MDCT. Ninety-eight subjects who did not have cervical spine-related symptoms were enrolled. After myelography, all subjects underwent cervical MDCT in cervical flexion and extension. Sagittal alignment and ROM between C2 and C7 were measured. The sagittal alignment between C2 and C7 was $-11.7^{\circ} \pm 8.3^{\circ}$ (mean \pm standard deviation) in flexion and $26.5^{\circ} \pm 12.9^{\circ}$ in extension. The C5/6 level showed maximum kyphosis in flexion. The C6/C7 level demonstrated maximum lordosis in extension. ROM between C2 and C7 was $37.9^{\circ} \pm 11.2^{\circ}$. The C2/3 level showed the lowest ROM and the C5/C6 level showed the highest ROM among the intervertebral levels evaluated. The sagittal alignment and ROM of the cervical spine during flexion and extension in asymptomatic subjects were measured using MDCT. Each level between C2 and C7 could be evaluated in detail without any influence due to degenerative changes in the spine or soft tissues of the shoulder. MDCT generated a more precise understanding of the dynamic changes at each evaluated intervertebral level in the cervical spine.

Level of Evidence : Level II

Keywords: cervical spine, sagittal alignment, multi detector-row-computed tomography, kyphosis, lordosis, range of motion

This is an Open Access article distributed under the Creative Commons Attribution-NonCommercial-NoDerivatives 4.0 International License. To view the details of this license, please visit (<http://creativecommons.org/licenses/by-nc-nd/4.0/>).

INTRODUCTION

Several studies have used plain radiography, for assessing the alignment and range of motion

Received: March 9, 2018; accepted: June 12, 2018

Corresponding Akinori Kobayakawa, MD

Department of Orthopedic Surgery, Chubu Rosai Hospital, Japan Labor Health and Welfare Organization,
1-10-6 Komei, Minato-ku, Nagoya, 455-8530, Japan

Tel: +81-052-652-5511, Fax: +81-052-652-5716, E-mail: aki.koba@med.nagoya-u.ac.jp

(ROM) of the cervical spine during cervical flexion and extension.¹⁻⁴⁾ However, these results are not always consistent. In addition, accurate evaluation was not possible in some cases because of the influence of posture and rotation, such as the overlap between the soft tissues of the shoulder and the cervical spine. In recent years, cervical spine has been evaluated in detail using multi-detector-row computed tomography (MDCT).⁵⁻⁷⁾ With this measurement method, the shape of the vertebral body can draw a clearer image than X-ray. Therefore, more accurate measurement can be expected for each vertebral body. However, no report investigated the sagittal alignment and ROM of the cervical spine during flexion and extension in asymptomatic subjects using MDCT. Therefore, the aim of this study was to identify the sagittal alignment and ROM of the cervical spine at each segmental level using MDCT. In addition to the knowledge of the cervical vertebra reported in past X-ray measurements, it can be expected that this study, which shows results with different measurement methods, may help to obtain further knowledge.

MATERIALS AND METHODS

Study population

A total of 98 patients (64 males, 34 females; mean age 47.3±14.4 years; range 21–77 years) who were admitted to our hospital for the treatment of lumbar disc herniation from January 2010 to December 2011 were prospectively enrolled in this study.

Cervical disc herniation, spondylosis, ossification of the posterior longitudinal ligament, vertebral fusion, tumors, or instability /abnormal alignment of the cervical spine were ruled out in all patients using plain radiography, CT, and magnetic resonance imaging; in addition, no patients had any cervical spine-related symptom.

After preoperative myelography for the diagnosis of lumbar disc herniation, MDCT of the cervical spine was performed in both maximum flexion and extension. The aims of this study were explained to all patients before myelography and CT, and all patients provided informed consent for participation. This study was approved by the hospital institutional review board.

CT in spinal flexion and extension

Pillows and/or folded towel were placed below the head for cervical flexion and between the shoulders for cervical extension.

In this study, by adjusting the position and amount of pillows and towels, we can evaluate the maximum extension and maximum flexion position as far as possible even in the supine position. It took approximately 5 seconds to perform MDCT [5,6]. A 64-line, multislice CT (Light Speed VCT; GE Healthcare Bio-Sciences, Piscataway, NJ, USA) was used. The images were taken perpendicularly as far as possible for each disc level between C2/C3 and C7/T1.

Measurement and data analysis

All CT images were transferred to a microcomputer and all parameters measured twice using Scion Imaging Software (Digitalcore Co.Ltd, Onis 2.1, Tokyo, Japan): mean data were calculated. Lordotic angle of each segment (between C2/C3 and C7/T1) was measured in the sagittal plane with reference to the lower edge of the vertebral body, similar to the measurement of Cobb's angle. Lordotic angles were indicated by a plus sign(+) and kyphotic angles were indicated by a minus sign(-). Total lordotic angle (between C2 and C7) was calculated as the summation of each segmental lordotic angle (between C2/C3 and C6/C7). Total and segmental ROM were then calculated [ROM = (lordotic angle at maximum extension) – (lordotic angle at maximum flexion)]. In order to reduce errors due to the measurement method, a single orthopedic surgeon

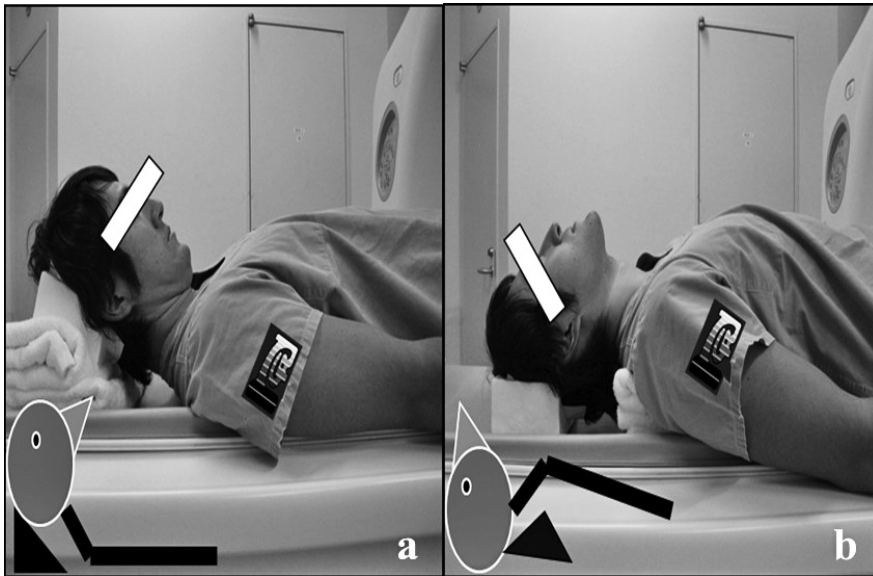


Fig. 1 Subject's position during flexion (a) and extension (b) of the cervical spine while performing computed tomography

Fig. 1a: Pillows and a folded bath towel supporting the back of the head.

Fig. 1b: A folded bath towel supporting the area between the shoulders.

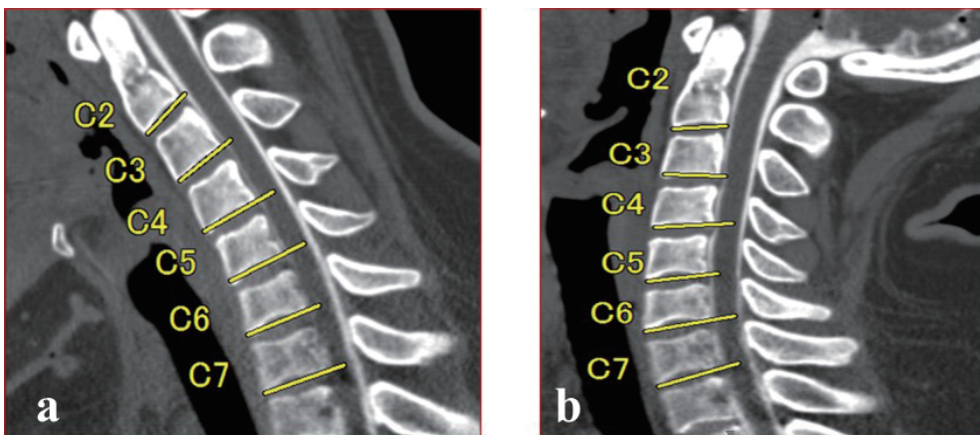


Fig. 2 Computed tomography images of the cervical spine in the sagittal plane following myelography (a) flexion, (b) extension

measured the same site twice, and the average value was taken as the result.

RESULTS

Sagittal alignment (angle)

Sagittal alignment between C2 and C7 was $-11.7^{\circ} \pm 8.3^{\circ}$ (mean \pm standard deviation) in flexion,

and $26.5^{\circ} \pm 12.9^{\circ}$ in extension.

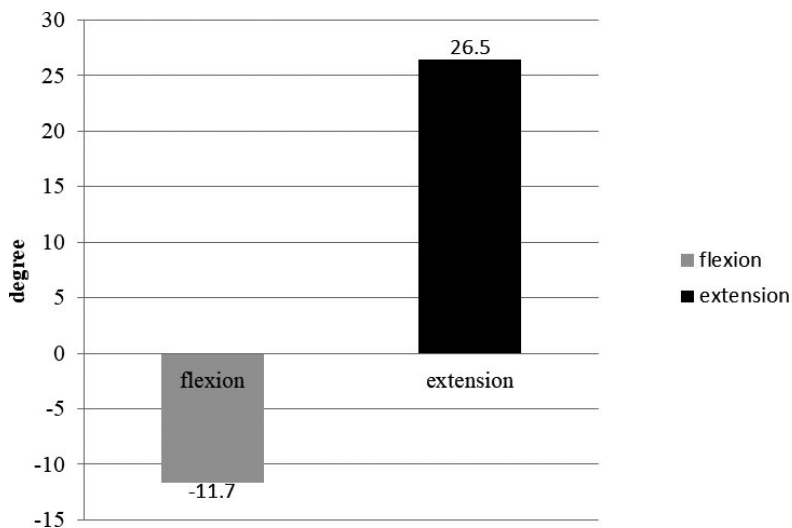


Fig. 3 Sagittal alignment (lordotic angle) during flexion and extension of the cervical spine.

Sagittal alignment between C2 and C7 shows lordosis in flexion: $-11.7^{\circ} \pm 8.3^{\circ}$ and kyphosis in extension: $26.5^{\circ} \pm 12.9^{\circ}$

Segmental lordotic angles in flexion were $-3.3^{\circ} \pm 2.6^{\circ}$ at C2/C3, $-3.2^{\circ} \pm 2.4^{\circ}$ at C3/C4, $-3.8^{\circ} \pm 2.6^{\circ}$ at C4/C5, $-4.0^{\circ} \pm 2.7^{\circ}$ at C5/C6, $-2.1^{\circ} \pm 2.6^{\circ}$ at C6/C7 those in extension were $2.8^{\circ} \pm 2.6^{\circ}$ at C2/C3, $4.2^{\circ} \pm 3.2^{\circ}$ at C3/C4, $5.6^{\circ} \pm 3.2^{\circ}$ at C4/C5, $5.6^{\circ} \pm 3.9^{\circ}$ at C5/C6, and $6.9^{\circ} \pm 3.7^{\circ}$ at C6/C7.

The maximum kyphosis angle in flexion was at the C5/C6 disc level, and the maximum lordosis in extension was at the C6/C7 disc level.

ROM

ROM between C2 and C7 was $37.9^{\circ} \pm 11.2^{\circ}$. Segmental ROM was $6.1^{\circ} \pm 3.8^{\circ}$ at C2/C3, $7.4^{\circ} \pm 3.6^{\circ}$ at C3/C4, $9.3^{\circ} \pm 3.8^{\circ}$ at C4/C5, $9.7^{\circ} \pm 3.9^{\circ}$ at C5/C6, $8.9^{\circ} \pm 4.3^{\circ}$ at C6/C7.

ROM gradually increased from C2/C3 to C5/C6 and decreased from C5/C6 to C6 /C7. The C2/C3 level showed the least ROM and the C5/C6 level showed the maximum ROM among the levels evaluated.

Alignment of the cervical spine

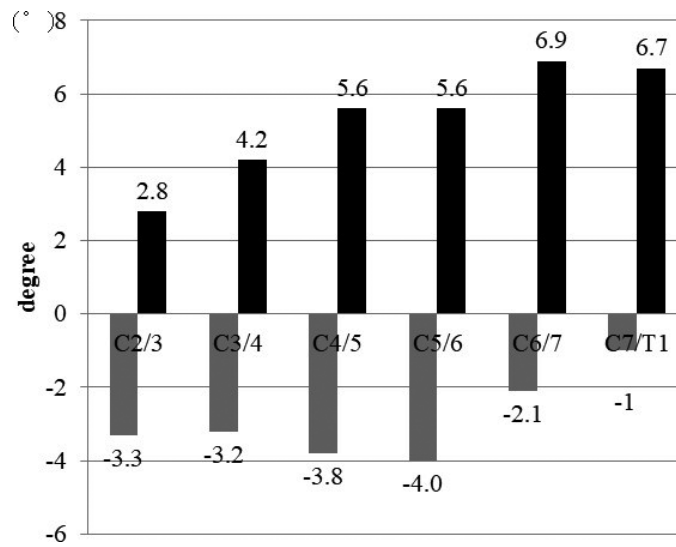


Fig. 4 Segmental lordotic angles in flexion and in extension of the cervical spine.
The maximum lordosis in flexion was at C5/C6 and the maximum kyphosis in extension was at C6/C7.

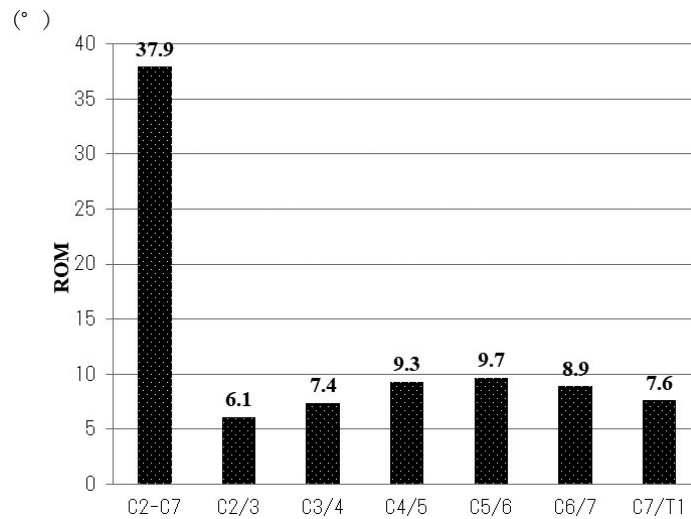


Fig. 5 Range of motion (ROM) of the cervical spine
ROM between C2 and C7 was $37.9^{\circ} \pm 11.2^{\circ}$. Segmental ROM gradually increased from C2/C3 to C5/C6 and decreased from C5/C6 to C6/C7.

DISCUSSION

Functional MDCT could evaluate the sagittal alignment and ROM between C2 and C7 in detail without any influence of degeneration of spine and soft tissues of shoulder.

The cervical spine showed a total of 37.9° ROM in the sagittal plane, measured by flexion-extension CT. This value was lower than that measured by plain radiography in many previous studies. With regard to segmental ROM, the minimum and maximum was at C2/C3 and C5/C6, respectively.

Several studies evaluating the alignment and ROM of the cervical spine in flexion and extension using plain radiography have been reported.

However, accurate evaluation was difficult in some cases because of the influence of posture and rotation, such as the overlap between the soft tissues of the shoulder and the cervical spine, especially during the assessment of the lower cervical spine.

Evaluation using MDCT is not influenced by soft tissue shadows and it is possible to observe the vertebral end plates clearly, even though images are taken only in the supine position. In comparison with reports using plain radiography, the lordotic angles generally had lower values in our study. However, dynamic changes in each segmental levels showed a similar trend. Segmental lordotic angles in extension also showed lower values on the whole, particularly in C4/C5. This suggests that cervical extension was limited because of the supine position in our study.

To obtain more accurate measurements, a better imaging position for the evaluation in cervical extension is required.

Holmes reported the normal functional ROM of the total cervical spine as 67.2°²⁾ and Lind reported as 66.0°.³⁾ Sagittal ROM from C2 to C7 was 55.3°±16.0° according to the results of medical evaluations on the cervical spine performed on 1200 healthy volunteers.⁴⁾ However all data in these studies were obtained using plain radiography.

ROM of the whole cervical spine in our study showed generally lower values, similar to the segmental lordotic angles. Dynamic changes of ROM in each intervertebral disc level showed a similar trend to those observed in previous reports. ROM at each level gradually increased from C2/C3 to C5/C6 and decreased from C5/C6 to C6 /C7.

Compared with the results of previous studies, ROM values obtained in the present study was approximately 70 %. It is likely that extension was limited because of the supine position used in our study. Which led to the observation of a lower range of motion; however, we were able to make a more accurate assessment of alignment and ROM of cervical spine at the segmental level.

The cervical region is the most mobile region of the spine and allows for a wide range of motion. The human spine is also subjected to large compressive preloads during the activities of daily life. Recently other studies have shown the efficacy of kinematic CT myelography to investigate dynamic factors in patients with cervical spondylotic myelopathy.^{5,7)}

There are several potential limitations to the present study. The kinematic studies were performed only during cervical flexion and extension and not in the neutral position. The examination of three different positions may have revealed interesting patterns of dynamic changes; however, this would have further increased patient's risk of radiation exposure. In the evaluation of dynamic instability, the elements of gravity and range of motion are very important. Unfortunately, we can not evaluate the gravity, although we can focus on the range of motion due to the characteristics of the inspection in this research. Despite these limitations, kinematic CT myelography was useful for evaluating the dynamic causative factors.

CONCLUSION

Sagittal alignment and ROM of the cervical spine at the segmental level were investigated using functional MDCT. By combining the results of this study with past X-ray evaluation, we can further understand dynamic anatomy of the asymptomatic cervical spine.

CONFLICT OF INTEREST

None.

REFERENCES

- 1) Lin RM, Tsai KH, Chu LP, Chang, PQ. Characteristics of sagittal vertebral alignment in Flexcion determined by dynamic radiographs of the cervical spine. *Spine*, 2001; 26: 256–261.
- 2) Holmes A, Wang C, Han ZH, Dang GT. The range and nature of flexion-extension motion in the cervical spine. *Spine*, 1994; 19: 2505–2510.
- 3) Lind B, Sihlbom H, Nordwall A, Malchau H. Normal range of motion of the cervical spine. *Arch Phys Med Rehab*, 1989; 70: 692–695.
- 4) Yukawa Y, Kato F, Suda K, Yamagata M, Ueta T. Age-related changes in osseous anatomy, alignment, and range of motion of the cervical spine. Part I: Radiographic data from over 1,200 asymptomatic subjects. *Eur Spine J*, 2012; 21: 1492–1498.
- 5) Machino M, Yukawa Y, Ito K, Nakashima H, Kato F. Dynamic changes in dural sac and spine cord cross-sectional area in patients with cervical spondylotic myelopathy. *Spine*, 2011; 36: 399–403.
- 6) Ito K, Yukawa Y, Machino M, Kato F. Spinal cord cross-sectional area during flexion and extension in the patients with cervical ossification of posterior longitudinal ligament. *Eur Spine J*, 2013; 22: 2564–2568.
- 7) Yoshii T, Yamada T, Hirai T, Taniyama T, Kato T, Enomoto M, *et al.* Dynamic changes in spinal cord compression by cervical ossification of the posterior longitudinal ligament evaluated by kinematic computed tomography myelography. *Spine*, 2014; 39: 113–119.