

Bilateral video-assisted thoracoscopic surgery in tracheotomised patients: E-Z blocker, a promising alternative

Sir,

One-lung ventilation (OLV) in a tracheotomised patient is very challenging to the anaesthesiologists, especially if surgery is performed bilaterally. EZ-blocker (Teleflex Life Sciences Ltd.; Ireland) provides an easy solution for OLV in sequential bilateral video-assisted thoracoscopic surgery (VATS). Informed consent from the patient was obtained for possible publication.

A 78-year-old, post-coronavirus disease 2019 (COVID-19), tracheotomised patient was admitted to the intensive care unit (ICU) for 7 months. He was also a known case of CKD (chronic kidney disease), DM (diabetic mellitus) and IHD (ischaemic heart disease) with an ejection fraction of 20%. He was on mechanical ventilation with high oxygen and noradrenaline support. During his ICU course, he developed an episode of ventilator-associated pneumonia (VAP) and acute kidney injury for which he underwent dialysis twice. He had two episodes of cardiac arrest during the ICU course. High-resolution computed tomography (HRCT) of the chest revealed empyema and collapse on both sides of the lung. The patient was posted for bilateral VATS for lung decortication. After the application of routine American Society of Anesthesiologists (ASA) monitoring, the patient was induced with injections of fentanyl 2 µg/kg, etomidate 0.2 mg/kg and rocuronium 0.8 mg/kg. After induction, a multiport adaptor was connected to the tracheostomy tube. With the help of a 3.7 mm internal diameter (ID) fibre-optic bronchoscope (FOB), the EZ-blocker was anchored at the carina and its extensions into the right and left main bronchus [Figure 1]. Sequential OLV was achieved by inflating the left and right cuff. The total time taken for EZ-blocker insertion was 3 min. The condition of lung collapse was satisfactory during the procedure. The surgery took 210 min. At the end of the surgical procedure, the EZ-blocker was removed and the patient was shifted to the ICU.

Devices available for OLV include a double-lumen tube (DLT), bronchial blocker (BB) and uninvent tube. DLT is the most commonly used device for

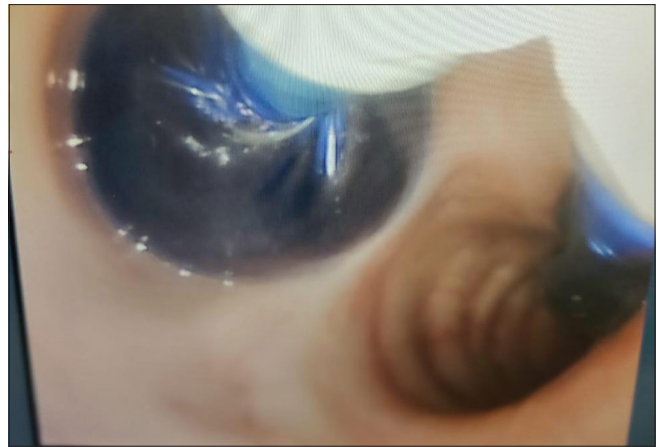


Figure 1: EZ-blocker anchored at the carina and its extensions into the right and left main bronchus

OLV in the normal airway, but it is difficult to place in a tracheotomised patient due to rigidity and its high probability of causing airway trauma and bleeding.^[1,2] The use of a shorter version of DLT in the tracheotomised patient has been reported in the literature.

BB is the most commonly used device for OLV in a tracheotomised patient, but it is difficult to position, has limited suction ability, and gets frequently dislodged during surgical manipulation and patient positioning.^[3] There is also a need for repositioning to the opposite side in case of bilateral procedures.

EZ-Blocker (Teleflex Life Sciences Ltd., Athlone, Ireland) (EZB) is a 7 French, 75 cm long, 4-lumen, Y-shaped semi-rigid endobronchial catheter, that can be placed either via a single-lumen tube (SLT) or tracheostomy tube under the FOB guidance [Figure 2].^[4] Its unique shape allows it to fit at the carina with two distal ends into the left and the right mainstream bronchi, making it less prone to dislodgement, especially during surgical manipulations and patient positioning. Both its distal ends have colour coded inflatable cuffs which can be inflated by two independent pilot balloons, and by inflating the cuff on the selected side, we can block the bronchus of that side to achieve OLV.

A study reported that EZ-blocker is comparable to DLT in terms of quality of lung deflation and causes less trauma and sore throat than DLT.^[5] A retrospective analysis of 100 patients undergoing thoracic surgery concluded that the EZ-blocker is an efficient, easy-to-use and safe airway device for OLV especially when DLT insertion is difficult.^[6]

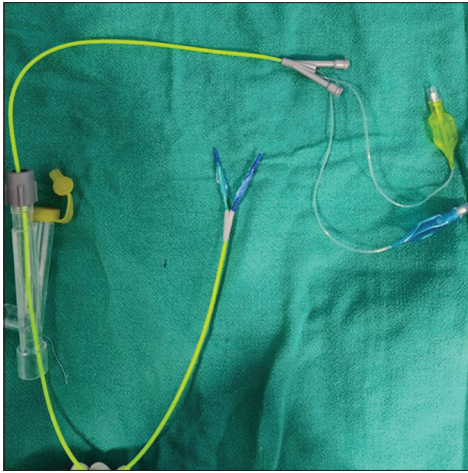


Figure 2: EZ -Blocker (Teleflex Life Sciences Ltd., Athlone, Ireland) (EZB) (Teleflex Life Sciences Ltd.; Ireland)

In our patient, who had a high oxygen requirement, removal of the tracheostomy tube and oral insertion of DLT would have led to hypoxia. EZ-blocker is the only available adjunct that provides sequential OLV for bilateral VATS without the need for repositioning during the intraoperative period. EZ-blocker is a simple and easy method of achieving OLV.

Declaration of patient consent

The authors certify that they have obtained all appropriate patient consent forms. In the form, the patient(s) has/have given his/her/their consent for his/her/their images and other clinical information to be reported in the journal. The patients understand that their names and initials will not be published and due efforts will be made to conceal their identity, but anonymity cannot be guaranteed.

Financial support and sponsorship

Nil.

Conflicts of interest

There are no conflicts of interest.

**Rakesh Kumar, Manoj Kamal, Pradeep Bhatia,
Pallavi Sahoo**

Department of Anaesthesiology and Critical Care, All India Institute of Medical Sciences, Jodhpur, Rajasthan, India

Address for correspondence:

Dr. Rakesh Kumar,
Department of Anaesthesiology and Critical Care, All India
Institute of Medical Sciences, Jodhpur - 342 005, Rajasthan, India.
E-mail: drakeshspmc@gmail.com

Submitted: 12-Oct-2021

Revised: 21-Feb-2022

Accepted: 15-Apr-2022

Published: 19-May-2022

REFERENCES

1. Purohit A, Bhargava S, Mangal V, Parashar VK. Lung isolation, one-lung ventilation and hypoxemia during lung isolation. *Indian J Anaesth* 2015;59:606-17.
2. Campos JH. Lung isolation techniques for patients with difficult airway. *Curr Opin Anaesthesiol* 2010;23:12-7.
3. Campos JH. Which device should be considered the best for lung isolation: Double-lumen endotracheal tube versus bronchial blockers. *Curr Opin Anaesthesiol* 2007;20:27-31.
4. Rispoli M, Nespoli MR, Salvi R, Corcione A, Buono S. One-lung ventilation in tracheostomized patients: Our experience with EZ-Blocker. *J Clin Anesth* 2016;31:288-90.
5. Mourisse J, Liesveld J, Verhagen A, van Rooij G, van der Heide S, Schuurbiens-Siebers O, *et al.* Efficiency, efficacy, and safety of EZ-blocker compared with left-sided double-lumen tube for one-lung ventilation. *Anesthesiology* 2013;118:550-61.
6. Moritz A, Irouschek A, Birkholz T, Prottegeier J, Sirbu H, Schmidt J. The EZ-blocker for one-lung ventilation in patients undergoing thoracic surgery: Clinical applications and experience in 100 cases in a routine clinical setting. *J Cardiothorac Surg* 2018;13:77.

This is an open access journal, and articles are distributed under the terms of the Creative Commons Attribution-NonCommercial-ShareAlike 4.0 License, which allows others to remix, tweak, and build upon the work non-commercially, as long as appropriate credit is given and the new creations are licensed under the identical terms.

| Access this article online | |
|--------------------------------------------------------------------------------------|--------------------------------|
| Quick response code | Website: www.ijaweb.org |
|  | DOI: 10.4103/ija.ija_918_21 |

How to cite this article: Kumar R, Kamal M, Bhatia P, Sahoo P. Bilateral video-assisted thoracoscopic surgery in tracheotomised patients: E-Z blocker, a promising alternative. *Indian J Anaesth* 2022;66:384-5.

© 2022 Indian Journal of Anaesthesia | Published by Wolters Kluwer - Medknow