



Contents lists available at ScienceDirect

International Journal of Surgery Case Reports

journal homepage: www.casereports.com

Splenic cyst during pregnancy



Oliver Varban*

University of Michigan Health Systems, 2210 Taubman Center, 1500 E Medical Center Drive, SPC 5343, Ann Arbor, MI 48109-5343, United States

ARTICLE INFO

Article history:

Received 20 May 2013

Received in revised form 21 March 2014

Accepted 26 March 2014

Available online 13 April 2014

Keywords:

Splenic cyst

Pregnancy

Laparoscopy

ABSTRACT

INTRODUCTION: Splenic cyst during pregnancy is rare and may result in spontaneous rupture during the third trimester, which increases perinatal mortality.

PRESENTATION OF CASE: We present a 27-year-old healthy Caucasian female who presented at 18 weeks gestation with left flank pain, early satiety and weight loss. Imaging studies demonstrated a large complex multiloculated splenic cyst. The patient underwent a successful laparoscopic splenectomy and delivered a healthy child at term without complication.

DISCUSSION: Spontaneous rupture of a splenic cyst during the third trimester incurs a perinatal mortality rate as high as 70%. Surgical management includes open or laparoscopic splenectomy or fenestration and preservation of the spleen.

CONCLUSION: Laparoscopic splenectomy during the second trimester appears to be safe and offers definitive management of a large symptomatic splenic cyst during pregnancy.

© 2014 The Authors. Published by Elsevier Ltd. on behalf of Surgical Associates Ltd. This is an open access article under the CC BY-NC-ND license (<http://creativecommons.org/licenses/by-nc-nd/3.0/>).

1. Introduction

The incidence of splenic cysts in the general population is low with only 800 cases reported worldwide.¹ Splenic cysts during pregnancy are even more rare with only 8 cases reported thus far.² Types of cysts documented include cystic spuria, hydatid, epithemoid and pseudocyst.^{2–8} Cysts larger than 5 cm in diameter are more likely to be symptomatic and the most feared complication is spontaneous rupture.^{1,9} Rupture results in hemoperitoneum, peritonitis, abscess or shock and is related with a perinatal mortality as high as 70%.¹⁰

2. Presentation of case

A 27-year-old Caucasian female presented at 18 weeks gestation with left sided flank discomfort, early satiety and weight loss. She underwent ultrasound imaging that detected a splenic cyst. This was further evaluated by magnetic resonance imaging (MRI), which demonstrated a complex, multiloculated cystic lesion, which measured 11 cm × 6.6 cm × 11.4 cm (Fig. 1a and b). The splenic vasculature was patent and there was no evidence of an aneurysm.

The patient had a prior miscarriage at 6 weeks gestation and her past medical history was significant for mononucleosis. She did not have a history of trauma, recent travel or illness. She did not have any prior abdominal surgery. She also denied family history of lymphoma. Laboratory studies included an IgG level that

was within normal limits indicating that she did not harbor a parasitic (hydatid) cyst. Given the increased risk of rupture and fetal loss during the third trimester, we proceeded with a laparoscopic splenectomy. The patient was given meningococcal, pneumococcal and influenza vaccines 2 weeks preoperatively.

Given the patient's symptoms of pain and associated weight-loss as well as the possibility of cyst rupture or infection in the setting of pregnancy, intervention was recommended over conservative management. All treatment options including drainage, fenestration, marsupialization and partial vs. total splenectomy were considered preoperatively and discussed with the patient at great length. The risks and benefits of each intervention were compared with respect to likelihood of cyst recurrence, need for re-intervention, as well as potential complications and time to recovery. Splenic preservation could be accomplished with simple drainage, fenestration, marsupialization or partial splenectomy. However given the size of the cyst and its many loculations, which abutted the splenic vessels, pancreas, stomach and colon, it would have been technically challenging and may have lead to early recurrence, bleeding or infection as well as the need for further intervention. By performing a laparoscopic splenectomy, a single intervention could be performed relatively safely with the least likelihood for recurrence and with a shorter recovery time, when compared to an open operation.

A laparoscopic splenectomy was performed through 5 ports. The patient was placed in full right decubitus position and essentially lying on her right flank, in order to avoid compression of the inferior vena cava by the fetus. There were no hypotensive episodes experienced during surgery and the patient positioning provided excellent visualization of the spleen and associated vasculature.

* Tel.: +734 936 5792; fax: +734 936 5830.

E-mail address: ovarban@med.umich.edu

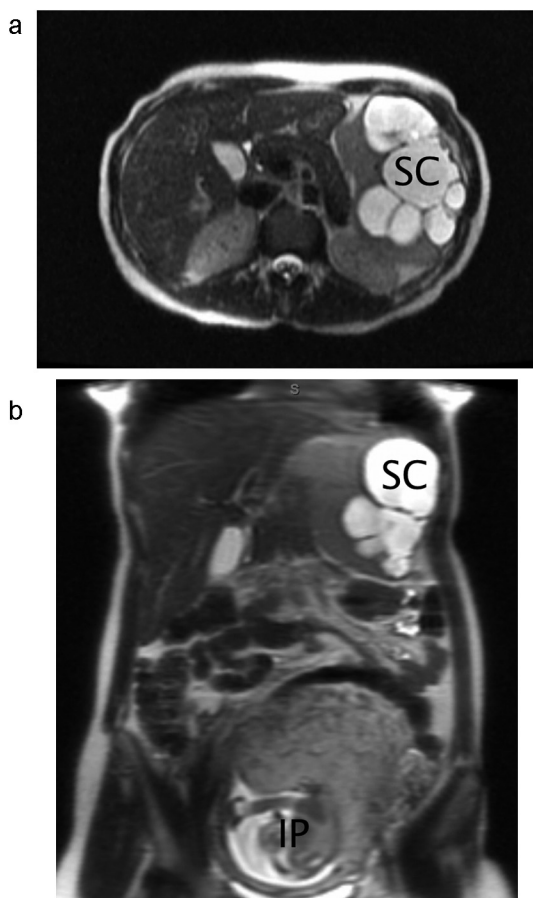


Fig. 1. (a) MRI (axial) of splenic cyst (SC). (b) MRI (coronal) of splenic cyst (SC) also demonstrating the intrauterine pregnancy (IP).

A large multiloculated splenic cyst was identified laparoscopically (Fig. 2). The operative technique involved initial exposure and dissection of the splenic vasculature, use of surgical staplers to divide the splenic artery and vein and finally, dissection of the spleen from the splenocolic and splenophrenic ligaments.

The operative time was 4 h and 30 min and blood loss was estimated at 300cc. The specimen was placed into a sterile laparoscopic bag and then morcellated within the bag, prior to removal through the umbilical port (Fig. 3). The patient was discharged on postoperative day 4. There were no postoperative complications and the

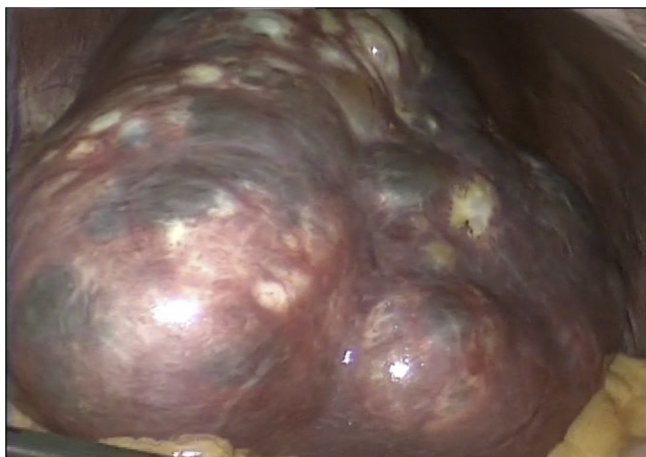

Fig. 2. Intraoperative image of splenic cyst during laparoscopy.

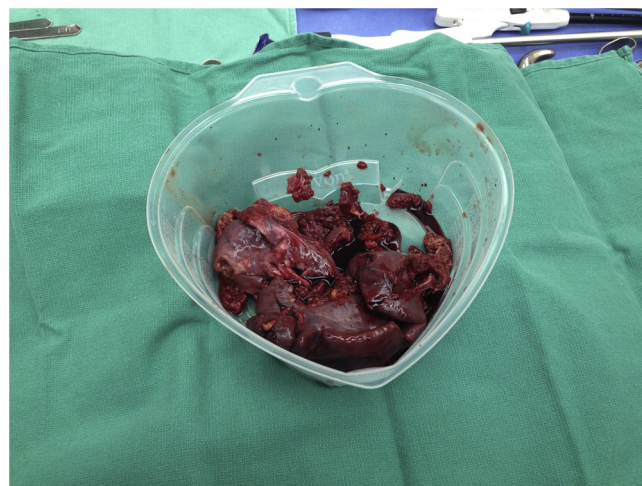


Fig. 3. Morcellated spleen after laparoscopic splenectomy.

patient delivered a healthy child at term. Final pathology demonstrated a benign epidermoid splenic cyst.

3. Discussion

Primary splenic cysts are classified as parasitic, congenital or neoplastic, while secondary cysts (pseudocysts) are usually post-traumatic in origin. Primary splenic cysts represent 30–40% of cysts encountered and are more common among children and young adults.¹¹ Parasitic (hydatid) cysts are commonly caused by the parasite *Echinococcus granulosus* and rupture of the cyst may result in anaphylactic shock.¹² Congenital cysts are further classified depending on their tissue of origin: epidermoid, dermoid or endodermoid. The epidermoid type accounts for 90% of primary nonparasitic cysts.¹³ Neoplastic cysts may involve all three germ layers or cystic vascular lesions such as hemangiomas or lymphangiomas.¹⁴ Although trauma accounts for the majority of secondary splenic cysts, other causes of secondary splenic infarction include sickle cell anemia and infections such as mononucleosis, tuberculosis or malaria.⁸ Splenic infarcts may also occur as a result of hormonal changes during pregnancy.¹⁴

Although more than 70% of patients with splenic cysts are asymptomatic, symptoms may include pain, nausea, vomiting, early satiety or weight loss.¹⁵ Large cysts may result in referred pain to the left shoulder and involvement of the left kidney may result in proteinuria or hypertension.^{9,13} Finally, circulatory changes may result in thrombocytopenia, and anemia.

Both serological studies and imaging assist in making the diagnosis. Ultrasonography (US), computed tomography (CT) and magnetic resonance imaging (MRI) are useful as they are able to distinguish between cystic and solid masses of the spleen, identify key morphology of the cyst (i.e. unilocular vs multilocular) as well as the composition of the cystic fluid, presence of calcifications and vascular anatomy. Splenic cysts are typically depicted by signal intensity that equals water on both T1 and T2 MRI images.¹⁶ Since rupture of a hydatid cyst may result in anaphylactic shock, thus it is important to obtain a serum IgG antibodies to rule out a parasitic etiology before surgery. Epidermoid splenic cysts can be ruled out with a normal carbohydrate antigen 19-9 (CA 19-9) level.¹³ Finally, percutaneous aspiration of a benign appearing cyst can help exclude the diagnosis of a neoplastic process, however there is a small risk of seeding the tract with malignant cells.⁸

Splenic cysts larger than 5 cm in diameter should be managed surgically as they are more likely to result in complications such as rupture or infection.^{9,11,17,18} Treatment options include

percutaneous drainage, fenestration, marsupialization and either partial or total splenectomy. The ideal intervention is minimally invasive, spleen preserving and results in the lowest recurrence rate.

Percutaneous drainage with supplementary alcohol instillation is safe, cost-effective with minimal recovery time, however the recurrence rate remains high.^{9,13} In a patient with a symptomatic large splenic cyst noted in the first trimester of pregnancy, Rotas et al., performed a percutaneous aspiration initially and followed the patient closely with biweekly sonographic evaluations until the second trimester when surgical intervention could be performed safely. Although the cystic fluid re-accumulated two weeks later and the patient recovered from a septic episode after noting a purulent aspiration, they were able to perform a successful laparoscopic fenestration with omentopexy in the second trimester.⁸ Similarly, Mahran et al. managed a large splenic cyst during pregnancy conservatively with analgesia, antibiotics and percutaneous aspiration. However, the patient required iron supplementation and blood transfusions for anemia and the cyst aspirate was found to be infected, requiring antibiotics. Moreover, after a normal vaginal delivery at 40 weeks, an ultrasound at 6 weeks demonstrated persistence of the cyst, which required re-aspiration.¹⁹

Whereas fenestration simply involves unroofing of the cystic wall, marsupialization involves separation of the entire cystic wall from the splenic parenchyma. It is believed that removing a large amount of the cyst wall will prevent recurrence, however this may result in more bleeding. Nevertheless, bleeding can often be managed with diathermy or topical agents.^{9,11,20} Both fenestration and marsupialization can be performed laparoscopically and is often recommended for superficial splenic cysts as it results in a shorter duration of surgery and no risk of recurrence.^{9,21}

Splenectomy can be performed either open or laparoscopically. Partial splenectomy has the advantage of conserving the regular immunologic function and is ideal if the cyst is located in the poles of the spleen.^{9,22} The operation requires great technical skill as well as a full evaluation of the splenic vasculature preoperatively.^{11,23} Total splenectomy is reserved for cases when the cyst location (posterior surface or in the hilum) or size would jeopardize the outcome of the procedure or if the pathology is unknown.²⁴ Laparoscopic technique is the preferred approach resulting in a decreased wound complications and postoperative hospitalization.^{25,26} Although the incidence overwhelming post-splenectomy infection (OPSI) is low (0.27% to 0.66%), the mortality remains high (58%).^{27,28} Thus it is imperative that patients are vaccinated for *S. pneumonia*, *N. meningitidis* and *H. influenza* preoperatively.

When comparing all possible options for management of splenic cysts in a pregnant patient, laparoscopic splenectomy offers a single intervention that is relatively safe and is the least likely to recur, since all of the cyst and splenic tissue is removed. Past experiences describe a need for repeat interventions as well as blood transfusions when percutaneous drainage or fenestration was performed. Finally, laparotomy and splenectomy provides an equally low recurrence rate when compared to laparoscopic splenectomy, however, the recovery is longer and the risk of wound complication is higher.

4. Conclusion

Splenic cysts are extremely rare in pregnancy but may result in pain, nausea, early satiety and weight loss. Prior to operative management, diagnostic studies must differentiate between parasitic (hydatid) and non-parasitic cysts as well as delineate its location in relation to the hilum and surrounding organs. Large symptomatic splenic cysts may be treated surgically and a laparoscopic approach during the second trimester is ideal.

Conflict of interest

None.

Funding

None.

Ethical approval

Written informed consent was obtained from the patient for publication of this case report and accompanying images. A copy of the written consent is available for review by the Editor-in-Chief of this journal on request.

Author contributions

Varban O is the first author and faculty surgeon in charge of the patient's care. Primary surgeon who performed the operation and provided follow up care. Obtained consent, diagnostic and intraoperative imaging. Performed literature review.

Key learning point

- Large symptomatic splenic cysts can be managed via laparoscopic splenectomy during the second trimester of pregnancy.

References

- Balzan SM, Riedner CE, Santos LM, Pazzinatto MC, Fontes PR. Posttraumatic splenic cysts and partial splenectomy: report of a case. *Surg Today* 2001;**31**:262–5.
- Dabrowski W, Luterek K, Szczepanik A, Niedzwiedzka B, Wielgos M. Management of a large splenic cyst in pregnancy – a case report. *Ginekol Pol* 2012;**83**:862–4.
- Can D, Oztekin O, Oztekin O, Tinar S, Sancı M. Hepatic and splenic hydatid cyst during pregnancy: a case report. *Arch Gynecol Obstet* 2003;**268**:239–40.
- Ceglowska A. The course of a multipara's pregnancy, labour and puerperium complicated by spleen tumor. *Ginekol Pol* 2003;**74**:629–32.
- Elit L, Aylward B. Splenic cyst carcinoma presenting in pregnancy. *Am J Hematol* 1989;**32**:57–60.
- Hamm JA, Delomenie M, Derniaux E, Durier M, Look M, Abboud P, et al. Splenic cyst during pregnancy: a rare disease with difficult management. *J Gynecol Obstet Biol Reprod (Paris)* 2013;**42**:191–4.
- Mendez-Arzac R, Sanjuan A, Rebollo G, Marquez JC, Recinos EG, Cue A, et al. Splenic hydatid cyst. Case report of a pregnant woman. *Rev Gastroenterol Mex* 2002;**67**:195–8.
- Rotas M, Ossowski R, Lutchman G, Levgur M. Pregnancy complicated with a giant splenic cyst: a case report and review of the literature. *Arch Gynecol Obstet* 2007;**275**:301–5.
- Smith ST, Scott DJ, Burdick JS, Rege RV, Jones DB. Laparoscopic marsupialization and hemisplenectomy for splenic cysts. *J Laparoendosc Adv Surg Tech A* 2001;**11**:243–9.
- Buchsbaum HJ. Splenic rupture in pregnancy. Report of a case and review of the literature. *Obstet Gynecol Surv* 1967;**22**:381–95.
- Hansen MB, Moller AC. Splenic cysts. *Surg Laparosc Endosc Percutan Tech* 2004;**14**:316–22.
- Safioleas M, Misiakos E, Manti C. Surgical treatment for splenic hydatidosis. *World J Surg* 1997;**21**:374–7, discussion 378.
- Cowles RA, Yahanda AM. Epidermoid cyst of the spleen. *Am J Surg* 2000;**180**:227.
- Triedman LJ, Raphael SL. Nonparasitic cysts of the spleen: case report and review of the literature. Rare disorder, here associated with pregnancy, is cured by splenectomy. *R I Med J* 1967;**50**:265–7.
- Qureshi MA, Hafner CD. Clinical manifestations of splenic cysts: study of 75 cases. *Am Surg* 1965;**31**:605–8.
- Moller AC, Jensen R, Hansen MB. Splenic cysts – pathogenesis, diagnostics and treatment. *Ugeskr Laeger* 2003;**165**:1039–40.
- Boesby S. Spontaneous rupture of benign nonparasitic cyst of the spleen. *Ugeskr Laeger* 1972;**134**:2596–7.
- Gianom D, Wildisen A, Hotz T, Goti F, Decurtins M. Open and laparoscopic treatment of nonparasitic splenic cysts. *Dig Surg* 2003;**20**:74–8.

19. Mahran MA, Bodley R, Farouk M, Ashworth F. Conservative management of gigantic splenic cyst during pregnancy; a differential diagnosis for chest pain caused by the forgotten organ. *Gynecol Surg* 2010;**7**:49–51.
20. Macheras A, Misiakos EP, Liakakos T, Mpistarakis D, Fotiadis C, Karatzas G. Non-parasitic splenic cysts: a report of three cases. *World J Gastroenterol* 2005;**11**:6884–7.
21. Millar JS. Partial excision and drainage of post-traumatic splenic cysts. *Br J Surg* 1982;**69**:477–8.
22. Kaiwa Y, Kurokawa Y, Namiki K, Matsumoto H, Satomi S. Laparoscopic partial splenectomies for true splenic cysts. A report of two cases. *Surg Endosc* 2000;**14**:865.
23. Fan H, Zhang D, Zhao X, Pan F, Jin ZK. Laparoscopic partial splenectomy for large splenic epidermoid cyst. *Chin Med J (Engl)* 2011;**124**:1751–3.
24. Karfis EA, Roustanis E, Tsimoyiannis EC. Surgical management of nonparasitic splenic cysts. *JSL* 2009;**13**:207–12.
25. Keckler SJ, Peter SD, Tsao K, Holcomb GW. Laparoscopic excision of splenic cysts: a comparison to the open approach. *Eur J Pediatr Surg* 2010;**20**:287–9.
26. Marte G, Scuderi V, Rocca A, Surfaro G, Migliaccio C, Ceriello A. Laparoscopic splenectomy: a single center experience. Unusual cases and expanded inclusion criteria for laparoscopic approach. *Updates Surg* 2013;**65**(2):115–9.
27. Di Cataldo A, Puleo S, Li Destri G, Racalbutto A, Trombatore G, Latteri F, et al. Splenic trauma and overwhelming postsplenectomy infection. *Br J Surg* 1987;**74**:343–5.
28. Singer DB. Postsplenectomy sepsis. *Perspect Pediatr Pathol* 1973;**1**:285–311.

Open Access

This article is published Open Access at sciedirect.com. It is distributed under the [IJSCR Supplemental terms and conditions](#), which permits unrestricted non commercial use, distribution, and reproduction in any medium, provided the original authors and source are credited.