

Clinical Characteristics and Management of Intrathoracic Bronchogenic Cysts: A Single Center Experience

Deok Heon Lee, M.D.*, Chang-Kwon Park, M.D.*, Dong-Yoon Kum, M.D.*,
Jae-Bum Kim, M.D.*, Ilseon Hwang, M.D.*

Background: The aim of this study is to investigate the clinical characteristics and management of intrathoracic bronchogenic cysts. **Materials and Methods:** Twenty-four (n=24) patients with intrathoracic bronchogenic cysts were treated surgically between August 1990 and December 2009 at our institution. Patients were divided into two groups by bronchogenic cyst location: mediastinal or intrapulmonary. Symptoms at diagnosis, radiologic findings, locations, surgical methods, pathological findings, and surgical outcomes were investigated retrospectively from consecutive patient medical records. **Results:** There were 12 females (50.0%). The mean age was 26.8 (range, 5 to 64) years. The mean follow-up period was 27.3 (range, 1 to 121) months. There were 15 (62.5%) mediastinal and 9 (37.5%) intrapulmonary bronchogenic cysts. Symptoms occurred in 8 patients with mediastinal bronchogenic cysts (53.3%) and 5 patients with intrapulmonary bronchogenic cysts (55.6%) (p=1.000). On computed tomography (CT), 7 patients (46.7%) showed homogenous solid masses in mediastinal bronchogenic cysts and five (55.6%) patients exhibited heterogeneous cystic masses with air-fluid levels in intrapulmonary bronchogenic cystic masses. Open thoracotomy was performed in 17 (70.8%) patients, and video-assisted thoracic surgery was performed in 7 (29.2%) patients. On pathological findings, there were 16 (66.7%) complicated cysts, and in 13 symptomatic patients, 11 (84.6%) patients had complicated cysts. There was no operative death in this study. During the follow-up period, no recurrence was detected. **Conclusion:** Intrathoracic bronchogenic cysts have a wide variety of clinical characteristics and radiologic findings. Even though some patients do not experience symptoms and signs caused by bronchogenic cysts, serious symptoms and complications may develop with the passage of time.

Key words: 1. Bronchogenic cyst
2. Mediastinum
3. Lung

INTRODUCTION

A bronchogenic cyst is a benign congenital aberration of bronchopulmonary foregut malformations that arise during the development of the embryonic foregut. It can be found in the mediastinum or pulmonary parenchyma and rarely in extra-thoracic locations [1]. Bronchogenic cysts of the mediastinum

represent about 18% of all primary mediastinal tumors [2]. Of all bronchogenic cysts, 15~23% are intrapulmonary bronchogenic cysts [3]. The clinical and radiological presentations of bronchogenic cysts vary from incidental radiologic finding without symptoms, to large mass-like findings associated with intense symptoms. Once the condition is diagnosed, complete excision is the standard management. In this retrospective

*Department of Thoracic and Cardiovascular Surgery, College of Medicine, Keimyung University

Received: March 10, 2011, Revised: April 8, 2011, Accepted: June 1, 2011

Corresponding author: Chang-Kwon Park, Department of Thoracic and Cardiovascular Surgery, College of Medicine, Keimyung University, 194, Dongsan-dong, Jung-gu, Daegu 700-712, Korea
(Tel) 82-53-250-7342 (Fax) 82-53-250-7307 (E-mail) ckpark80@dsmc.or.kr

© The Korean Society for Thoracic and Cardiovascular Surgery. 2011. All right reserved.

© This is an open access article distributed under the terms of the Creative Commons Attribution Non-Commercial License (<http://creativecommons.org/licenses/by-nc/3.0>) which permits unrestricted non-commercial use, distribution, and reproduction in any medium, provided the original work is properly cited.

study, we report our experience of the clinical characteristics and management of intrathoracic bronchogenic cysts.

MATERIALS AND METHODS

Between August 1990 and December 2009, 30 patients with bronchogenic cysts underwent surgery at our hospital. Thirty excised cysts were pathologically confirmed by ciliated columnar cuboidal epithelia containing cartilage or bronchial glands on the cyst surface. After excluding 6 extrathoracic bronchogenic cysts during the study period, 24 (80.0%) patients with intrathoracic bronchogenic cysts were enrolled in this study. There were 12 females (50.0%) and 12 males (50.0%). The mean age was 26.3 (range, 5 to 64) years. The mean follow-up period was 27.3 (range, 1 to 121) months. The symptoms at diagnosis, radiologic findings, locations, surgical methods, pathological findings, and surgical outcomes were evaluated retrospectively from consecutive patient records. Statistical evaluation was performed by using PASW 18.0 for Windows. Mann-Whitney U or Fisher's exact test were used for comparison between groups. Differences were considered statistically significant if p-values were less than 0.05 ($p < 0.05$). The institutional review board of the University of Keimyung, the Republic of Korea, approved this study.

RESULTS

1) Location of the lesions

The mediastinum was the most common site. There were 15 (62.5%) mediastinal and 9 (37.5%) intrapulmonary bronchogenic cysts. Six (40.0%) mediastinal bronchogenic cysts were located in the subcarinal area, four in the posterior mediastinum, three in the perihilar area, one in the anterior mediastinum, and one in the right diaphragm. One intrapulmonary bronchogenic cysts was located in the right upper lobe, three in the right middle lobe, three in the right lower lobe, one in the left upper lobe and one in the left lower lobe.

2) Patient's characteristics

Among patients with mediastinal bronchogenic cysts, there

were 7 females (46.7%) and 8 males (53.3%), with a mean age of 26.4 (range, 5 to 56) years. Five females (55.6%) and 4 males (44.4%) were diagnosed with intrapulmonary bronchogenic cysts, with a mean age of 26.3 (range, 7 to 64) years. There were no significant differences in sex and age between the two groups ($p=1.000$, $p=0.929$).

3) Clinical presentations

Symptoms were present in 13 patients (54.2%), of whom 10 patients (76.9%) experienced coughing and it was the most common complaint. Other symptoms included chest pain in 6 patients (46.1%), fever in 3 (23.0%), and sputum expectoration in 3 (23.0%). Eight patients (61.5%) had more than one symptom. These symptoms occurred in 8 patients with mediastinal bronchogenic cysts (53.3%) and 5 patients with intrapulmonary bronchogenic cysts (55.6%) ($p=1.000$). The mean age of symptomatic and asymptomatic patients was 24.6 (range, 5 to 56) years and 28.4 (range, 13 to 64) years ($p=0.369$), respectively.

4) Radiologic findings

Standard chest radiographs were reviewed in all patients. Among patients diagnosed with mediastinal bronchogenic cysts, 5 (33.3%) had homogenous mass lesions, 1 (6.7%) had cystic mass lesions containing air-fluid levels and 1 (6.7%) experienced pleural effusion. Lesions could not be identified on chest radiographs in 8 patients (53.3%). Among patients diagnosed with intrapulmonary bronchogenic cysts, 4 patients (44.4%) had cysts with heterogeneous air-fluid levels, 4 (44.4%) experienced homogenous mass lesions and 1 (11.1%) experienced pneumonic consolidation. Chest computed tomography (CT) was performed in 22 patients. Among patients with mediastinal bronchogenic cysts, 7 (46.7%) had homogenous solid mass, 5 (33.3%) had homogenous cystic mass and 1 (6.7%) had heterogeneous cystic mass containing air-fluid levels. Among patients with intrapulmonary bronchogenic cysts, 5 (55.6%) showed heterogeneous cystic masses containing air-fluid levels, 2 (22.2%) showed homogenous solid masses and 2 (22.2%) showed homogenous cystic masses. The Hounsfield units varied from 15 to 1,060. The mean Hounsfield units, excluding one patient with 1,060 Hounsfield units, was 44.5.

Table 1. Postoperative results according to location and pathologic characteristics of bronchogenic cysts

	MBC	PBC	p-value	Simple cysts	Complicated cysts	p-value
Mean operating time (minute)	100	135	0.039*	98	121	0.195
Duration of drainage (day)	3.0	5.3	0.047	2.6	4.5	0.029*
Duration of hospital stay (day)	5.4	7.0	0.469	4.8	6.7	0.082
Complication	1	2	-	0	3	-

*=Statistically significant; MBC=Mediastinal bronchogenic cyst; PBC=Intrapulmonary bronchogenic cyst.

5) Preoperative diagnosis

Based on clinical investigations and radiologic appearances, preoperative diagnoses were made in our hospital. Twelve (50.0%) of 24 patients were diagnosed with bronchogenic cysts and 12 patients were diagnosed with other conditions. Three patients (12.5%) were misdiagnosed with neurogenic tumors, 2 (8.3%) with thymic cysts, 2 with pulmonary tuberculosis and 1 (4.2%) each with lung cancer, lung abscess, infected bullae, gynecological tumor, and congenital cystic adenomatoid malformation.

6) Operations

All except 1 patient underwent complete surgical excision. Open thoracotomy was performed in 17 (70.8%) patients (11 with mediastinal bronchogenic cysts, 6 with intrapulmonary bronchogenic cysts), and thoracoscopic surgery in 7 (29.2%) patients (4 with mediastinal bronchogenic cysts, 3 with intrapulmonary bronchogenic cysts). Complete cyst excision was performed in all patients with mediastinal bronchogenic cysts. Among patients with intrapulmonary bronchogenic cysts, 5 patients underwent lobectomy, 3 patients underwent wedge resection and 1 patient underwent partial excision and direct closure due to severe pericystic adhesion. Pericystic adhesions developed in 5 (33.3%) patients with mediastinal bronchogenic cysts, and 5 (55.6%) with intrapulmonary bronchogenic cysts ($p=0.403$). The mean operating time was 100 min in patients with mediastinal bronchogenic cysts, and 135 min in patients with intrapulmonary bronchogenic cysts ($p=0.039$). The mean duration of thoracic drainage and hospital stay were 3.0 days and 5.4 days, respectively, in patients with mediastinal bronchogenic cysts, and 5.3 days and 7.0 days, respectively, in patients with intrapulmonary bronchogenic cysts

($p=0.470$, $p=0.469$). Operating time was the only parameter that attained a statistically significant difference between the two patient groups (Table 1).

7) Pathologic findings

On histologic examination, the mean diameter of the mediastinal bronchogenic cysts was 5.40 cm (range 1~15 cm), and 4.83 cm (range 1~9 cm) for intrapulmonary bronchogenic cysts ($p=0.834$). Almost all cysts ($n=22$) were lined by ciliated columnar epithelia, but some cysts ($n=2$) were lined by a mixture of squamous and columnar epithelia. More than half of the cysts ($n=16$) consisted of ciliated pseudostratified columnar epithelia with inflammatory cell infiltration. There are many chronic and acute inflammatory cells associated with fibrosis, granulation tissue, and congestion around the cysts (Fig. 1). The others ($n=8$) consisted of ciliated pseudostratified columnar epithelia, but had few inflammatory cells and no granulation tissue (Fig. 2). We regarded a simple cyst as epithelial lining with little inflammatory cell infiltration, and a complicated cyst as cyst with extensive inflammation and granulation tissue, even if there was no definitive evidence of cystic infection by bacteriologic culture. Sixteen (66.7%) cysts were considered complicated cysts, and 8 (33.3%) were considered simple cysts. Eight (53.3%) mediastinal cysts and 8 (88.9%) intrapulmonary cysts were defined as complicated cysts ($p=0.178$). Eleven (84.6%) patients out of 13 symptomatic patients had complicated cysts ($p=0.082$). Complicated cysts were more commonly found in an intrapulmonary location and in symptomatic patients, but the difference was without statistical significance.

8) Surgical outcomes

The mean operating time was 98 min in patients with sim-

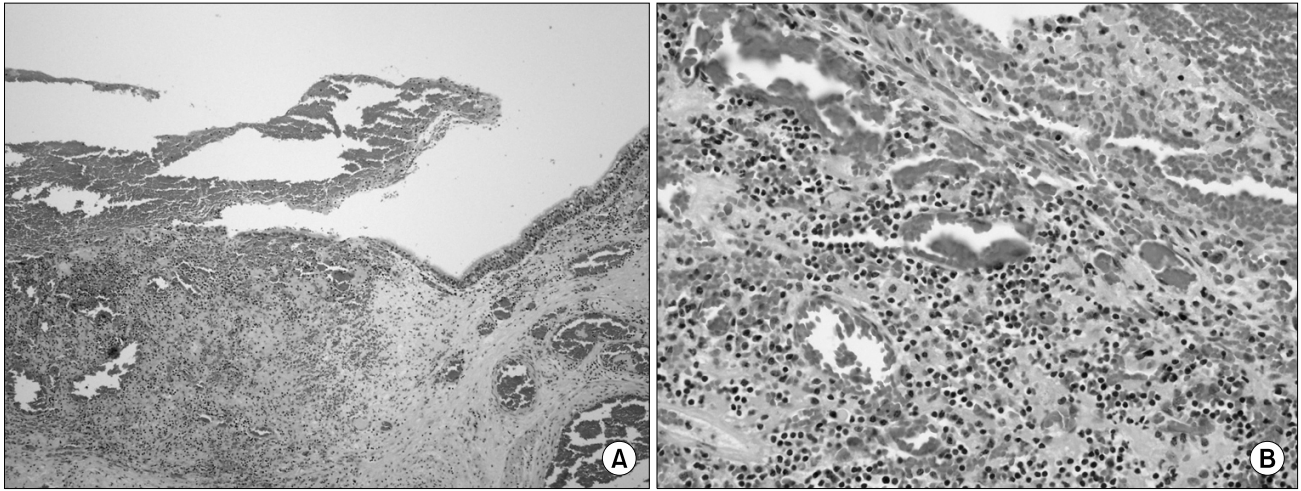


Fig. 1. A complicated cyst consists of pseudostratified columnar epithelial lining with many chronic inflammatory cells with fibrosis and congestion. (A) H&E, $\times 100$, (B) H&E, $\times 400$.

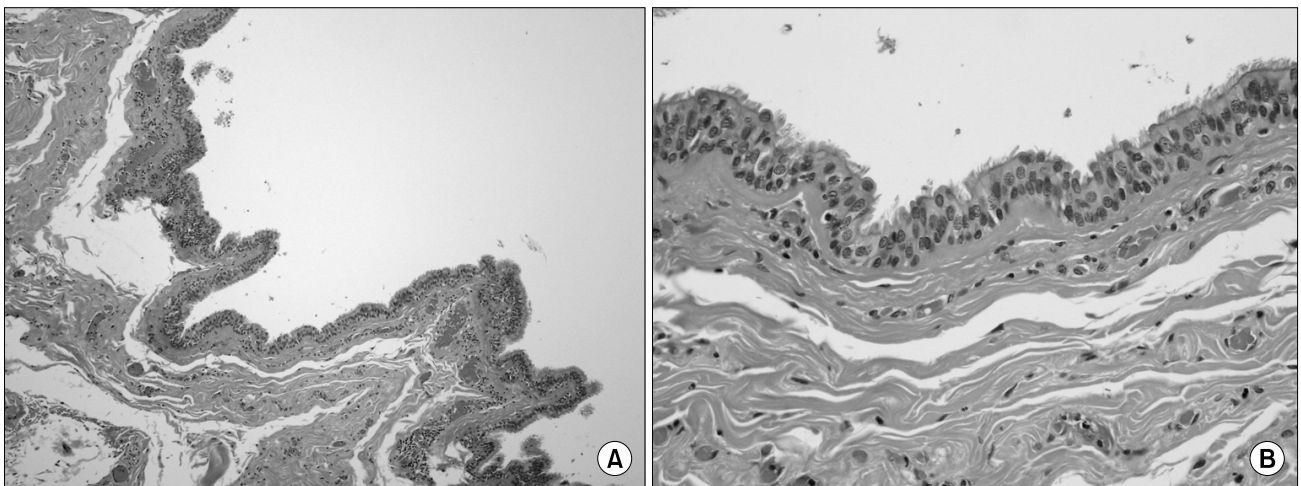


Fig. 2. A simple cyst consists of pseudostratified columnar epithelium with few inflammatory cells. (A) H&E, $\times 100$, (B) H&E, $\times 400$.

ple cysts and 121 min in patients with complicated cysts ($p=0.195$). The mean duration of thoracic drainage and hospital stay were 2.6 days and 4.8 days, respectively, in patients with simple cysts, and 4.5 days and 6.7 days, respectively, in patients with complicated cysts ($p=0.029$, $p=0.082$). The mean operating time, duration of thoracic drainage, and hospital stay were longer in patients with complicated cysts. However, the mean duration of thoracic drainage was the only parameter that demonstrated statistical difference between the two patient groups (Table 1). There was no operative death in this study. However, one patient with mediastinal bronchogenic

cysts and two with intrapulmonary bronchogenic cysts experienced postoperative complications (atrial fibrillation, pneumonia, and prolonged air leakage). All 3 patients who experienced postoperative complications had complicated cysts. They underwent uneventful recovery after undergoing appropriate management. No recurrence was detected during the follow up period.

DISCUSSION

Bronchogenic cysts are most commonly located in the me-

diastinum, and 15~20% of all bronchogenic cysts are intrapulmonary cysts [4]. In this study, bronchogenic cysts predominantly comprised mediastinal bronchogenic cysts (62.5%), and about 37.5% were intrapulmonary bronchogenic cysts. Symptoms are usually related to cyst infection or compression of the adjacent structures. Patients may remain asymptomatic until infection occurs, and symptoms include cough, dyspnea, and thoracic pain [5,6]. The incidence of infection differentiates mediastinal cysts from intrapulmonary cysts [7]. Intrapulmonary cysts were more often symptomatic than mediastinal cysts [8]. Sometimes, life-threatening complications, such as hemoptysis or respiratory distress, may occur [9,10]. In this study, 13 patients (54.2%) were symptomatic, and the most common symptom was cough, and symptoms in relation to location were not statistically meaningful.

Although there was no statistical significance in the present study, complicated cysts were more often found in intrapulmonary bronchogenic cysts by pathological examination. Among symptomatic patients, 84.6% were confirmed as having complicated cysts. In addition, mean operating time, mean duration of postoperative thoracic drainage, and hospital stay were longer in patients with complicated cysts than those with simple cysts, although only the mean duration of postoperative thoracic drainage was statistically significant. Kosar et al. reported that postoperative complications occur more frequently in patients with complicated bronchogenic cysts [4]. In our study, all 3 patients who developed postoperative complications were diagnosed with complicated bronchogenic cysts. Patel et al. reported a significant difference in postoperative complications between symptomatic patients and asymptomatic patients (27% vs. 14%) [11]. If we put these results together, the possibility of cyst infection may be high in patients with intrapulmonary bronchogenic cysts that are directly exposed to the environment. On this account, symptoms may occur more often in intrapulmonary bronchogenic cysts, with evolution of bronchogenic cysts into complicated cysts caused by frequent cystic inflammation. Also, repeated cystic inflammation can lead to pericystic adhesion or cystic fibrosis. In this instance, it is likely to prolong the operating time, the duration of postoperative thoracic drainage, and hospital stay.

Bronchogenic cysts show a wide range of clinical and ra-

diologic manifestations, which makes diagnosis difficult preoperatively. The differential diagnosis of bronchogenic cysts includes fungal ball, pulmonary tuberculosis, lung abscess, infected bullae, and lung cancer for intrapulmonary bronchogenic cysts, while mediastinal masses such as neurogenic tumor, thymic tumor, lymphoma, or congenital cystic disease are included in differential diagnosis for mediastinal bronchogenic cysts. The accuracy of preoperative diagnosis of bronchogenic cysts based on radiologic findings lies between 10% and 40% of cases [11,12]. Recently, McAdams et al. suggested that most bronchogenic cysts can be confidently diagnosed by non-enhanced CT, while contrast enhanced CT and magnetic resonance imaging (MRI) can be useful for differentiating bronchogenic cysts from mediastinal neoplasia [13]. Standard chest radiography and CT are the most valuable diagnostic studies. On CT, mediastinal cysts are usually described as round, well marginated with homogenous water or soft-tissue attenuation [13], and intrapulmonary cysts are usually described as thin-walled, of homogenous water density with air-fluid levels or air-filled cysts [3,14]. In this study, most mediastinal bronchogenic cysts (81.2%) showed homogenous mass density on CT imaging, and six intrapulmonary bronchogenic cysts (60%) showed a heterogeneous cystic mass containing air-fluid levels as described previously.

There is generally no controversy surrounding surgical treatment of symptomatic or complicated cysts. Complete excision remains crucial for mediastinal bronchogenic cysts [4,6,12,15,16], and also lobectomy is the best treatment for intrapulmonary bronchogenic cysts. As for peripheral small cysts, wedge resection is adequate [7]. When bronchogenic cysts are incompletely excised due to adhesion, partial excision with de-epithelization must be performed to prevent recurrence [4,17]. Incomplete resection may lead to local recurrence more than 10 years later [18]. Surgery remains controversial in asymptomatic patients [19]. However, if left untreated, bronchogenic cysts have the potential to cause complications and malignant transformation [20]. Recently, with the development of thoracoscopic surgery, many authors have reported favorable outcomes using thoracoscopy and have suggested thoracoscopic surgery should be considered a primary therapeutic option for bronchogenic cysts [2,4,15,16,21, 22]. Video-assisted thoracic surgery for the treatment of bron-

chogenic cysts has been performed at our hospital since 1998, and the surgical outcomes have been favorable.

CONCLUSION

In conclusion, intrathoracic bronchogenic cysts have a wide variety of clinical characteristics and radiologic appearances, and there are many problems for differential diagnosis in spite of the development of various diagnostic tools. Surgical excision followed by histopathological examination remains the only way to obtain a definitive diagnosis. Even though some patients do not experience symptoms and signs caused by bronchogenic cysts, serious symptoms and complications may develop with the passage of time.

REFERENCES

1. Shields TW. *General thoracic surgery*. 7th ed. Philadelphia, PA; London: Wolters Kluwer Health/Lippincott Williams & Wilkins. 2009.
2. Martinod E, Pons F, Azorin J, et al. *Thoracoscopic excision of mediastinal bronchogenic cysts: results in 20 cases*. *Ann Thorac Surg* 2000;69:1525-8.
3. Chang YC, Chang YL, Chen SY, et al. *Intrapulmonary bronchogenic cysts: computed tomography, clinical and histopathologic correlations*. *J Formos Med Assoc* 2007;106:8-15.
4. Kosar A, Tezel C, Orki A, Kiral H, Arman B. *Bronchogenic cysts of the lung: report of 29 cases*. *Heart Lung Circ* 2009;18:214-8.
5. Limaïem F, Ayadi-Kaddour A, Djilani H, Kilani T, El Mezni F. *Pulmonary and mediastinal bronchogenic cysts: a clinicopathologic study of 33 cases*. *Lung* 2008;186:55-61.
6. Liu HS, Li SQ, Cao ZL, Zhang ZY, Ren H. *Clinical features and treatment of bronchogenic cyst in adults*. *Chin Med Sci J* 2009;24:60-3.
7. Ribet ME, Copin MC, Gosselin B. *Bronchogenic cysts of the mediastinum*. *J Thorac Cardiovasc Surg* 1995;109:1003-10.
8. Kanemitsu Y, Nakayama H, Asamura H, Kondo H, Tsuchiya R, Naruke T. *Clinical features and management of bronchogenic cysts: report of 17 cases*. *Surg Today* 1999;29:1201-5.
9. Lardinois D, Gugger M, Ris HB. *Bronchogenic cyst of the left lower lobe associated with severe hemoptysis*. *Eur J Cardiothorac Surg* 1999;16:382-3.
10. Hajjar W, El-Madany Y, Ashour M, Al-Kattan K. *Life threatening complications caused by bronchogenic and oesophageal duplication cysts in a child*. *J Cardiovasc Surg (Torino)* 2003;44:135-7.
11. Patel SR, Meeker DP, Biscotti CV, Kirby TJ, Rice TW. *Presentation and management of bronchogenic cysts in the adult*. *Chest* 1994;106:79-85.
12. Suen HC, Mathisen DJ, Grillo HC, et al. *Surgical management and radiological characteristics of bronchogenic cysts*. *Ann Thorac Surg* 1993;55:476-81.
13. McAdams HP, Kirejczyk WM, Rosado-de-Christenson ML, Matsumoto S. *Bronchogenic cyst: imaging features with clinical and histopathologic correlation*. *Radiology* 2000;217:441-6.
14. Yoon YC, Lee KS, Kim TS, Kim J, Shim YM, Han J. *Intrapulmonary bronchogenic cyst: CT and pathologic findings in five adult patients*. *AJR Am J Roentgenol* 2002;179:167-70.
15. Weber T, Roth TC, Beshay M, Herrmann P, Stein R, Schmid RA. *Video-assisted thoracoscopic surgery of mediastinal bronchogenic cysts in adults: a single-center experience*. *Ann Thorac Surg* 2004;78:987-91.
16. De Giacomo T, Diso D, Anile M, et al. *Thoracoscopic resection of mediastinal bronchogenic cysts in adults*. *Eur J Cardiothorac Surg* 2009;36:357-9.
17. Ribet ME, Copin MC, Gosselin BH. *Bronchogenic cysts of the lung*. *Ann Thorac Surg* 1996;61:1636-40.
18. Hasegawa T, Murayama F, Endo S, Sohara Y. *Recurrent bronchogenic cyst 15 years after incomplete excision*. *Interact Cardiovasc Thorac Surg* 2003;2:685-7.
19. Bolton JW, Shahian DM. *Asymptomatic bronchogenic cysts: what is the best management?* *Ann Thorac Surg* 1992;53:1134-7.
20. Endo C, Imai T, Nakagawa H, Ebina A, Kaimori M. *Bronchioloalveolar carcinoma arising in a bronchogenic cyst*. *Ann Thorac Surg* 2000;69:933-5.
21. Tölg C, Abelin K, Laudenbach V, et al. *Open vs thoracoscopic surgical management of bronchogenic cysts*. *Surg Endosc* 2005;19:77-80.
22. Jiménez Merchán R, Congregado Loscertales M, Gallardo Valera G, Ayarra Jarne J, Loscertales J. *Resection of 8 mediastinal bronchogenic cysts by video-assisted thoracoscopy*. *Arch Bronconeumol* 2008;44:220-3.