

Received: 2019.08.07

Accepted: 2019.12.14

Available online: 2020.01.24

Published: 2020.03.02

# A Multi-Modality Treatment of Retroperitoneal De-Differentiated Liposarcoma

## Authors' Contribution:

Study Design A  
Data Collection B  
Statistical Analysis C  
Data Interpretation D  
Manuscript Preparation E  
Literature Search F  
Funds Collection G

AE 1 **Joel Horowitz**  
 ADE 2 **Mayank Singhal**  
 ADE 2 **Dana Marrero**  
 ABCDEFG 2 **Fuad Bashjawish**  
 ABCDE 3 **Dezarae Leto**  
 ACE 3 **Maryselle Winters**  
 ABE 4 **Julian Jeberaeel**

1 Department of Oncological Surgery, Cape Fear Valley Hospital, Fayetteville, NC, U.S.A.  
 2 Department of Internal Medicine, Cape Fear Valley Hospital, Fayetteville, NC, U.S.A.  
 3 Department of General Surgery, Cape Fear Valley Hospital, Fayetteville, NC, U.S.A.  
 4 Campbell School of Osteopathic Medicine, Cape Fear Valley Hospital, Fayetteville, NC, U.S.A.

This case was presented at many regional conferences in North Carolina, the 2019 National ACP Conference, as well as the 2019 International Radiology and Novel Cancer Therapies Conference in Canada

**Corresponding Author:** Fuad Bashjawish, e-mail: [drfbash@gmail.com](mailto:drfbash@gmail.com)

**Conflict of interest:** None declared

**Patient:** Male, 73-year-old  
**Final Diagnosis:** Retroperitoneal dedifferentiated liposarcoma  
**Symptoms:** Abdominal pain  
**Medication:** —  
**Clinical Procedure:** Exploratory laparotomy  
**Specialty:** Oncology

**Objective:** Rare disease

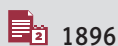
**Background:** Retroperitoneal sarcomas are rare tumors, only affecting 2 to 5 people per million population and accounting for 0.1% of all malignancies. Liposarcoma is the most common of all retroperitoneal sarcomas, responsible for approximately 20% of all sarcomas in adults. The most important prognostic factors are tumor grade, the presence of positive margins, tumor integrity, and degree of resection.

**Case Report:** Our patient was a 73-year-old man with abdominal pain whose CT scan of the abdomen and pelvis demonstrated a 15×15 cm heterogeneous, left-sided intra-abdominal mass. He underwent resection of the retroperitoneal tumor, left colectomy, and left nephrectomy. Final pathology demonstrated a high-grade, de-differentiated liposarcoma with a rhabdosarcomatous component. The postoperative course was complicated by a small intra-abdominal abscess and abdominal dehiscence. A CT scan after surgery showed a residual tumor of the retroperitoneal posterior margin. Re-exploration to resect the residual tumor and repair the fascial dehiscence were performed. The patient underwent an initial chemotherapy regimen with doxorubicin, then moved to targeted therapy with Palbociclib, and is now on chemotherapy using Eribulin.

**Conclusions:** Achieving complete resection and the grade of the tumor at diagnosis are the 2 most important prognostic factors for patient survival in retroperitoneal liposarcoma, as survival rates are inversely proportional to the grade of the tumor. Even with the best resection attempts, there is always a risk of residual tumor cells within the tumor bed, which contribute to recurrence and need for additional surgical interventions. It is important to approach this disease process with a multidisciplinary team that includes surgical, medical, and radiation oncology to ensure the best survival outcomes. Retroperitoneal sarcoma recurrence and survival are directly related to the ability to achieve negative margins of resection, as well as the grade and size of the primary tumor. Adjuvant therapies that include radiation and immunotherapy may be effective in treating recurrent disease.

**MeSH Keywords:** Colonic Neoplasms • Liposarcoma • Retroperitoneal Neoplasms

**Full-text PDF:** <https://www.amjcaserep.com/abstract/index/idArt/919245>



1896



—



7



23



## Background

Retroperitoneal sarcomas are extremely rare tumors, only affecting 2 to 5 per million people and accounting for 0.1% of all malignancies [1]. Liposarcoma is the most common of all retroperitoneal sarcomas, responsible for approximately 20% of all sarcomas in adults [2]. Even with successful tumor resection, most patients must undergo additional surgery due to the high infiltrative tendency of high-grade tumors [3]. Chemotherapy and radiation are also mainstays of treatment. The chemotherapy drug of choice has been doxorubicin. However, a recent paper on a phase II clinical trial with Ibrance (Palbociclib) showed that it leads to favorable progression-free survival and occasional tumor response for well-differentiated and de-differentiated liposarcomas [4]. In addition, another recent paper has shown that Halaven (Eribulin) can improve survival time of patients with advanced-stage liposarcomas [5].

## Case Report

Our patient was a 73-year-old man who presented to the emergency room in July 2018 for further evaluation of an abdominal mass recently discovered upon workup prompted by the Veterans Association healthcare network. Pertinent history included previous employment at a nuclear powerplant where he had unintentionally inhaled radioactive materials due to a problem with his oxygen mask. He underwent a CT scan of the abdomen and pelvis, which revealed a 15×15 cm heterogeneous left-sided intra-abdominal mass extending from the inguinal region to the level of the kidneys (Figures 1, 2). Gastroenterology was consulted and the patient underwent a colonoscopy, which showed no evidence of invasion into the lumen of the colon, but a large retroperitoneal mass was found upon examination. The patient was taken to the operating room and underwent exploratory laparotomy, radical resection of a retroperitoneal tumor (Figures 3, 4), left colectomy, and left nephrectomy because the mass was found to be adherent to the mid-portion of the left ureter. Of note, the tumor involved the anterior fascia of the iliopsoas and also involved the testicular vasculature. The patient tolerated the procedure well and was admitted to the Intensive Care Unit for monitoring. Intraoperative specimens were sent to a tertiary facility for review, with a final diagnosis of de-differentiated liposarcoma, high-grade, measuring 16 cm in greatest diameter, and the margins positive. Interphase FISH analysis revealed that 91% of the cells in the sample had a gain-of-function mutation in the MDM2 gene (primer signal), which is often seen in liposarcomas that are either well-differentiated or de-differentiated [6] (Histology slides Figure 5A, 5B). The ratio of MDM2 signal to CEP12 signal was >3 in 85% of the cells analyzed (a value >10% indicates amplification.) Two weeks later, the patient was readmitted to the hospital after suffering surgical wound dehiscence which

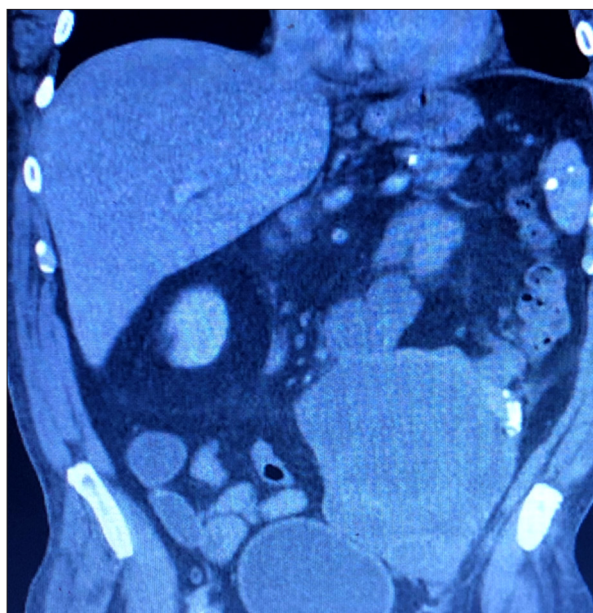


Figure 1. CT Abd-pelvis with and without contrast. Coronal View showing a 15×15 cm heterogeneous mass.

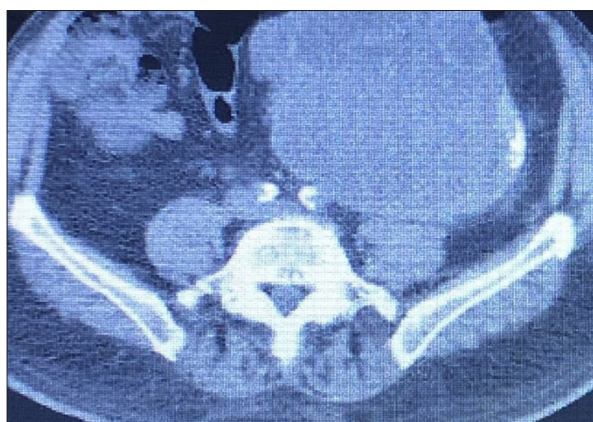

Figure 2. CT Abd-pelvis with and without contrast. Axial view showing a 15×15 cm heterogeneous mass.

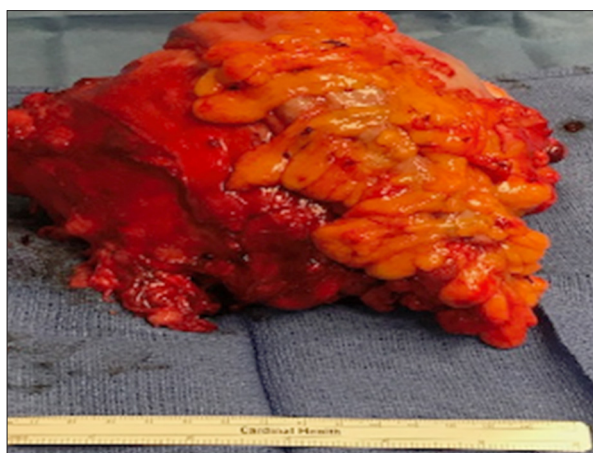
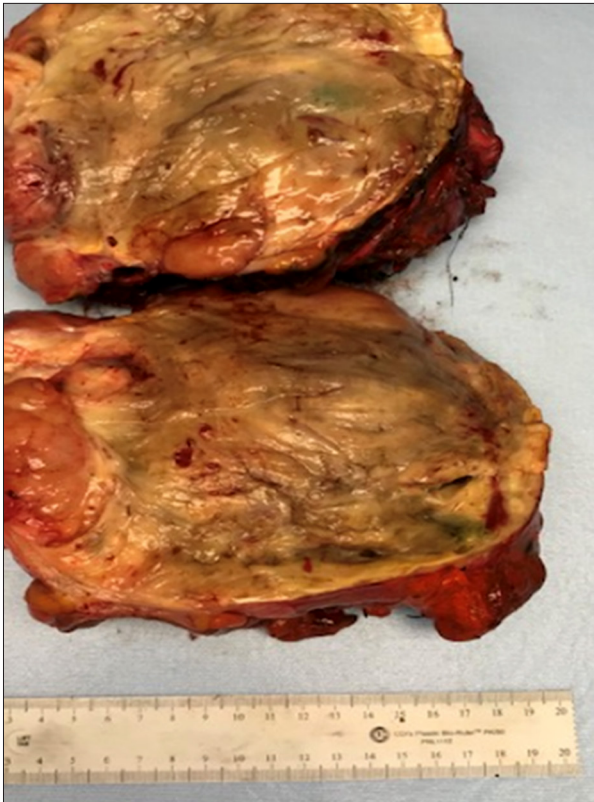

Figure 3. Gross retroperitoneal tumor in the operating room.



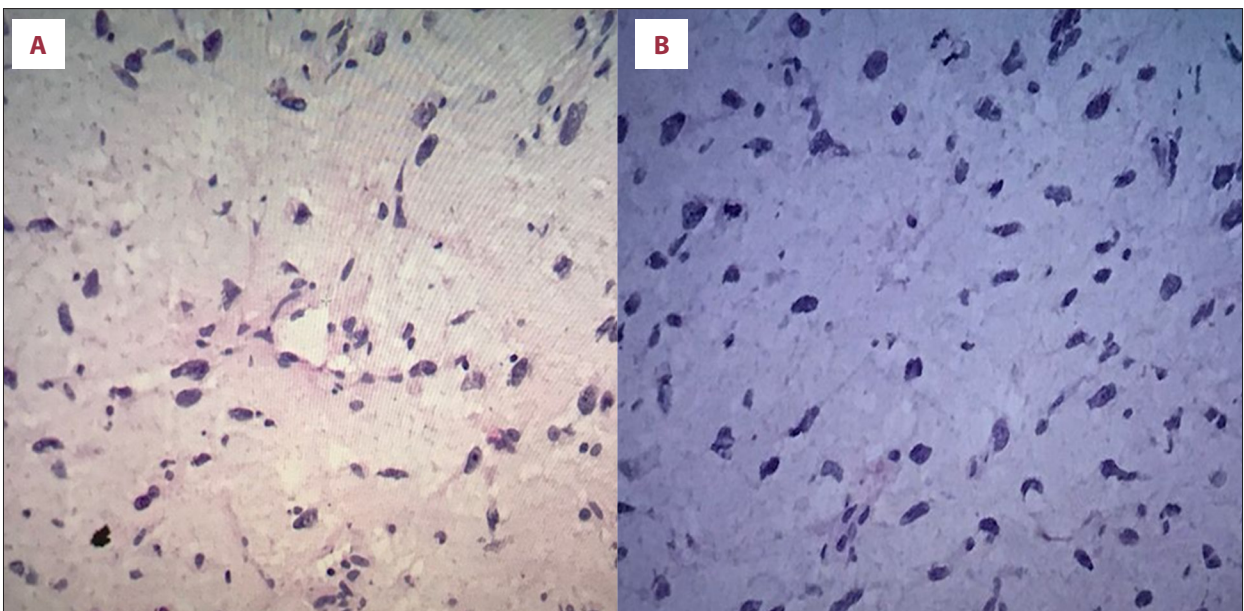
**Figure 4.** Transected retroperitoneal tumor, classification pT4NX (T4: cancer has distant spread to tissues, NX: cancer in nearby lymph nodes cannot be measured).

had caused a sudden flow of serosanguinous fluid from the operative site. Upon opening the abdomen, a pelvic abscess was noted and subsequently drained, along with further resection

of the retroperitoneal sarcoma. Additionally, the patient underwent resection of the transverse colon and proximal rectum, small bowel resection with primary anastomosis, and transverse colon colostomy with Hartmann's pouch. The surgical pathology (Figure 4) was concordant with previous findings. Postoperatively, the patient recovered well and spent nearly a month in rehabilitation. Despite 2 debulking surgeries, his re-staging imaging studies noted a residual soft-tissue tumor in the left retroperitoneum. He subsequently underwent chemotherapy with 4 cycles of doxorubicin. After completing this regimen, re-evaluation CT scans showed disease progression. The patient was switched to Ibrance (Palbociclib), a CDK 4/6 (cyclin-dependent kinase) inhibitor, which, as targeted monotherapy, has been shown to improve progression-free survival [4], which is the length of time that the patient lives with the disease but does not worsen.

## Discussion

Our surgical case highlights a rare and insidious form of soft-tissue sarcoma that slowly forms in the retroperitoneum. Our patient's history of radiation exposure is the most likely cause of his sarcoma, and a review of the literature shows that, while they are rare occurrences, radiation-induced sarcomas have a high mortality rate [7]. Only about 12–15% of these soft-tissue tumors develop in the retroperitoneum, with liposarcomas representing about 70% of such cases [8]. This makes retroperitoneal liposarcomas extremely rare tumors, accounting for only 0.1% of all malignancies [1]. The pathological subtypes are further divided by a WHO classification scheme into well-differentiated (WDL), de-differentiated (DDL), myxoid, and



**Figure 5.** (A, B) Histological image of retroperitoneal tumor, showing weak S-100 and strong CD56 positivity.

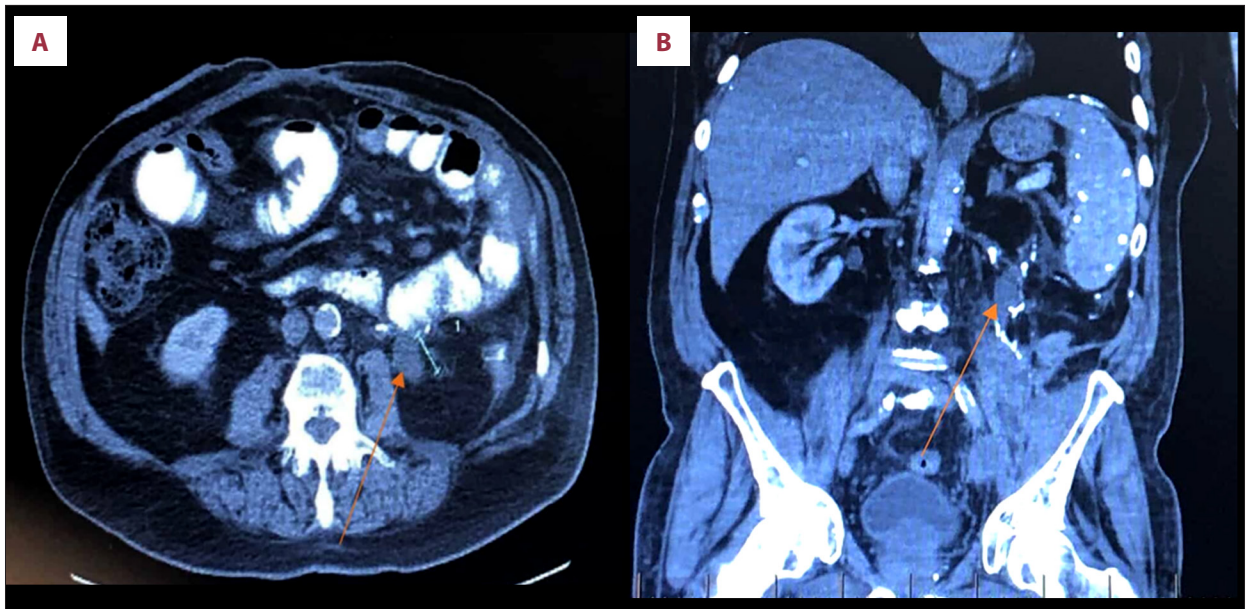
pleomorphic [8]. While the myxoid/round cell and pleomorphic liposarcomas are usually found in the extremities, well-differentiated and de-differentiated liposarcomas are usually found in the retroperitoneum. Due to the frequent absence of presenting symptoms in the retroperitoneal space, liposarcomas can reach a large size by the time of diagnosis and can present with compressed adjacent organs, as was the situation of our patient, who arrived with a rigid abdomen that had been worsening over a few months. Subsequent colonoscopy and CT imaging revealed an occult tumor that was thought to be intraperitoneal, only to be uncovered in the retroperitoneal space in the operating room. Our patient needed to have repeat exploratory laparotomy due to his fascial dehiscence and to subsequently remove his residual tumor burden. This is in line with the surgical literature, in which liposarcomas are noted to have a 3-fold higher risk of local recurrence compared with other histologies [9] and to recur more often as the de-differentiated subtype compared to the well-differentiated [10]. Specifically, Park et al. noted that local recurrence occurs with 80% of de-differentiated tumors within 5 years vs. 50% of well-differentiated tumors [1,10]. Being able to completely resect the retroperitoneal liposarcoma remains the most important predictor of local recurrence and overall survival [9,11,12], yet this is often difficult to achieve given intraoperative bleeding that reseeds the operative area. This likely occurred in our patient and required him to undergo postoperative chemotherapy.

Regarding the surgical treatment of retroperitoneal liposarcomas, multiple reports confirm that gross tumor resection is the most effective treatment modality and prognostic factor in these patients [2,13–16]. A paper by Zheng et al. recommends that surgeons should perform a more extended resection to include retroperitoneal fat and tumor-adjacent organs because there is no pre- or peri-operative technique currently available to assess nearby parenchymal infiltration [3].

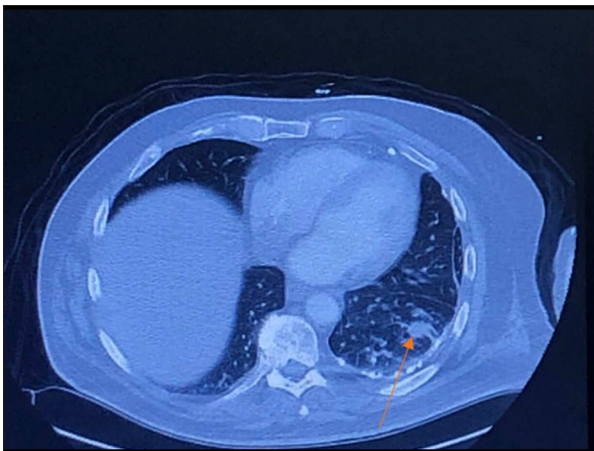
A possible noteworthy exception is suggested in a paper by Park et al., who wrote that tumors with “local recurrence growth rates greater than 0.9 cm/month do not benefit from an aggressive surgical approach” and hence may benefit more from medical therapy with novel systemic agents [1]. In addition, as seen in our patient, reoperation is the only effective treatment for recurrent abdominal liposarcomas [10,17]. Patients who undergo gross tumor resection tend to have a longer postoperative survival than those who undergo partial or palliative resection performed to mitigate intolerable symptoms [10]. After the initial operation, the most commonly reported complication is either an anastomotic leak or infection [10]. Our patient’s postoperative course was complicated by a pelvic abscess which required drainage. The most commonly resected organ alongside a retroperitoneal liposarcoma is the kidney [16] followed by the small bowel [10]. Similarly, our patient had a

left nephrectomy and subsequent small bowel resection when his residual tumor was removed. The nephrectomy was performed because the initial mass was found to be grossly adherent to the mid-portion of the left ureter. This is in line with the recommendation by Singer et al. noting that “nephrectomy should only be performed if required to accomplish a complete gross resection.” [9] Subsequent treatment modalities often involve using chemotherapy with possible use of radiation to prevent the spread of malignancy. A review of the literature indicates that pre-operative or peri-operative radiotherapy shows some usefulness in terms of local control and safety [18,19]. In addition, a case report by Carboni et al. noted that “No studies have proven the efficacy of postop radiotherapy after sarcoma resection” [20], and our patient was not placed on any radiotherapy due to the proximity of the original tumor site to critical blood vessels; specifically, the internal iliac artery and vein. Carboni et al. further stated that chemotherapy is reserved for palliative treatment of advanced or metastatic disease, for which our patient was started on an initial schedule of doxorubicin. An analysis of 61 cases of retroperitoneal liposarcoma at a large institution noted that response rates are low, even with doxorubicin being the first-line chemotherapy for metastatic and or unresectable disease [16]. Due to this difficult roadblock, it is not surprising that every article we have encountered reiterates the need for new molecular therapy options [10,11,16,20].

To the best of our knowledge, the present article provides the first case report utilizing recent updates on available treatments for retroperitoneal liposarcoma. For a short time, Olaratumab (Lartruvo), an immunoglobulin G (Ig) G1 human antibody, was thought to be an innovative treatment for soft-tissue sarcomas. A paper published in May 2018 noted that, used in combination with doxorubicin, olaratumab had shown improved overall survival compared with doxorubicin monotherapy [21]. However, Olaratumab was removed from the market in January 2019 after failure in a phase III trial. The NCCN (National Comprehensive Cancer Network) now recommends using Palbociclib (Ibrance), a selective inhibitor of CDK4 and CDK6, for treatment of patients with well-differentiated and de-differentiated liposarcoma (category 2A) [22]. Our patient was treated by his oncologist using doxorubicin for his initial 4 cycles of chemotherapy, yet he continued having disease progression. Therefore, he was switched to a different modality using Palbociclib in March 2019, with the intent of halting the progression of metastases. However, his sarcoma proved to be resistant to Palbociclib, and CT imaging done the following June (Figure 6A, 6B) showed growth of multiple recurrent nodules in the left retroperitoneal resection bed and metastases to the left lung (Figure 7). Our patient was subsequently started on third-line therapy with the chemotherapy agent Halaven (Eribulin), a microtubule inhibitor, attempting to halt the progression of disease. Halaven is used to treat patients



**Figure 6.** (A) CT abdomen and pelvis – axial view. (B) CT abdomen and pelvis – coronal view. Abnormal soft-tissue density (orange arrows) along the inferior aspect of the operative bed, measuring approximately 2.7 cm in size, and likely a new recurrence.



**Figure 7.** Abnormal pulmonary mass in left lung base, 1.9 cm in size, and is seen posteriorly, with irregular borders.

with liposarcoma that is either metastatic or inoperable and has demonstrated a “clinically significant, albeit moderate, survival benefit in the treatment of advanced soft-tissue sarcomas of liposarcoma histologies” [16]. At this point in time, our patient’s main treatment goal is palliative, extending his lifespan as long as possible.

## Conclusions

Achieving complete resection and the tumor grade at diagnosis are the most important prognostic factors for survival of patients with retroperitoneal liposarcoma [23]. It is important to approach this disease process with a multidisciplinary team

that includes surgical, medical oncology, and radiation oncology. Even with radical resection of the tumor, retroperitoneal sarcomas prove difficult to treat and require trying different chemotherapy modalities (e.g., doxorubicin vs. Eribulin), immunotherapy, or specific targeted therapy (Palbociclib) with follow-up imaging to monitor tumor response. To the best of our knowledge, this is the first case report in the literature to include the latest updates on using either Palbociclib or Eribulin as viable options for an extremely rare malignancy.

All the aforementioned authors made substantial contributions to conception and design, acquisition of data, or analysis and interpretation of data. All the aforementioned authors drafted the article or revised it critically for important intellectual content. All the aforementioned authors gave final approval of the version of the article to be published. All the aforementioned authors agree to be accountable for all aspects of the work in ensuring that questions related to the accuracy or integrity of any part of the work are appropriately investigated and resolved.

## Statement

Part of the payment for publication of this article came from Campbell Medical School for scholarly medical student activity. There was no formal grant given for this research paper.

## Conflicts of interest

None.

## References:

1. Park JO, Qin LX, Prete FP et al: Predicting outcome by growth rate of locally recurrent retroperitoneal liposarcoma: the one centimeter per month rule. *Ann Surg*, 2009; 250(6): 977–82
2. Keung EZ, Hornick JL, Bertagnolli MM et al: Predictors of outcomes in patients with primary retroperitoneal dedifferentiated liposarcoma undergoing surgery. *J Am Coll Surg*, 2014; 218(2): 206–17
3. Wang Z, Wu J, Lv A et al: Infiltration characteristics and influencing factors of retroperitoneal liposarcoma: Novel evidence for extended surgery and a tumor grading system. *Biosci Trends*, 2018; 12(2): 185–92
4. Dickson MA, Schwartz GK, Keohan ML et al: Progression-free survival among patients with well-differentiated or dedifferentiated liposarcoma treated with CDK4 inhibitor palbociclib: A Phase 2 Clinical Trial. *JAMA Oncol*, 2016; 2(7): 937–40
5. Koliou P, Karavasilis V, Theochari M et al: Advances in the treatment of soft tissue sarcoma: focus on eribulin. *Cancer Manag Res*, 2018; 10: 207–16
6. College of American Pathologists. Cancer Protocol Templates. Soft Tissue Resection PDF (v4.0.1.1), accessed 8 Nov. 2019, <https://documents.cap.org/protocols/cp-other-softtissue-resection-19-4011.pdf>
7. Berrington de Gonzalez A, Kutsenko A, Rajaraman P: Sarcoma risk after radiation exposure. *Clin Sarcoma Res*, 2012; 2(1): 18
8. Thway K, Jones RL, Noujaim J et al: Dedifferentiated liposarcoma: Updates on morphology, genetics, and therapeutic strategies. *Adv Anat Pathol*, 2016; 23(1): 30–40
9. Singer S, Antonescu CR, Riedel E, Brennan MF: Histologic subtype and margin of resection predict pattern of recurrence and survival for retroperitoneal liposarcoma. *Ann Surg*, 2003; 238(3): 358–71
10. Lu W, Lau J, Xu MD et al: Recurrent abdominal liposarcoma: Analysis of 19 cases and prognostic factors. *World J Gastroenterol*, 2013; 19(25): 4045–52
11. Lewis JJ, Leung D, Woodruff JM, Brennan MF: Retroperitoneal soft-tissue sarcoma: Analysis of 500 patients treated and followed at a single institution. *Ann Surg*, 1998; 228(3): 355–65
12. Singer S, Corson JM, Demetri GD et al: Prognostic factors predictive of survival for truncal and retroperitoneal soft-tissue sarcoma. *Ann Surg*, 1995; 221(2): 185–95
13. Oh YJ, Yi SY, Kim KH et al: Prognostic model to predict survival outcome for curatively resected liposarcoma: A multi-institutional experience. *J Cancer*, 2016; 7(9): 1174–80
14. Knebel C, Lenze U, Pohlig F et al: Prognostic factors and outcome of Liposarcoma patients: A retrospective evaluation over 15 years. *BMC Cancer*, 2017; 17(1): 410
15. Ghadimi MP, Al-Zaid T, Madewell J et al: Diagnosis, management, and outcome of patients with dedifferentiated liposarcoma systemic metastasis. *Ann Surg Oncol*, 2011; 18(13): 3762–70
16. Luo P, Cai W, Yang L et al: Retroperitoneal dedifferentiated liposarcoma: Analysis of 61 cases from a large institution. *J Cancer*, 2018; 9(21): 3831–38
17. Sato T, Yamaguchi T, Azekura K et al: Repeated resection for intra-abdominal and retroperitoneal liposarcomas: Long-term experience in a single cancer center in Japan. *Int Surg*, 2006; 91(5): 267–71
18. Haas RLM, Bonvalot S, Miceli R et al: Radiotherapy for retroperitoneal liposarcoma: A report from the Transatlantic Retroperitoneal Sarcoma Working Group. *Cancer*, 2019; 125(8): 1290–300
19. Tuan J, Vitolo V, Vischioni B et al: Radiation therapy for retroperitoneal sarcoma. *Radiol Med*, 2014; 119(10): 790–802
20. Carboni F, Valle M, Federici O et al: Giant primary retroperitoneal dedifferentiated liposarcoma. *J Gastrointest Surg*, 2019; 23(7): 1521–23
21. Penniman L, Parmar S, Patel K: Olaratumab (Lartruvo): An innovative treatment for soft tissue sarcoma. *P T*, 2018; 43(5): 267–70
22. Dickson MA, Tap WD, Keohan ML et al: Phase II trial of the CDK4 inhibitor PD0332991 in patients with advanced CDK4-amplified well-differentiated or dedifferentiated liposarcoma. *J Clin Oncol*, 2013; 31(16): 2024–28
23. Bashjawish, Fuad: Rare case of primary retroperitoneal dedifferentiated liposarcoma. Proceedings of the 22<sup>nd</sup> Canada Meetings on Radiology & Novel Cancer Therapies. 2019 June 11–13. Montreal, Canada