

Hirayama's Disease: A Rare Clinical Variant of Amyotrophic Lateral Sclerosis

Abstract

Hirayama's disease is a rare clinical variant of amyotrophic lateral sclerosis where distal muscles are involved more compared to proximal muscles and vice-versa occurs only in 10% cases and so it is differentiated from O'Sullivan McLeod syndrome which involves only small muscles of single limb. Here, we present a case of Hirayama's disease where disease achieved a plateau after 3 years with no further progression. His electrophysiological studies, and clinical picture, and magnetic resonance imaging findings were consistent with a diagnosis of Hirayama's disease.

Keywords: *Amyotrophic lateral sclerosis, Hirayama's disease, monomelic amyotrophy*

Introduction

Hirayama's disease is a very rare variant of amyotrophic lateral sclerosis where the hallmark of diagnosis is the involvement of a single limb with lower motor neuron (LMN) features which are more common in distal muscles than proximal muscles. It's a benign motor neuron disorder with male preponderance. It is commonly misdiagnosed in patients presenting with isolated amyotrophy of upper limb due to other diagnoses. It's a kind of cervical myelopathy related to flexion movement of the neck. Its characteristic is that it progresses for only 2–4 years and then achieves a plateau with spontaneous stabilisation.^[1] The precise cause of this disorder is still unknown. An assumption of imbalanced growth between the patient's vertebral column and spinal canal contents has been postulated till now. Here, we are reporting a case report of Hirayama's disease where the disease achieved a plateau after 3 years and we will discuss his magnetic resonance imaging (MRI) and electromyographic (EMG) findings along with the discussion about how to differentiate it from its other differential diagnoses.

Case Report

A 49-year-old male patient was admitted to our hospital with complaints of the weakness of left upper limb for

20 years. His weakness was associated with fasciculations, and the weakness progressed over a period of 3 years, and then it stopped progressing completely. The patient never experienced any abnormal sensations in the left upper limb. Twenty years back, he was diagnosed to be having some motor neuron disease, and EMG/nerve conduction velocity (NCV) were done. For this, he was only managed conservatively, and was explained about the prognosis. On admission to our hospital, his vitals were stable. On general examination, fasciculations were seen in the left upper limb (mainly the deltoid area). On neurological examination, higher mental functions, cranial nerves, spine, cerebellar functions, gait, jaw jerk, and abdominal reflexes were normal. On motor examination, the patient had predominant proximal muscle weakness of left upper limb (mainly deltoid, supraspinatus, infraspinatus, rhomboids, and small muscles of hands) [Figure 1]. Bulbar muscles and muscles of both the lower limbs were spared. There was hypotonia in proximal muscles of the left upper limb. Deep tendon reflexes were absent in left upper limb. Plantar response was flexor, bilaterally. The sensory system was normal. All his routine blood investigation reports were within normal limits. On the suspicion of Hirayama's disease, the patient was advised EMG/NCV studies which showed lower motor denervation at proximal spinal

**Swati C. Aundhakar,
Sanket K. Mahajan,
Daanish A. Chhapra**

*From the Department of
Medicine, Krishna Institute of
Medical Sciences University,
Karad, Maharashtra, India*

Address for correspondence:

*Dr. Swati C. Aundhakar,
Saurabh Hospital 140,
Budhwar Peth, Karad - 415 110,
Maharashtra, India.
E-mail: dr.swatiaundhakar@
yahoo.co.in*

Access this article online

Website: www.advbiores.net

DOI: 10.4103/2277-9175.211797

Quick Response Code:



How to cite this article: Aundhakar SC, Mahajan SK, Chhapra DA. Hirayama's Disease: A Rare Clinical Variant of Amyotrophic Lateral Sclerosis. *Adv Biomed Res* 2017;6:95.

Received: March, 2013. **Accepted:** July, 2015.

This is an open access article distributed under the terms of the Creative Commons Attribution-NonCommercial-ShareAlike 3.0 License, which allows others to remix, tweak, and build upon the work non-commercially, as long as the author is credited and the new creations are licensed under the identical terms.

For reprints contact: reprints@medknow.com

level involving left upper limb concluding an anterior horn cell disease. MRI cervical spine (neutral, and flexion) was suggestive of cervical cord compression (C3–C5), and anterior displacement of the posterior dural sac. All neurological findings after 20 years were same, as seen in comparison to the patient's previous hospital records. The patient was discharged after proper counselling, and neurologist's opinion who confirmed our diagnosis of Hirayama's disease.

Discussion

Hirayama disease also termed as juvenile muscular atrophy of the unilateral upper extremity, is a type of cervical myelopathy related to flexional movements of the neck.^[2] Hirayama's disease was initially recognized in Japan in 1959 and reported under the name of juvenile muscular atrophy of unilateral upper extremity. Since then, similar cases have been described from many countries, mostly from Asia. In a report in 1991, Chan *et al.* estimated 150 cases from Japan, 37 from India, and 102 from Sri Lanka.^[3] This condition is more prevalent in India, Japan, and Sri Lanka.

Hirayama's disease is a rare, clinical variant of amyotrophic lateral sclerosis where distal muscles are involved, more compared to proximal muscles and vice-versa occurs only in 10% cases,^[4,5] just like in our case which makes our case even more interesting. The onset of Hirayama's disease is usually between 15 and 25 years. There is sparing of brachioradialis muscle giving the impression of "oblique atrophy."^[4,6,7] Left side is affected more than the right side, just as in our case. Fasciculations are present in 47–66% on the affected side, with no sensory loss. Local cramps and spasms are present in only 30% cases only. Less common features include coldness of hands, hyperhidrosis, and aggravation of motor symptoms on exposure to cold.^[8] There is no relationship between the patient's handedness, and side of greater muscular atrophy.^[5,9] The weakness in Hirayama's disease progresses over 1 month–5 years and

has a self-limiting course. The nonprogressive state lasts for decades. Mild disabilities are seen in 73% cases.

Hirayama's disease is differentiated from O'Sullivan McLeod syndrome which involves only small muscles of the single limb. It is to be differentiated from "flail arm syndrome" where the later has bilateral symmetric involvement of upper limbs with LMN signs in both upper limbs. When the duration of the symptoms is short, several conditions that also cause localized amyotrophy of the distal arm – including syringomyelia, amyotrophic lateral sclerosis, cervical spondylotic myelopathy, and spinal cord tumour – should be differentiated from Hirayama's disease. One of the diseases that should be considered is a postpolio syndrome, which can be differentiated from Hirayama's disease by a definite history of poliomyelitis. Hirayama disease is different from the known types of motor neuron diseases because of its nonprogressive behaviour, and pathologic findings of focal ischemic changes in the anterior horn of the lower cervical cord.^[10] Hirayama's disease should be distinguished from multiple motor neuropathies when the amyotrophy is distally in the upper limb, and in this disease there is an evidence of conduction block in motor nerves, and high serum titers of anti-GM1 ganglioside antibodies. A chronic focal myositis can be differentiated by an elevated serum creatine phosphokinase, and the EMG, and the muscle histologic features.

MRI cervical spine in Hirayama's disease may show the spinal cord compression on neck flexion with anterior shifting of posterior dura [Figure 2]. Nerve conduction studies frequently demonstrates the low amplitude compound muscle action potentials commensurate with degree of weakness, and atrophy.^[5] The EMG findings usually show loss of motor unit potentials which are rapidly firing, high amplitude, and polyphasic, as seen in anterior horn cell disorders.^[4,5,9] These changes are localized to lower cervical and T1 myotomes. Fibrillation potentials and sharp waves may be seen.^[7]

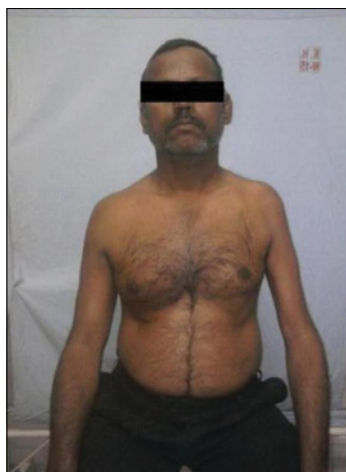

Figure 1: Involvement of muscles of left upper limb in Hirayama's disease

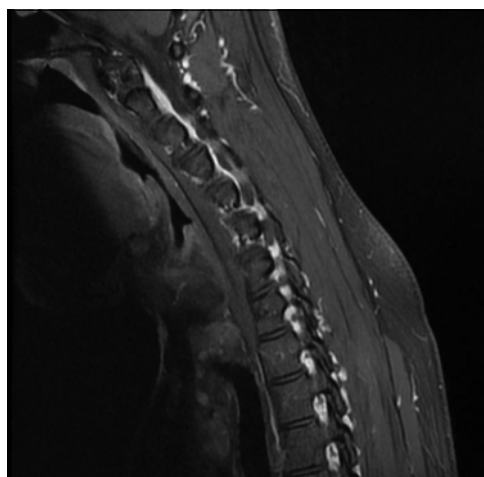


Figure 2: Sagittal flexion T2-weighted image shows anterior displacement of posterior dural sac and cord compression

The pathogenesis is still unclear, and is thought mainly due to dynamic spinal cord compression due to neck flexion with forward displacement of posterior dura as the primary mechanism.^[6] The lower cervical cord moves forward in flexion and contacts the posterior surface of the vertebrae, and becomes flattened at the contact point.^[5] The posterior wall of the dural tube also moves forward, the posterior epidural space expands forming a crescent shaped mass in the posterior epidural space mainly due to the congestion of posterior internal vertebral venous plexus.^[5] The anterior horn cells which are vulnerable to ischemia begin to degenerate, resulting in localized cord atrophy of the lower cervical region, weak, and wasted hands and forearms.^[11] The clinical features and diagnosis of our case are persistent with a report of 73 patients by Hirayama and Tokumaru who concluded that dynamic cord compression in flexion with forward displacement of posterior dura is an unequivocal finding in progressive stage. The mechanism of myelopathy may involve ischemic changes, or chronic trauma by repeated neck flexion affecting anterior horn cells along with spinal cord thinning, termed as flexion myelopathy.^[6]

The prognosis is good in Hirayama's disease compared to other forms of motor neuron diseases with less morbidity, and prolonged survival as there is no specific treatment for this condition. The primary principle of treatment is a restriction of neck flexion. The posture with long-term neck flexion must be avoided. Low pillows are recommended. The anterior fusion of cervical vertebrae, and duraplasty, with or without anterior fusion has been performed. The indications and methods of surgical treatment remains controversial.^[5]

Declaration of patient consent

The authors certify that they have obtained all appropriate patient consent forms. In the form the patient(s) has/have given his/her/their consent for his/her/their images and other clinical information to be reported in the journal. The patients understand that their names and initials will not be published and due efforts will be made to conceal their identity, but anonymity cannot be guaranteed.

Financial support and sponsorship

Nil.

Conflicts of interest

There are no conflicts of interest.

References

1. Orsini M, Freitas MR, Catbarino A, Mello MP, Nascimento OJ. Upper limb proximal form of benign monomelic amyotrophy: On purpose of 2 cases. *Rev Bras Neurol* 2008;44:13-7.
2. Hirayama K. Non-progressive juvenile spinal muscular atrophy of the distal upper limb (Hirayama's disease). In: De Jong JM, editor. *Handbook of Clinical Neurology*. Vol. 15. Amsterdam, The Netherlands: Elsevier; 1991. p. 107-20.
3. Chan YW, Kay R, Schwartz MS. Juvenile distal spinal muscular atrophy of upper extremities in Chinese males: A single fibre electromyographic study of arms and legs. *J Neurol Neurosurg Psychiatry* 1991;54:165-6.
4. Nascimento OJ, Freitas MR. Non-progressive juvenile spinal muscular atrophy of the distal upper limb (Hirayama's disease): A clinical variant of the benign monomelic amyotrophy. *Arq Neuropsiquiatr* 2000;58:814-9.
5. Kikuchi S, Tashiro K. Juvenile muscular atrophy of distal upper extremity (Hirayama disease). In Jones HR Jr, De Vivo DC, Darras BT, editors. *Neuromuscular Disorders of Infancy, Childhood and Adolescence – A Clinician's Approach*. UK: Butterworth-Heinemann; 2003. p. 167-81.
6. Gandhi D, Goyal M, Bourque PR, Jain R. Case 68: Hirayama disease. *Radiology* 2004;230:692-6.
7. Ochi H, Murai H, Osoegawa M, Minohara M, Inaba S, Kira J. Juvenile muscular atrophy of distal upper extremity associated with airway allergy: Two cases successfully treated by plasma exchange. *J Neurol Sci* 2003;206:109-14.
8. Gourie-Devi M, Nalini A. Long-term follow-up of 44 patients with brachial monomelic amyotrophy. *Acta Neurol Scand* 2003;107:215-20.
9. Peiris JB, Seneviratne KN, Wickremasinghe HR, Gunatilake SB, Gamage R. Non familial juvenile distal spinal muscular atrophy of upper extremity. *J Neurol Neurosurg Psychiatry* 1989;52:314-9.
10. Hirayama K, Toyokura Y, Tsubaki T. Juvenile muscular atrophy of unilateral upper extremity: A new clinical entity. *Psychiatr Neurol Jpn* 1959;61:2190-7.
11. Tayade AT, Kale SK, Pandey A, Kalantri S. Hirayama disease. *J Neurosci Rural Pract* 2010;1:46-8.