

Available online at [www.sciencedirect.com](http://www.sciencedirect.com)

ScienceDirect

journal homepage: [www.elsevier.com/locate/radcr](http://www.elsevier.com/locate/radcr)

## Case Report

# CT, MRI, and FDG-PET imaging findings of low-grade extrauterine endometrial stromal sarcoma arising from the mesentery: A case report <sup>☆</sup>

Satoshi Suzuki, MD<sup>a</sup>, Ryo Kurokawa, MD, PhD<sup>a,\*</sup>, Tetsushi Tsuruga, MD, PhD<sup>b</sup>, Mayuyo Mori-Uchino, MD, PhD<sup>b</sup>, Haruka Nishida, MD, PhD<sup>b</sup>, Tomoyasu Kato, MD, PhD<sup>c</sup>, Hiroyuki Abe, MD, PhD<sup>d</sup>, Tetsuo Ushiku, MD, PhD<sup>d</sup>, Shiori Amemiya, MD, PhD<sup>a</sup>, Akira Katayama, MD<sup>a</sup>, Osamu Abe, MD, PhD<sup>a</sup>

<sup>a</sup> Department of Radiology, Graduate School of Medicine, The University of Tokyo, 7-3-1 Hongo, Bunkyo-ku, Tokyo 113-8655, Japan

<sup>b</sup> Department of Obstetrics and Gynecology, Graduate School of Medicine, The University of Tokyo, Tokyo, Japan

<sup>c</sup> Department of Gynecology, National Cancer Center Hospital, Tokyo, Japan

<sup>d</sup> Department of Pathology, Graduate School of Medicine, The University of Tokyo, Tokyo, Japan

## ARTICLE INFO

## Article history:

Received 15 June 2021

Revised 20 June 2021

Accepted 21 June 2021

## Keywords:

Extrauterine endometrial stromal sarcoma

Mesentery

JAZF1

Computed tomography

Magnetic resonance imaging

Fluorodeoxyglucose-positron emission tomography

## ABSTRACT

Endometrial stromal sarcoma is a rare uterine mesenchymal neoplasm, and extrauterine endometrial stromal sarcoma is even rarer, with a limited number of case reports. In the present report, we present a case of low-grade extrauterine endometrial stromal sarcoma originating from the mesentery in a 49-year-old woman, without endometrial stromal sarcoma in the uterus or evidence of endometriosis. The tumor was diagnosed using recombination of the JAZF1 gene by fluorescence in situ hybridization. Computed tomography, magnetic resonance imaging, and 18F-fluorodeoxyglucose positron emission tomography/computed tomography showed a 13 cm, primarily polycystic, mass containing a contrast-enhancing solid component with restricted diffusion and mild 18F-fluorodeoxyglucose uptake. A large cystic component may be a characteristic feature of extrauterine endometrial stromal sarcoma, given the low pressure from the surrounding tissues.

© 2021 The Authors. Published by Elsevier Inc. on behalf of University of Washington.

This is an open access article under the CC BY-NC-ND license (<http://creativecommons.org/licenses/by-nc-nd/4.0/>)

<sup>☆</sup> Competing Interests: The authors have declared that no competing interests exist.

\* Corresponding author.

E-mail address: [kuroro63@gmail.com](mailto:kuroro63@gmail.com) (R. Kurokawa).

<https://doi.org/10.1016/j.radcr.2021.06.063>

1930-0433/© 2021 The Authors. Published by Elsevier Inc. on behalf of University of Washington. This is an open access article under the CC BY-NC-ND license (<http://creativecommons.org/licenses/by-nc-nd/4.0/>)

## Introduction

Endometrial stromal sarcoma (ESS) is a rare uterine mesenchymal neoplasm, accounting for < 10% of uterine sarcomas and 0.2% of all primary malignant tumors of the uterus [1]. In the 2020 World Health Organization (WHO) “Classification of Tumours of Female Reproductive Organs,” endometrial stromal tumors and related tumors were classified into four categories: benign endometrial stromal nodules, low-grade ESS (LGESS), high-grade ESS (HGESS), and undifferentiated uterine sarcoma [2]. Extrauterine ESS (EESS) is an even rarer entity, thought to originate from foci of endometriosis [3]. Most reports on EESS involve cases of LGESS, few cases of HGESS [4,5], and no cases of benign endometrial stromal nodules or undifferentiated uterine sarcoma, which is in-line with the frequency of each category in uterine ESS. Here, we present a case of low-grade EESS in the mesentery with no evidence of primary uterine ESS or endometriosis.

## Case report

A 49-year-old woman with increasing lower abdominal pain was referred to our institution 4 months after undergoing a medical check-up with reported ovarian enlargement. Ultrasonography detected a solid polycystic mass measuring 12 × 12 cm. She had no medical history other than depression, and no family history of malignancies, except for her father, who had prostate cancer. Laboratory analysis was not significant except for a slight increase in CA-125 of 42 U/mL (normal range, 0-35 U/mL).

Contrast-enhanced computed tomography (CT) revealed a 13 cm solid and cystic mass with contrast enhancement (Fig. 1). The dorsal edge of the mass was ill-defined, and internal walls were found within the mass. The mesenteric vein, which was suspected to be the drainage vein, was located at the periphery of the mass (Fig. 1B). On magnetic resonance imaging (MRI), the solid part of the tumor showed heterogeneous intensity on T2-weighted imaging (T2WI) and T1-weighted imaging (T1WI) with restricted diffusion

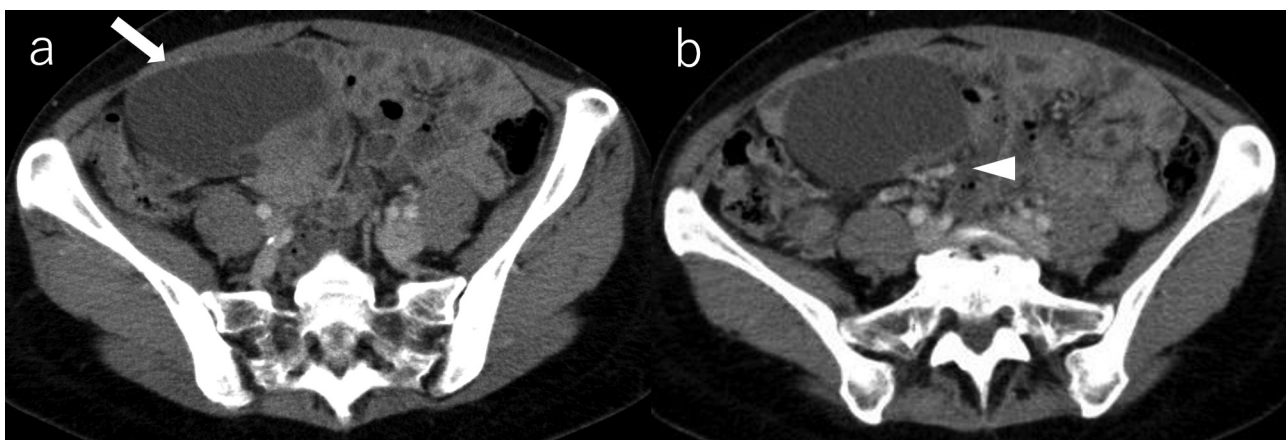(Fig. 2). No abnormality was suspected in the uterus, other than typical leiomyomas, and both ovaries were normal. 18F-fluorodeoxyglucose positron emission tomography/CT (FDG-PET/CT) was also performed, on which FDG accumulated in the solid part of the tumor with a maximum standardized uptake value (SUVmax) of 4.5 and 5.9 at 1 and 2 h after isotope injection, respectively (Fig. 3). No metastasis was observed.

Malignancies, including gastrointestinal stromal tumors, were considered for the differential diagnosis, and laparotomy was performed. Direct visual inspection during surgery revealed that the uterus and ovaries were intact, and the mass was confirmed to arise from the mesentery (Fig. 4), after which it was removed. No metastasis or dissemination was observed.

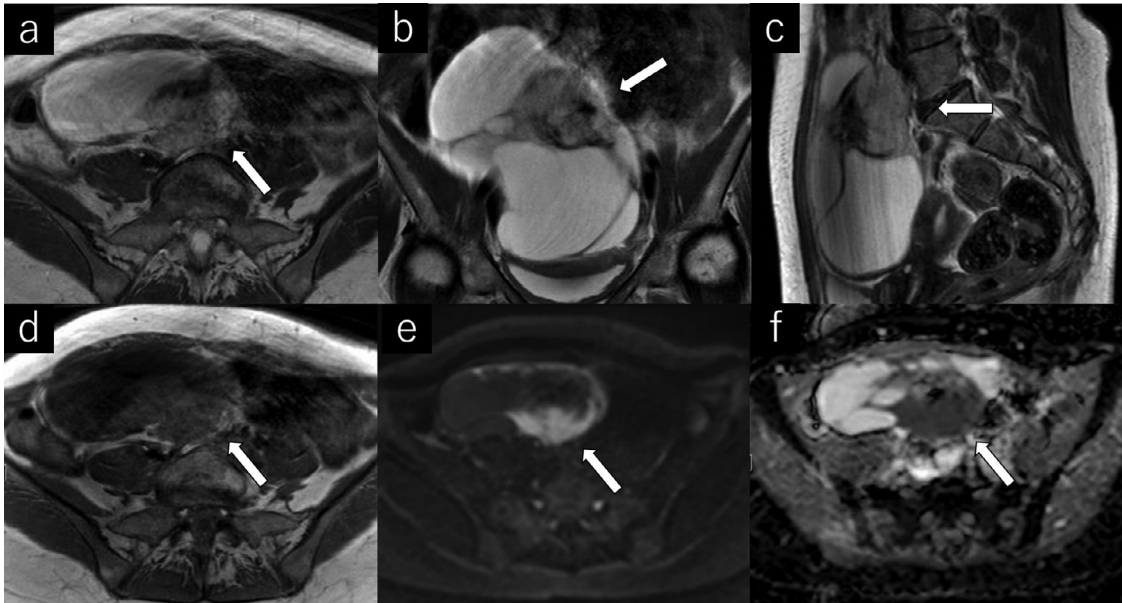
Macroscopically, the tumor was polycystic with a soft, yellow-white solid component. Histologically, diffuse proliferation of cells with ovoid- to spindle-like nuclei and clear cytoplasm was observed (Fig. 5). Cell density was high in a few regions of hemorrhage, edema, and necrosis. The tumor was covered with a fibrous capsule, and the margins were negative. Several foci of venous invasion were observed. Ki-67 was positive in approximately 20% of cells. Immunohistochemically, proliferating cells were positive for cluster of differentiation 10 (CD10) and estrogen receptor (ER). The recombination of the JAZF1 gene was identified by fluorescence in situ hybridization (FISH), and the tumor was diagnosed as low-grade EESS. No PHF1 gene recombinations were observed. Because uterine involvement was highly suspected, hysterectomy and bilateral salpingo-oophorectomy were performed; however, no malignancy or endometriosis was observed. After discharge, the patient was regularly attended follow-up visits.

## Discussion

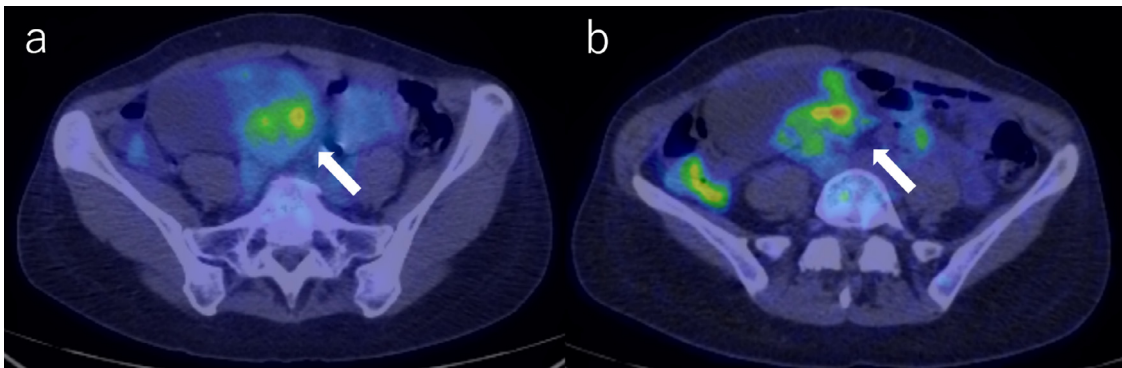
We have reported herein a case of low-grade EESS originating from the mesentery. A few other authors have reported cases of EESS originating from extrauterine organs, such as the colon [6], small bowel [7], stomach [8], round ligament [9], ovary [10], vagina [11], peritoneum [12], lung [5], and mesentery [13–16]; however, to the best of our knowledge, only four cases of EESS originating from the mesentery have been re-



**Fig. 1 – (A) A 13 cm solid and cystic mass with contrast enhancement (arrow); (B) the mesenteric vein is located at the periphery of the mass (arrowhead)**



**Fig. 2** – The solid part of the mass (arrows) shows heterogeneous signal intensity on axial (A), coronal (B), and sagittal T2-weighted imaging (T2WI) (C), and axial T1-weighted imaging (T1WI) (D); the dorsal edge of the mass is ill-defined; diffusion is restricted in the solid part with apparent diffusion coefficient (ADC) of  $1.04 \times 10^{-3} \text{ mm}^2/\text{s}$  (E and F)



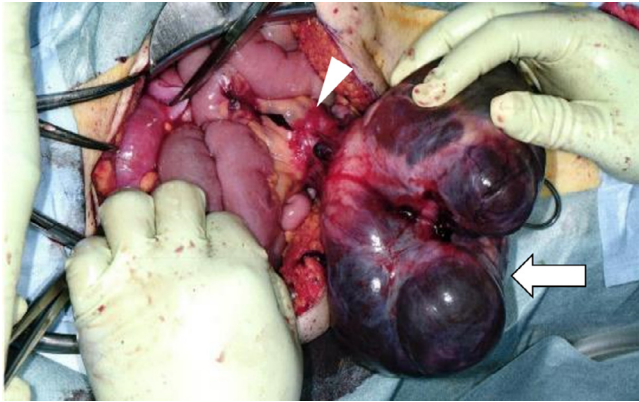
**Fig. 3** –  $^{18}\text{F}$ -fluorodeoxyglucose positron emission tomography/computed tomography (FDG-PET/CT) shows abnormal FDG uptake in the solid part (arrows); the maximum standardized uptake value (SUVmax) was 4.5 at 1 h after (A) and 5.9 at 2 h after isotope injection (B).

ported in the available English literature, and the present case is the first to report all of CT, MRI, and FDG-PET/CT findings.

According to a study by Masand et al. [17], which summarized 63 cases of ESS with extrauterine involvement, the median age was 50 years (range, 27–87 years), and the most frequent symptoms reported were abdominal and pelvic masses, pain, genital bleeding, and gastrointestinal symptoms. Endometriosis was noted in 30/63 cases. LGESS generally has an indolent clinical course with a median overall survival of 80 months [18]. Lan et al. [19] speculated that EESS of endometrioid origin might be more prone to dissemination, as the incidence of dissemination was 76.9% in low-grade EESS arising from endometriosis, and 31% in uterine LGESS. In the present case, there was no history of endometriosis nor were there findings suggestive of endometriosis at the time of surgery.

Although it is possible that the EESS originated from subclinical endometriosis, the absence of disseminated lesions in the present case may be related to the absence of coexisting endometriosis.

Preoperative diagnosis of EESS is considered challenging, especially in the absence of uterine ESS, as in the present case, because of the rarity of the condition and the radiological similarities with other tumors, such as leiomyoma, leiomyosarcoma, and gastrointestinal stromal tumor. Radiologically, uterine LGESS forms a polypoidal endometrial mass with a well-defined or infiltrative border [20,21]. MRI typically shows heterogeneous isointensity on T1WI and heterogeneous hyperintensity on T2WI [21], but the signal intensity on T2WI may vary depending on the degenerative changes [22]. Several characteristic MRI features of LGESS have been

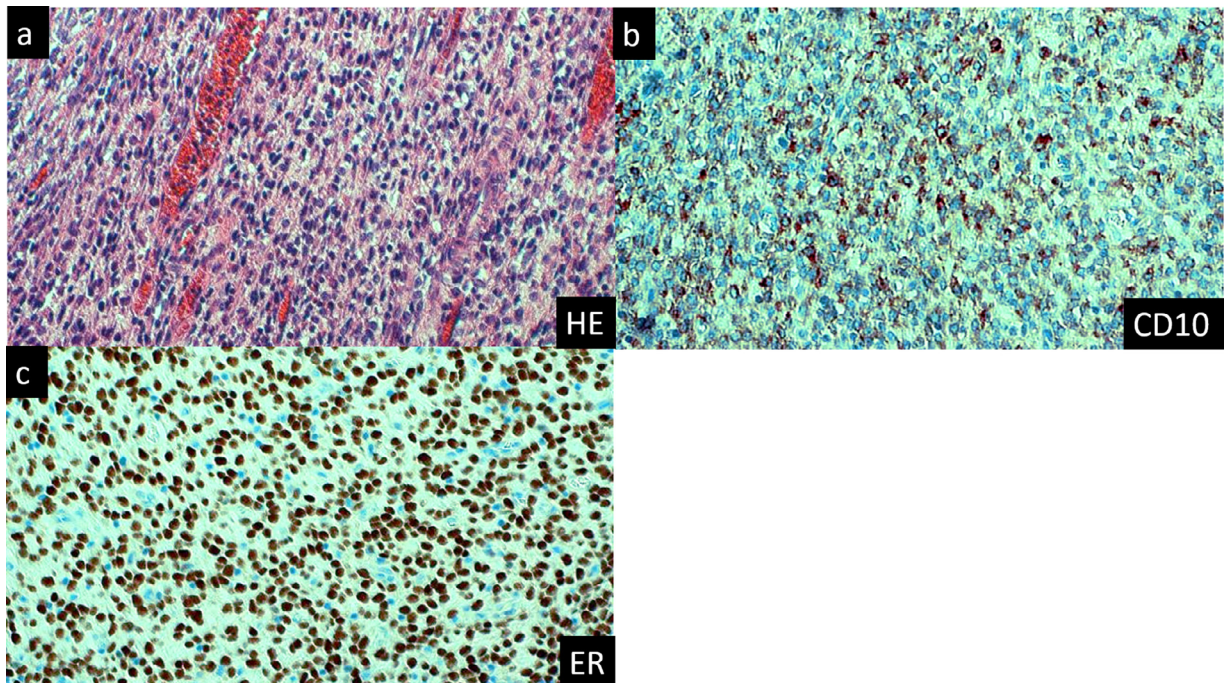


**Fig. 4 – Operative view of the tumor (arrow) arising from the mesentery (arrowhead)**

reported as follows: a worm-like nodular extension [21] indicates lymphatic and vascular invasion into the myometrium; and T2WI hypointense bands [22], indicating the preserved normal myometrium surrounded by the tumor, and the extension along with the ligaments [23]. LGESS is typically moderately enhanced after contrast enhancement, and restricted diffusion with a mean ADC value of 1.09 [24, 25]. The reported SUVmax of LGESS was 5.41 [26] and 13.28 [27]. However, there are very few reports available on the imaging features of low-grade EESS. Almost nothing is known about the differences in imaging features between uterine ESS and EESS because of the rarity of these tumors.

The large polycystic part of the tumor was a major characteristic of the present case. We speculated that the cystic components of EESS might tend to be larger than those in uterine ESS, given the lower pressure from the surrounding tissues in the uterine myometrium. However, very few studies have focused on this issue. Khan et al. [14] reported two EESS cases (the grade was low in one patient but undescribed for the other), in which CT imaging showed large tumors occupying the right lobe of the liver, and most of the tumors had large cystic components in both cases. Kim et al. [7] reviewed 16 EESS cases, including the 2 cases reported by Khan et al. [14], and 4 EESS cases contained cystic parts macroscopically, although the grade was unknown in 3 of them. In a review of low-grade EESS by Xie et al. [28], 2 out of 9 included cystic parts macroscopically; however, information about the size of the cystic components was unavailable. For uterine LGESS, although cystic change is frequent (up to 70%), cystic components tend to be small as seen in the study by Park et al. [29], in which the mean size of 10 LGESS cases including 7 cystic components was 2.8 cm (range, 1.3–4.5 cm). EESS may therefore be characterized by a tendency to have a larger cystic component compared to uterine ESS. To confirm this, further investigation with a larger number of patients is needed.

Pathological findings of low-grade EESS are similar to those of uterine LGESS [4]. Macroscopically, LGESS is circumscribed, solid, and multinodular. It is composed of monotonous cells with scant cytoplasm and minimal atypia [30]. Immunohistochemically, ESS is positive for CD10, ER, and progesterone receptor, and may also be positive for smooth muscle markers, including H-caldesmon and desmin [31]. Ki-67 index and p53 immunoreactivity were lower than those of HGEES. LGESS fre-



**Fig. 5 – Microscopic view of the resected specimen (×100 each); (A) Hematoxylin and eosin (HE) stain shows diffuse proliferation of cells with ovoid- to spindle-like nuclei with a few regions of hemorrhage, edema, and necrosis; immunohistochemical staining with (B) cluster of differentiation 10 (CD10) and (C) ER was positive.**

quently involves fusion of two zinc finger genes between chromosomes 7 and 17, *JAZF1/SUZ12* and/or *JAZF1/PHF1*, which is useful for differentiating LGESS from HGESS [32]. These pathological features were also found in the present case, including the recombination of the *JAZF1* gene seen in FISH. The management of EESS usually follows that of uterine ESS [33], where the first-line treatment is hysterectomy and adnexectomy, followed by adjuvant hormonal therapy [34]. In cases of EESS, resection of the EESS is also required. The benefits of adjuvant hormonal therapy for EESS may be limited, however, especially in cases of advanced or metastatic disease [33].

## Conclusion

We have reported herein a case of low-grade EESS originating from the mesentery, without uterine ESS or evidence of endometriosis, which was formally diagnosed through FISH. CT, MRI, and FDG-PET/CT imaging showed a 13 cm mainly polycystic mass containing a contrast-enhanced solid component with restricted diffusion and mild FDG uptake. A large cystic component may be a characteristic feature of EESS, given the low pressure of the surrounding tissues, although further investigation is necessary.

## Patient Consent Statement

Informed consent for patient information to be published in this article was obtained.

## REFERENCES

- [1] Puliyaath G, Nair MK. Endometrial stromal sarcoma: a review of the literature. *Indian J Med Paediatr Oncol* 2012;33:1–6. doi:10.4103/0971-5851.96960.
- [2] Kurman RJ, Carcangiu ML, Young RH, Simon Herrington C. 2014. WHO classification of tumours of female reproductive organs. International Agency for Research on Cancer, Lyon, France.
- [3] Oliva E, Egger JF, Young RH. Primary endometrioid stromal sarcoma of the ovary: a clinicopathologic study of 27 cases with morphologic and behavioral features similar to those of uterine low-grade endometrial stromal sarcoma. *Am J Surg Pathol* 2014;38:305–15. doi:10.1097/PAS.000000000000145.
- [4] Wang F, Lei R, Yang H, Guo M, Tan G. Endometrial stromal sarcoma: a clinicopathological analysis of 14 cases. *Int J Clin Exp Pathol* 2018;11(5):2799–804.
- [5] Alessandrini L, Sopracordevole F, Bertola G, Scalone S, Urbani M, Miolo G, et al. Primary extragenital endometrial stromal sarcoma of the lung: first reported case and review of literature. *Diagn Pathol* 2017;12:36. doi:10.1186/s13000-017-0627-2.
- [6] Son HJ, Kim JH, Kang DW, Lee HK, Park MJ, Lee SY. Primary extrauterine endometrial stromal sarcoma in the sigmoid colon. *Ann Coloproctol* 2015;31:68–73. doi:10.3393/ac.2015.31.2.68.
- [7] Kim L, Choi SJ, Park IS, Han JY, Kim JM, Chu YC, et al. Endometrial stromal sarcoma of the small bowel: a case report and review of literature. *Ann Diagn Pathol* 2008;12:128–33. doi:10.1016/j.anndiagpath.2006.03.020.
- [8] Jin M, Reynolds JP, Odronic SI, Wakely PE. Primary gastric extra-uterine endometrial stromal sarcoma. *Ann Diagn Pathol* 2014;18:187–90. doi:10.1016/j.anndiagpath.2014.02.001.
- [9] Miglani U, Laul P, Bindal N, Chhibber P, Saxena P. Extrauterine endometrial stromal sarcoma: a rare entity. *Indian J Gynecol Oncol* 2019;17:38. doi:10.1007/s40944-019-0281-6.
- [10] Efares B, Sidibé IS, Erregad F, Hammas N, Chbani L, el Fatemi H. Extra-uterine low grade endometrioid stromal sarcoma arising from ovarian endometriosis: a case report and review of the literature. *Gynecol Oncol Res Pract* 2019;6(2). doi:10.1186/s40661-019-0067-7.
- [11] Liu Z, Ding J, Li X, Yu K. Endometrial stromal sarcoma arising in vagina. *Int J Clin Exp Pathol* 2013;6:2997–3002.
- [12] Clair K, Wolford J, Veran-Taguibao S, Kim G, Eskander RN. Primary low-grade endometrial stromal sarcoma of the Omentum. *Gynecol Oncol Rep* 2017;21:119–21. doi:10.1016/j.gore.2017.08.002.
- [13] Welfel J, Gottwald L, Kowalczyk-Amico K, Szwalski J, Lech W, Suzin J. Low-grade endometrial stromal sarcoma firstly localized in colonic mesentery. *Ginekol Pol* 2004;75:150–2.
- [14] Khan AW, Craig M, Jarmulowicz M, Davidson BR. Liver tumours due to endometriosis and endometrial stromal sarcoma. *HPB* 2002;4(1):43–6. doi:10.1080/136518202753598735.
- [15] Schoolmeester JK, Sciallis A, Greipp PT, Hodge JC, Cin PD, Keeney GL, et al. Analysis of MDM2 amplification in 43 endometrial stromal tumors: a potential diagnostic pitfall. *Int J Gynecol Pathol* 2015;34:576–83. doi:10.1097/pgp.0000000000000187.
- [16] Verma A, Menon S, Rekhi B, Pai T, Maheshwari A, Ghosh J, et al. Utility of YWHAE fluorescent in-situ hybridisation in mesenchymal tumors of uterus—an initial experience from tertiary oncology centre in India. *Indian J Cancer* 2019;56(4):335–40. doi:10.4103/ijc.ijc\_722\_18.
- [17] Masand RP, Euscher ED, Deavers MT, Malpica A. Endometrioid stromal sarcoma: a clinicopathologic study of 63 cases. *Am J Surg Pathol* 2013;37:1635–47. doi:10.1097/PAS.0000000000000083.
- [18] Leath CA, Huh WK, Hyde J, Cohn DE, Resnick KE, Taylor NP, et al. A multi-institutional review of outcomes of endometrial stromal sarcoma. *Gynecol Oncol* 2007;105:630–4. doi:10.1016/j.ygyno.2007.01.031.
- [19] Lan C, Huang X, Lin S, Cai M, Liu J. Endometrial stromal sarcoma arising from endometriosis: a clinicopathological study and literature review. *Gynecol Obstet Invest* 2012;74:288–97. doi:10.1159/000341706.
- [20] Huang YL, Ueng SH, Chen K, Huang YT, Lu HY, Ng KK, et al. Utility of diffusion-weighted and contrast enhanced magnetic resonance imaging in diagnosing and differentiating between high- and low-grade uterine endometrial stromal sarcoma. *Cancer Imag* 2019(63):19. doi:10.1186/s40644-019-0247-z.
- [21] Chaitra PA, Gyanchandani M, Goolahally LN, Itagi RM, Kalenahalli KV. Endometrial stromal sarcoma: an aggressive uterine malignancy. *J Radiol Case Rep* 2016;10(9):35–43. doi:10.3941/jrcr.v10i9.2770.
- [22] Li HM, Liu J, Qiang JW, Gu WY, Zhang GF, Ma FH. Endometrial stromal sarcoma of the uterus magnetic resonance imaging findings including apparent diffusion coefficient value and its correlation with Ki-67 expression. *Intl J Gynecol Cancer* 2017;27(9):1877–87. doi:10.1097/igc.0000000000001114.
- [23] Koyama T, Togashi K, Konishi I, Kobayashi H, Ueda H, Kataoka ML, et al. MR imaging of endometrial stromal sarcoma: correlation with pathologic findings. *Am J Roentgenol* 1999;173:767–72. doi:10.2214/ajr.173.3.10470920.

- [24] Santos P, Cunha TM. Uterine sarcomas: clinical presentation and MRI features. *Diagn Interv Radiol* 2015;21:4–9. doi:10.5152/dir.2014.14053.
- [25] Huang YT, Huang YL, Ng KK, Lin G. Current status of magnetic resonance imaging in patients with malignant uterine neoplasms: a review. *Korean J Radiol* 2019;20(1):18–33. doi:10.3348/kjr.2018.0090.
- [26] Yamamoto M, Tsujikawa T, Yamada S, Kurokawa T, Shinagawa A, Chino Y, et al. 18F-FDG/18F-FES standardized uptake value ratio determined using PET predicts prognosis in uterine sarcoma. *Oncotarget* 2017;8:22581–9. doi:10.18632/oncotarget.15127.
- [27] Fujiishi K, Nagata S, Kano R, Kubo C, Shirayanagi M, Ozaki M, et al. JAZF1–SUZ12 endometrial stromal sarcoma forming subserosal masses with extraordinary uptake of fluorodeoxyglucose on positron emission tomography: a case report. *Diagn Pathol* 2019;14:110. doi:10.1186/s13000-019-0897-y.
- [28] Xie W, Bi X, Cao D, Yang J, Shen K, You Y. Primary endometrioid stromal sarcomas of the ovary: a clinicopathological study of 14 cases with a review of the literature. *Oncotarget* 2017;8:63345–52. doi:10.18632/oncotarget.18805.
- [29] Park GE, Rha SE, Oh SN, Lee A, Lee KH, Kim MR. Ultrasonographic findings of low-grade endometrial stromal sarcoma of the uterus with a focus on cystic degeneration. *Ultrason* 2016;35:124–30. doi:10.14366/usg.15045.
- [30] Lipsich F, Andrieu PIC, Wernicke A, Patrono MG, Napoli MN, Beatriz Chacon CR, et al. Extra-uterine endometrial stromal sarcoma arising from deep infiltrating endometriosis. *Clin Imag* 2020;67:250–4. doi:10.1016/j.clinimag.2020.08.015.
- [31] Sato S, Ojima Y, Kanda M, Kizaki T, Ohara N. Endometrial stromal sarcoma arising from endometrial polyp: a case report. *Kobe J Med Sci* 2018;64(2):E36–42.
- [32] Hodge JC, Bedroske PP, Pearce KE, Sukov WR. Molecular cytogenetic analysis of JAZF1, PHF1, and YWHAE in endometrial stromal tumors discovery of genetic complexity by fluorescence in situ hybridization. *J Mol Diagn* 2016;18:516–26. doi:10.1016/j.jmoldx.2016.02.001.
- [33] Mercier NB, Roberts LF, Azordegan N, Altman AD. Extra-uterine endometrial stromal sarcoma of the left adnexa and distal ureter: a case report. *Gynecol Oncol Rep* 2021;36:100702. doi:10.1016/j.gore.2021.100702.
- [34] Thiel FC, Halmen S. Low-grade endometrial stromal sarcoma—a review. *Oncol Res Treat* 2018;41:687–92. doi:10.1159/000494225.