

Intestinal Perforation during the Stabilization Period in a Preterm Infant with Congenital Diaphragmatic Hernia

Zbyněk Straňák^{1,2} Karel Pýcha³ Simona Feyereislova^{1,2} Jaroslav Feyereisl² Michal Rygl³

¹Third Faculty of Medicine, Charles University, Prague, Czech Republic

²Fetal Medicine Centre, Institute for the Care of Mother and Child, Prague, Czech Republic

³Department of Pediatric Surgery, Second Faculty of Medicine, Charles University, Prague, Czech Republic

Address for correspondence Dr med Simona Feyereislova, MD, Fetal Medicine Centre, Institute for the Care of Mother and Child, Prague 14700, Czech Republic (e-mail: simona.feyereislova@gmail.com).

Eur J Pediatr Surg Rep 2017;5:e51–e54.

Abstract

Background Delayed surgery after stabilization of infants with congenital diaphragmatic hernia (CDH) is an accepted strategy. However, the evidence favoring delayed versus immediate surgical repair is limited. We present an extremely rare case of a very low-birth-weight infant with prenatally diagnosed left-sided CDH and unexpected transmural bowel perforations developing within the postnatal stabilization period.

Case Report A neonate born at 31st week of gestation with a birth weight of 1,470 g with antenatally diagnosed left-sided CDH presented with bowel dilation leading to transmural bowel perforations on the 2nd day of life. Meconium pleuroperitonitis resulted in severe systemic inflammatory response syndrome, pulmonary hypertension, multiple organ failure, and death.

Conclusion In neonates with CDH deteriorating under standard postnatal management, intestinal perforation, and early surgical intervention should be considered.

Keywords

- ▶ congenital diaphragmatic hernia
- ▶ delayed surgery
- ▶ bowel perforation

New Insights and the Importance for the Pediatric Surgeon

A rare case of a very low birth weight infant with prenatally diagnosed congenital diaphragmatic hernia (CDH) in the unusual association with bowel perforation whilst undergoing standard protocol with delayed surgery is presented and compared with published literature.

Although the role of early surgery in preterm CDH patients and its possible positive impact on prevention of unexpected complications remains unclear, it may be of benefit to keep this possibility in mind for this kind of very rare and highly specific patient population (preterm and growth restricted CDH neonates).

Spontaneous intestinal perforation requiring early surgical intervention should be considered in the differential diagnoses in a clinically deteriorating preterm neonate.

Introduction

The management of congenital diaphragmatic hernia (CDH) remains challenging despite advances in neonatal care.


Infants with CDH mostly present with immediate respiratory deterioration after delivery due to pulmonary hypoplasia and pulmonary hypertension.¹ The strategy of delayed surgical repair of CDH after physiological

received
September 8, 2016
accepted after revision
July 21, 2017

DOI <https://doi.org/10.1055/s-0037-1606288>.
ISSN 2194-7619.

© 2017 Georg Thieme Verlag KG
Stuttgart · New York

License terms



stabilization of the newborn is accepted at the majority of centers including our department.² The decision for late surgery is being justified by an effort to reduce the risk of pulmonary hypertension.³

Although most centers have adopted this paradigm, clinical evidence to determine the right timing of surgical CDH repair is still of interest.⁴ Moreover, among lower risk patients, delayed repair does not seem to have an impact on survival.⁵ Serious gastrointestinal symptoms (gastric perforation, sigmoid perforation, volvulus, peritonitis, etc.) have also been described in a few CDH cases during the early neonatal period. These complications seem to have mainly developed prenatally and/or were not clinically manifested immediately after delivery.^{6–13}

Only a few cases^{7–13} of bowel perforation in newborn patients with CDH have been reported. However, all published cases were described in term or near-term infants. In most of these published cases^{8–11} patients had only mild respiratory insufficiency, small defects of the diaphragm, and high survival rate. We report the case of a very low-birth-weight infant with CDH with initially satisfactory postnatal stabilization until bowel perforation occurred with urgent surgery and fatal outcome.

Case Report

The patient prenatally diagnosed with left-sided CDH was born by emergency cesarean delivery due to suspected intrauterine hypoxia at 31st week of gestation with a birth weight of 1,470 g. Signs of severe respiratory distress syndrome (RDS) developed

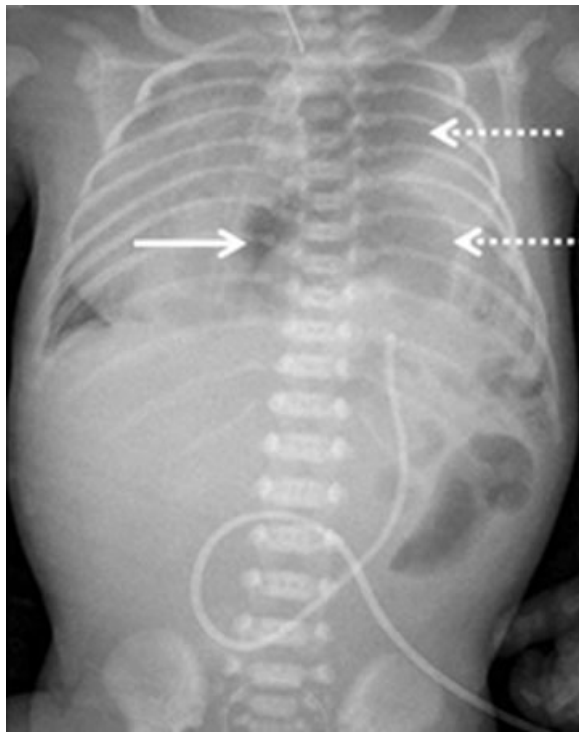


Fig. 1 X-ray of the newborn patient, on the second day of life. X-ray shows left-sided CDH, severe dilation of intestinal loops on the left side of the chest (discontinuous arrow) and free air in the chest (full arrow). CDH, congenital diaphragmatic hernia.

immediately after delivery, and the infant was managed by intubation followed by surfactant administration at 2 hours of age and conventional ventilation. Low doses of dopamine, as well as dobutamine, and volume were administered for mild myocardial dysfunction and hypotension. Postnatal stabilization then proceeded successfully within the first 24 hours (mild respiratory support, small fraction of inspired oxygen—up to 30% fraction of inspired oxygen (FiO₂)—to maintain adequate oxygenation). However, severe cardiopulmonary deterioration occurred on the second day with 100% FiO₂ required to maintain oxygenation. A chest X-ray revealed a dilation of the herniated bowel loops and suspected free air in the chest (▶Fig. 1). The patient recovered from cardiorespiratory collapse after the switch to high-frequency oscillatory ventilation, when higher doses of inotropes were used, after that urgent subcostal laparotomy was indicated.

During surgery, agenesis of the left diaphragm with the narrow medial rim, free meconium in the thoracic and abdominal cavities, rotation of midgut by 180 degrees counterclockwise including incomplete torsion of common mesentery and multiple ischemic lesions with two transmural perforations (terminal ileum and oral sigmoid colon) were found. The left hepatic lobe and spleen were localized in the thorax. Reconstruction of the diaphragm was performed by Gore-Tex patch (Dualmesh 1.0 mm, Gore Medical) and the bowel perforations were closed with interrupted stitches. The abdominal cavity was closed with a patch (Gore-Tex patch Dualmesh 1.0 mm) as a prevention of abdominal compartment syndrome. Second-look procedures followed on the fifth and eighth day of life when multiple parietal bowel necroses in the small intestine and colon were resected and the bowel sutured. The abdominal cavity was permanently covered by a patch. Systemic inflammatory response syndrome unresponsive to aggressive treatment presented from day 2 and progressed to multiple organ failure and death on the 11th day of life. Autopsy disclosed postinflammatory changes in the abdominal and chest cavities and moderate pulmonary hypoplasia with diffuse alveolar hyaline membrane disease. No other congenital anomalies were found. Both intestinal sutures and diaphragmatic reconstruction were healed.

Discussion

We report a very rare case of intestinal perforation during the stabilization period in a preterm infant with CDH. In contrast to the published literature (see ▶Table 1 for details), our patient was a preterm neonate with intrauterine growth restriction (IUGR) and diagnosis of left-sided CDH with diaphragmatic agenesis needing a patch to close the defect. Cases described in the literature include newborns with prenatally diagnosed CDH with a small defect and in-utero perforation of the stomach^{10,12} another group of patients described in literature comprises of term neonates with only mild RDS symptoms and predominant abdominal symptoms^{8,13} and neonates with associated gastrointestinal anomalies, such as Job's syndrome⁹ or associated jejunal atresia.⁷ Therefore, the presented case does not fit into any of the listed patient groups already published. Several risk

Table 1 Overview of the published literature on the topic

Authors, year	Medical history	Perioperative findings	Outcome
Silverman et al, ⁶ 1986	Near-term newborn, twin A, IUGR, pleural effusion and ascites, pneumoperitoneum and pneumothorax, developed later—thoracocentesis and cytology confirmed meconium and diagnosis of right-sided CDH Mild RDS	Sigmoidal perforation with meconial peritonitis and pleuritis in infant with CDH	No patch Survived
Christopher et al, ⁷ 1990	Term newborn, RDS after delivery treated using hyperventilation. Postnatally diagnosed left-sided CDH. Calcifications scattered throughout the abdominal and thoracic cavities Associated anomaly: jejunal atresia	Incarcerated bowel in left hemithorax, meconium, and cloudy fluid in abdomen, symptoms of peritonitis Two perforations detected (area not specified)	Systemic inflammatory response syndrome after surgery No patch Survived
Manning et al, ⁸ 1992	Term newborn, hospital readmission with postnatally diagnosed CDH, mild RDS, and severe gastrointestinal symptoms	Gastric volvulus was noted. After reduction of the contents, a perforation of size 1 × 1.5 cm within an area of necrosis on the posterior surface of the gastric fundus was noted Gastric volvulus, perforation within an area of necrosis on the posterior surface of the gastric fundus	No patch Survived
Butterworth and Webber, ⁹ 2002	Term newborn, mild RDS, pleural effusion—bile-stained fluid removed by thoracocentesis Associated anomaly: Job's syndrome	Left-sided CDH, perforation of a normally positioned cecum. Meconium staining throughout the peritoneal cavity. Debris in the left pleural space. An ileocecal resection and ileostomy with mucous fistula were performed	Pathologic examination showed a congenital deficiency of the muscularis propria in the perforated area with a chronic inflammatory response No patch Survived
Hyodo et al, ¹⁰ 2002	Term newborn, mild RDS. Prenatally diagnosed CDH and massive ascites without dilated bowels, clearly visible diaphragm between the ascites and pleural effusion	Left-sided CDH, small defect. Perforation was located at the gastric angle. No significant inflammation or calcification of the peritoneum and pleura was identified	No patch Survived
Esposito et al, ¹¹ 2008	Term newborn. Postnatally diagnosed pneumothorax and peritonitis. Moderate RDS requiring ventilation	Left-sided CDH diagnosed during surgery. Perforation of the great curvature	No patch Survived
Komuro and Gotoh, ¹² 2012	Prenatally diagnosed CDH, ascites, and pleural effusion. Near-term newborn, severe RDS improved after thoracic drainage	Left-sided CDH, small defect. Perforation was found in the stomach just proximal to the pylorus and repaired by direct closure	No patch Survived
Jiang et al, ¹³ 2013	Term newborn postnatally diagnosed CDH, presented with gastrointestinal symptoms only	Gastric perforation located at the back wall of greater curvature. Ascites	No patch Survived
Presented case	Prenatally diagnosed CDH. Very low-birth-weight infant, acute RDS, and PPHN. Rebound of respiratory failure on 2nd day of life, severe systemic inflammatory response syndrome and multiple organ failures	Multiple ischemic lesions with two transmural perforations in terminal ileum and oral sigmoid colon Second-look surgery: multiple parietal bowel necrosis in the small intestine and colon	Gore-Tex patch needed to close diaphragmatic defect and abdomen Died on 11th day of life

Abbreviations: CDH, congenital diaphragmatic hernia; IUGR, intrauterine growth restriction; PPHN, persistent pulmonary hypertension of the newborn; RDS, respiratory distress syndrome.

factors for the development of spontaneous intestinal perforation (SIP) in preterm infants were present in our patients' case (severe RDS, IUGR, mild myocardial dysfunction needing circulatory support).^{14,15} No drugs with known adverse side effects in terms of SIP (epinephrine, steroids, indomethacin) were used. Although surfactant is not usually given to CDH patients or patients with hypoplasia of the lungs, in this case, the neonate required surfactant administration for RDS. In addition to the above, prematurity may be a significant factor for the development of SIP and infants with SIP tend to present with symptoms early after delivery.¹⁶ Moreover, incomplete torsion of common mesentery, multiple ischemic intestinal lesions, and meconium

peritonitis were found during first surgery, which may support the hypothesis of spontaneous intestinal perforation rather than prenatally acquired perforation.¹

Preoperative stabilization may have the potential to reduce the risk of pulmonary hypertension in CDH cases² and delayed surgery is the preferred approach. However some unexpected complications (i.e., SIP—as in the presented case, gastric perforation¹⁰) during the stabilization period can occur. Although risk factors for SIP are not preventable by early surgery, SIP needs to be considered among the possible differential diagnoses in a preterm neonate with CDH who is not responding to standard postnatal management or in the case of deterioration during stabilization period after delivery.

The unexpected development of meconium pleuroperitonitis led to systemic inflammatory response syndrome and multiple organ failures. This appears to be the main and unpreventable cause of death in the presented case. The role of other causes, such as foreign bodies—patches, is highly speculative. An enterostomy to decompress the bowel was considered, however not performed due to the fragility of the bowel and the given clinical state of the neonate.

Finally, the unfavorable outcome could among other causes be influenced by the “liver-up” presentation. This commonly remains a challenging issue in CDH patients and is known to be associated with worse prognosis.^{17,18}

Conclusion

Delayed repair of CDH after stabilization will continue to be the standard approach. However, intestinal perforation needs to be considered among the possible differential diagnoses in a clinically deteriorating preterm neonate.

Conflict of Interest

None.

References

- Grover TR, Murthy K, Brozanski B, et al; Children's Hospitals Neonatal Consortium. Short-term outcomes and medical and surgical interventions in infants with congenital diaphragmatic hernia. *Am J Perinatol* 2015;32(11):1038–1044
- Reiss I, Schaible T, van den Hout L, et al; CDH EURO Consortium. Standardized postnatal management of infants with congenital diaphragmatic hernia in Europe: the CDH EURO Consortium consensus. *Neonatology* 2010;98(04):354–364
- Garriboldi M, Duess JW, Ruttenstock E, et al. Trends in the treatment and outcome of congenital diaphragmatic hernia over the last decade. *Pediatr Surg Int* 2012;28(12):1177–1181
- Moyer V, Moya F, Tibboel R, Losty P, Nagaya M, Lally KP. Late versus early surgical correction for congenital diaphragmatic hernia in newborn infants. *Cochrane Database Syst Rev* 2000;(03):CD001695
- Hollinger LE, Lally PA, Tsao K, Wray CJ, Lally KP; Congenital Diaphragmatic Hernia Study Group. A risk-stratified analysis of delayed congenital diaphragmatic hernia repair: does timing of operation matter? *Surgery* 2014;156(02):475–482
- Silverman JF, Kopelman AE. Meconium pleuritis: cytologic diagnosis in a neonate with perforated sigmoid colon and diaphragmatic hernia. *Pediatr Pathol* 1986;6(2-3):325–333
- Christopher TD, Effmann EL, Filston HC. Meconium peritonitis and pleuritis: a clue to perforation of an incarcerated Bochdalek hernia in a neonate. *J Pediatr Surg* 1990;25(05):558–559
- Manning PB, Murphy JP, Raynor SC, Ashcraft KW. Congenital diaphragmatic hernia presenting due to gastrointestinal complications. *J Pediatr Surg* 1992;27(09):1225–1228
- Butterworth SA, Webber EM. Meconium thorax: A case of Bochdalek hernia and cecal perforation in a neonate with Job's syndrome. *J Pediatr Surg* 2002;37(04):673–674
- Hyodo H, Nitsu T, Yoshizawa K, Unno N, Aoki T, Taketani Y. A case of a fetus with gastric perforation associated with congenital diaphragmatic hernia. *Ultrasound Obstet Gynecol* 2002;20(05):518–519
- Esposito C, Settimi A, Centonze A, et al. Bochdalek diaphragmatic hernia, complicated by an antenatal gastric perforation, presenting as a pneumothorax and a perforative peritonitis. *Pediatr Surg Int* 2008;24(03):365–369
- Komuro H, Gotoh C. A case of intrauterine gastric perforation in congenital diaphragmatic hernia. *Pediatr Radiol* 2012;42(10):1267–1268
- Jiang Y, Sun BP, Shi LP. Gastric perforation associated with congenital diaphragmatic hernia in a neonate. *Iran J Pediatr* 2013;23(06):712–714
- Attridge JT, Clark R, Walker MW, Gordon PV. New insights into spontaneous intestinal perforation using a national data set: (1) SIP is associated with early indomethacin exposure. *J Perinatol* 2006;26(02):93–99
- Attridge JT, Clark R, Walker MW, Gordon PV. New insights into spontaneous intestinal perforation using a national data set: (2) two populations of patients with perforations. *J Perinatol* 2006;26(03):185–188
- Pumberger W, Mayr M, Kohlhauser C, Weninger M. Spontaneous localized intestinal perforation in very-low-birth-weight infants: a distinct clinical entity different from necrotizing enterocolitis. *J Am Coll Surg* 2002;195(06):796–803
- Ruano R, Takashi E, da Silva MM, Campos JA, Tannuri U, Zugaib M. Prediction and probability of neonatal outcome in isolated congenital diaphragmatic hernia using multiple ultrasound parameters. *Ultrasound Obstet Gynecol* 2012;39(01):42–49
- Usui N, Kitano Y, Okuyama H, et al. Prenatal risk stratification for isolated congenital diaphragmatic hernia: results of a Japanese multicenter study. *J Pediatr Surg* 2011;46(10):1873–1880