

CLINICAL IMAGE

Absent lunula: An overlooked finding in chronic kidney disease

Najla Daadaa¹  | Asmahane Souissi¹ | Badreddine Ben Kaab² |
Mohamed Karim Zouaghi² | Mourad Mokni¹

¹Dermatology Department, La Rabta Hospital, Tunis, Tunisia

²Nephrology Department, La Rabta Hospital, Tunis, Tunisia

Correspondence

Najla Daadaa, La Rabta Hospital, Street Jbel Lakhdar, 1007, Tunis, Tunisia.
Email: daadaanajla1990@gmail.com

Abstract

We highlight the importance of a thorough nail examination in every clinical encounter, especially in uremic patients. Absent lunula should prompt the clinician to rule out underlying kidney disease even in the absence of signs of uremia.

KEYWORDS

absent lunula, chronic kidney disease, hemodialysis

1 | CASE HISTORY

Thorough nails examination should be an integral part of exhaustive physical examination in uremic patients since nail disorders, as absent lunula, can serve as a marker of chronic kidney disease in the absence of more alarming signs.

A 62-year-old man was addressed from the nephrology department for a systematic dermatological check-up. He reported a history of an end-stage chronic kidney disease (CKD) due to hypertensive kidney disease. He had not been on hemodialysis yet. On close observation, the lunula of all fingernails was surprisingly absent (Figures 1 and 2). Blood investigations revealed anemia (11 g/dL), hypocalcemia (73 mg/L), and low serum iron level (0.28 mg/L).

The lunula is the visible portion of the nail matrix that extends beyond the proximal nail fold.¹ Absent lunula (AL) has been recorded in up to 62.9% of patients with CKD² but also described in chronic obstructive pulmonary disease and rheumatoid arthritis.¹ Anemia, seen in our patient, is thought to be a causative effect of AL.³ However, other reports suggested that it reflected rather a combination of several conditions in uremic patients.^{2,3} AL has been observed before

hemodialysis. Thus, it is believed that CKD itself, not particularly hemodialysis, could play a role in the development of AL.²

In conclusion, AL can serve as a marker of CKD in the absence of more alarming signs. Therefore, thorough nails examination should be an integral part of exhaustive physical examination in uremic patients.

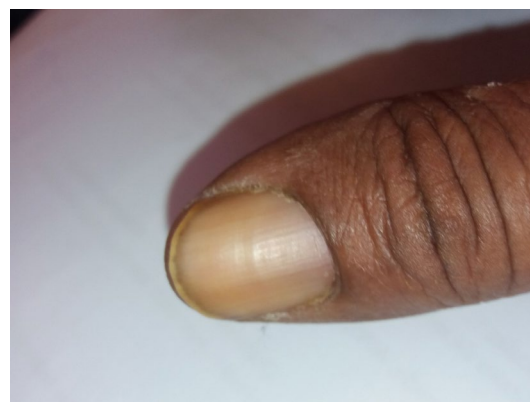


FIGURE 1 Absent lunula of the thumbnail

This is an open access article under the terms of the Creative Commons Attribution License, which permits use, distribution and reproduction in any medium, provided the original work is properly cited.

© 2020 The Authors. *Clinical Case Reports* published by John Wiley & Sons Ltd

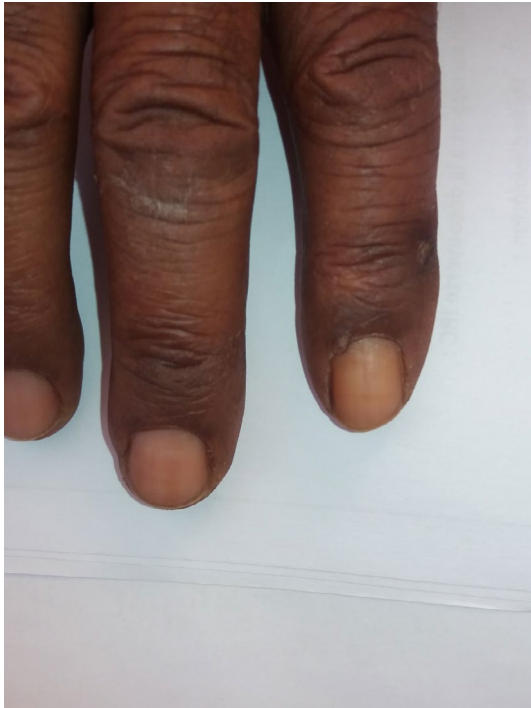

FIGURE 2 Absent lunula of the other fingernails

ACKNOWLEDGMENTS

We thank the patient for granting permission to publish this manuscript. Published with written consent of the patient.

CONFLICT OF INTEREST

No conflict of interest.

AUTHOR CONTRIBUTIONS

DN: helped in writing the manuscript, did literature search, and is corresponding author. AS: collected clinical data, conceptualized the article, and did final proofreading of the submission. KB: helped in writing manuscript and took clinical pictures. MKZ and MM: revised and approved the final version of the manuscript.

DATA AVAILABILITY STATEMENT

Data sharing not applicable to this article as no datasets were generated or analyzed during the current study.

ORCID

Najla Daadaa  <https://orcid.org/0000-0001-6205-6737>

REFERENCES

1. Cohen PR. The lunula. *J Am Acad Dermatol*. 1996;34(6):943-953.
2. Martinez MAR, Gregório CL, Santos VP, Bérqamo RR, Machado CDS. Nail disorders in patients with chronic renal failure undergoing hemodialysis. *An Bras Dermatol*. 2010;85(3):318-323.
3. Salem A, Mokadem S, Attwa E, Abelraoof S, Ebrahim HM, Faheem KT. Nail changes in chronic renal failure patients under haemodialysis. *J Eur Acad Dermatol Venereol*. 2008;22(11):1326-1331.

How to cite this article: Daadaa N, Souissi A, Ben Kaab B, Zouaghi MK, Mokni M. Absent lunula: An overlooked finding in chronic kidney disease. *Clin Case Rep*. 2021;9:576–577. <https://doi.org/10.1002/ccr3.3471>