



Case Report

Death due to fracture of thin calvarial bones after a fall: A forensic approach

Georgios Sioutas ^a, Maria-Valeria Karakasi ^b, Stylianos Kapetanakis ^a, Pavlos Pavlidis ^{b,*}^a Department of Anatomy, School of Medicine, Democritus University of Thrace, Dragana, GR 68100, Alexandroupolis, Greece^b Laboratory of Forensic Sciences, School of Medicine, Democritus University of Thrace, Dragana, GR 68100, Alexandroupolis, Greece

ARTICLE INFO

Article history:

Received 9 April 2016

Received in revised form

28 December 2016

Accepted 10 January 2017

Available online 16 March 2017

Keywords:

Calvarial thinning

Thin neurocranial bones

Skull fractures

Cortical thickness

Accidents

Forensic pathology

ABSTRACT

A 45-year-old male was autopsied. He had fallen backwards from a two-stairs height to the ground and passed away. A skull fracture was detected in the left occipital area, extending up to the left side of the skull base. The patient's death occurred due to the very low thickness of the calvarial bones, which led to the aforementioned fracture, and in turn resulted in subarachnoid hemorrhage and death. The cortical thickness was measured and compared with average values at standardized points. Uniform bone thinning was confirmed rather than localized. Calvarial thinning may result from various conditions. In the present case study, however, the exact mechanism which led to the low thickness of the calvarial bones of the patient is undetermined. Death due to the susceptible structure and fracture of calvarial bones has rarely been reported throughout relevant literature.

© 2017 Daping Hospital and the Research Institute of Surgery of the Third Military Medical University. Production and hosting by Elsevier B.V. This is an open access article under the CC BY-NC-ND license (<http://creativecommons.org/licenses/by-nc-nd/4.0/>).

Introduction

The skull can be roughly divided into two parts: the neurocranium, which forms a protective case around the cerebrum, and the splanchnocranium, which forms the skeleton of the face. The upper part of the neurocranium is defined as the "calvaria," a structure externally forming the cranial cavity, containing and protecting the brain.¹ The average normal thickness of the calvarial bones across all anatomical regions of the skull is 6.32 mm.²

The present case study aims to examine a rare autopsy case involving a middle aged male patient with relatively thin bones in the anatomical region of the neurocranium. The patient was in a verbal disagreement with his fiancée, when he accidentally fell backwards from the second doorstep to the pavement. The National Centre of Emergency was alerted almost immediately, but when the ambulance arrived, approximately 10 min later, it was only to confirm the patient's death.

Case report

The deceased was 45 years of age. His height was 1.76 m and weight 78 pounds. Forensic examination of the head revealed a 1-cm-long superficial wound on the soft tissues of the scalp. It was located in the middle of the occipital area. Furthermore, in the left temporo-parieto-occipital area, a hematoma was observed at the epicranial aponeurosis.

During the dissection of the skull cavity, a left occipital fracture was detected, extending to the skull base (Fig. 1). Subarachnoid hemorrhage was evident at the left lobe of the brain as well as cerebellar hemorrhage, due to rupture of the cerebral artery branches. Upon the dissection of the brain, no obvious pathological alterations were noticed macroscopically.

The skull bones of the neurocranium were measured and cortical thickness was found to be relatively thin. No additional pathological process was found responsible for the thinning of the bones.

Thickness measurement of the calvarial bones

The thickness of the calvarial bones was measured at standardized anatomical points of the calvarium. All total thickness measurements were obtained by the same individual with a caliper

* Corresponding author.

E-mail address: pavli@med.duth.gr (P. Pavlidis).

Peer review under responsibility of Daping Hospital and the Research Institute of Surgery of the Third Military Medical University.

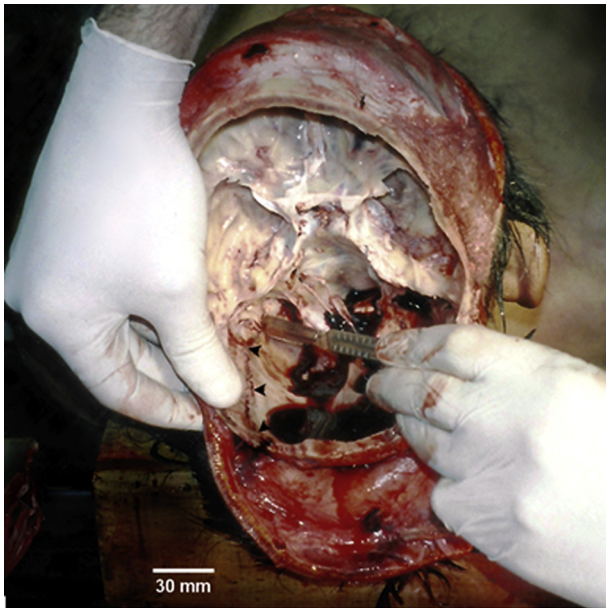


Fig. 1. The three black arrows show the linear fracture at the occipital bone. It was located in the left occipital area, extending up to the skull base, at the left.

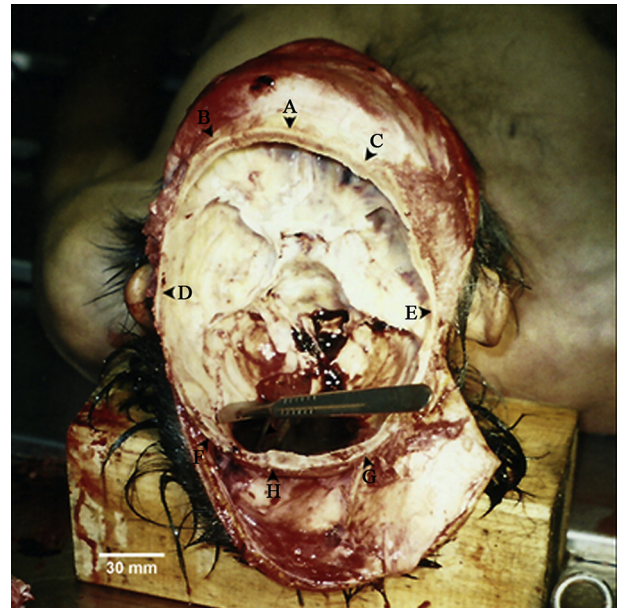


Fig. 2. The eight arrows show the sites of the measurements – A, B, C, D, E, F and G – described in the text.

that was placed perpendicularly to the outer surface at each measurement point. The accuracy of the measurements was ± 0.05 mm. Fig. 2 depicts the exact points where the measurements were taken (Fig. 2).

Thickness point A is situated at the midline, 2 cm superior to the superciliary arch. Thickness points B (left) and C (right) are 2 cm superior to the superciliary arch and 3 cm lateral to the midline. Thickness points D (left) and E (right) are placed 0.5 cm below the upper part of the squamous part of the temporal bone, at the level of the external auditory meatus. Thickness points F (left) and G (right) are located 3 cm lateral to the midline and 1 cm below the external occipital protuberance, while thickness point H is at the midline, 1 cm below the external occipital protuberance.

Measurement results

Thickness A was 4.45 mm, thickness B 4.90 mm and thickness C 4.50 mm, varying significantly from the corresponding average normal values, which are 6.50 mm, 7.00 mm and 7.00 mm respectively.² Thickness D was estimated to be 1.32 mm and thickness E was 1.45 mm, in contrast to the average normal

thickness values which are 5.96 mm and 5.86 mm respectively.⁵ Thickness F was found to be 3.21 mm, while the average normal values in males range from (5.50 ± 1.90) mm to (6.80 ± 2.40) mm, according to different studies. Thickness G was found to be 4.81 mm, while the range of the average normal values in male individuals varies from (5.70 ± 1.70) mm to (6.50 ± 1.70) mm (normal values of different studies). Thickness H was 5.92 mm, while the average normal thickness of the same anatomical point ranges from (11.10 ± 2.50) mm to (12.70 ± 4.10) mm in males (normal values of different studies).^{6,7} The aforementioned measurements are summarized in Table 1.

These measurements unveiled a significant deviation between the thicknesses of the calvarial bones of the examined patient in comparison to the mean normal thickness values. At all points measured, the examined patient had very low cortical thickness at the measured sites.

The forensic and police investigations were subsequently led to the inference that the 45-year-old patient's death was caused accidentally. His left occipital bone was fractured by the fall to the ground and then he died due to cerebral and cerebellar hemorrhage.

Table 1

Measured thickness values of the examined patient compared to the average normal ranges ($n = 8$).

Measured points	Anatomical localization	Thickness values of examined patient (mm)	Average normal thickness values (mm)	Variation from lower limit (mm)	Variation percentage (%)
A	Midline – 2 cm below superciliary arches	4.5	6.5	2.0	30.8
B (Left)	3 cm lateral to midline – 2 cm below superciliary arches	4.9	7.0	2.1	30.0
C (Right)	3 cm lateral to midline – 2 cm below superciliary arches	4.5	7.0	2.5	35.7
D (Left)	0.5 cm below squamous part of the temporal bone – at the level of external auditory meatus	1.3	6.0	4.7	78.3
E (Right)	0.5 cm below squamous part of the temporal bone – at the level of external auditory meatus	1.5	6.0	4.5	75.0
F (Left)	3 cm lateral to midline – 1 cm below external occipital protuberance	3.2	3.6–9.2	0.4	11.1
G (Right)	3 cm lateral to midline – 1 cm below external occipital protuberance	4.8	4.0–8.2	Within normal values	
H	Midline – 1 cm below external occipital protuberance	5.9	8.6–16.8	2.7	31.4

Discussion

The mechanism of skull fractures is influenced by four variables: (a) impact velocity, (b) impact surface, (c) cortical thickness, and (d) cortical density. The thickness of the skull influences the dynamic responses of the head during direct impact. The thicker the skull is, the less the energy is absorbed, which leads to slighter skull deformation.³ Therefore, the risk of injury is inversely proportional to cortical thickness (for example, the risk increases for a cortical thickness of 1.5 mm compared to 3 mm).^{4–7} In the present case study, the relatively low cortical thickness of the calvarium was a significant key factor for the causation of the fracture. Throughout relevant literature, however, calvarium thinning as a death factor is a rarity and as a result, it has been reported, but not extensively studied.^{8–15}

Parietal, biparietal and bilateral parietal thinning have been described in the literature. It is an uncommon condition, with the incidence of 0.25%–0.80%, and a higher prevalence among females. The characteristic site of bilateral parietal thinning is the area between the sagittal suture and parietal prominence. The severity of its clinical expression may range from (painless or painful) palpable depressed regions in the scalp over the thinned areas to fracturing of the areas of parietal thinning with even a fatal outcome.^{8,9}

Calvarial thinning may result from several conditions, such as acute inflammatory atrophy associated with trauma, primary and metastatic tumors, Gorham-Stout disease, hyperparathyroidism, granulomatous diseases, diabetes mellitus, osteomyelitis, systemic mastocytosis, aseptic necrosis, prolonged steroid therapy, bone aneurysm, and cystic angiomas of bone. Five types of idiopathic osteolysis have been described: hereditary multicentric osteolysis with (a) dominant or (b) recessive transmission, (c) nonhereditary multicentric osteolysis with nephropathy, (d) Gorham-Stout disease, and (e) Winchester's disease.^{10,11}

Interestingly, in the present case study, the calvarial thinning was not only localized at the parietal bones. In regard of the diagnosis of the examined patient, the 45-year-old man of the case study was a healthy individual without any systematic

disease. All aforementioned health conditions were excluded, considering the rather generalized (than localized or focal) thinning of the calvarial bones. Although the decedent was a relatively tall individual of good general health and nutrition, the cranial thickness cannot be inferred from an individual's stature and general body build.¹²

References

1. Tubbs RS, Bosmia AN, Cohen-Gadol AA. The human calvaria: a review of embryology, anatomy, pathology, and molecular development. *Childs Nerv Syst.* 2012;28:23–31.
2. Moreira-Gonzalez A, Papay FE, Zins JE. Calvarial thickness and its relation to cranial bone harvest. *Plast Reconstr Surg.* 2006;117:1964–1971.
3. Ruan J, Prasad P. The effects of skull thickness variations on human head dynamic impact responses. *Stapp Car Crash J.* 2001;45:395–414.
4. Hamel A, Llari M, Piercecchi-Marti MD, et al. Effects of fall conditions and biological variability on the mechanism of skull fractures caused by falls. *Int J Leg Med.* 2013;127:111–118.
5. Jung YS, Kim HJ, Choi SW, et al. Regional thickness of parietal bone in Korean adults. *Int J Oral Maxillofac Surg.* 2003;32:638–641.
6. Naderi S, Usal C, Tural AN, et al. Morphologic and radiologic anatomy of the occipital bone. *J Spinal Disord.* 2001;14:500–503.
7. Zipnick RI, Merola AA, Gorup J, et al. Occipital morphology. An anatomic guide to internal fixation. *Spine Phila Pa* 1976. 1996;21:1719–1724. discussion 1729–1730.
8. Yiu Luk S, Fai Shum JS, Wai Chan JK, et al. Bilateral thinning of the parietal bones: a case report and review of radiological features. *Pan Afr Med J.* 2010;4:7.
9. Cederlund CG, Andrén L, Olivecrona H. Progressive bilateral thinning of the parietal bones. *Skelet Radiol.* 1982;8:29–33.
10. Tsutsumi S, Yasumoto Y, Ito M. Idiopathic calvarial thinning. *Neurol Med Chir Tokyo.* 2008;48:275–278.
11. Lo CP, Chen CY, Chin SC, et al. Disappearing calvarium in Gorham disease: MR imaging characteristics with pathologic correlation. *AJNR Am J Neuroradiol.* 2004;25:415–418.
12. Lynnerup N. Cranial thickness in relation to age, sex and general body build in a Danish forensic sample. *Forensic Sci Int.* 2001;117:45–51.
13. Durward A. A Note on symmetrical thinning of the parietal bones. *J Anat.* 1929;63:356–362.
14. Haden MA, Keats TE. The anatomic basis for localized occipital thinning: a normal anatomic variant. *Skelet Radiol.* 1982;8:221–222.
15. Jeffree MA, Molyneux AJ, Lee T, et al. Calvarial thinning in low grade intracerebral gliomas presenting with epilepsy. *Clin Radiol.* 1991;44:406–409.