

# A case report of cardiogenic shock from takotsubo cardiomyopathy with left ventricular outflow tract obstruction: fundamental lessons in cardiac pathophysiology

Quan M. Bui \*, Lawrence Ang, and Nicholas Phreaner 

Division of Cardiovascular Medicine, Department of Medicine, University of California, San Diego, San Diego, 9452 Medical Center Drive #7411 La Jolla, CA 92037-7411, USA

Received 15 November 2020; first decision 11 December 2020; accepted 16 March 2021

## Background

A subset of patients with takotsubo cardiomyopathy will develop significant dynamic left ventricular outflow tract (LVOT) obstruction leading to cardiogenic shock. However, traditional therapies for cardiogenic shock that focus on increased inotropy and afterload reduction can be detrimental in this situation.

## Case summary

We describe a 71-year-old woman who presented to the emergency department with typical, substernal chest pain found to be hypotensive with ST-elevations in the lateral leads. Coronary angiography showed no significant coronary artery disease, but a left ventriculogram demonstrated takotsubo cardiomyopathy. Right heart catheterization revealed cardiogenic shock and elevated filling pressures. Haemodynamics and symptoms worsened with the initiation of dopamine and placement of intra-aortic balloon pump but improved with the initiation of phenylephrine. Follow-up echocardiogram demonstrated dynamic LVOT obstruction with concomitant severe mitral regurgitation (MR). The patient recovered in the intensive care unit for 5 days after successful weaning of phenylephrine and initiation of low-dose beta-blocker. Repeat echocardiogram 3 weeks later showed complete resolution of apical akinesis, LVOT obstruction, and MR.

## Discussion

Elucidating whether dynamic LVOT obstruction is contributing to cardiogenic shock physiology is paramount since the management radically differs depending on the presence or absence of obstruction. Corrective therapy focuses on reducing the LVOT gradient and includes fluid administration to improve preload, beta-blocker therapy to increase diastolic filling time, and vasopressors to raise afterload.

## Keywords

Cardiogenic shock • Takotsubo • LVOT obstruction • Mitral regurgitation • Pathophysiology • Case report

## Learning points

- Traditional therapies for cardiogenic shock that focus on increased inotropy and afterload reduction can be detrimental in patients with significant left ventricular outflow tract (LVOT) obstruction (i.e. Takotsubo cardiomyopathy, hypertrophic obstructive cardiomyopathy)
- Therapy should focus on reducing the LVOT gradient and includes fluid administration to improve preload, beta-blocker therapy to increase diastolic filling time, and vasopressors to raise afterload.

\* Corresponding author. Tel: (858) 246-1326, Fax: (858) 657-1828, Email: [q3bui@health.ucsd.edu](mailto:q3bui@health.ucsd.edu)

Handling Editor: Pierpaolo Pellicori

Peer-reviewers: Luca Arcari and Alessia Gambaro

Compliance Editor: Linh Ngo

Supplementary Material Editor: Mariame Chakir

© The Author(s) 2021. Published by Oxford University Press on behalf of the European Society of Cardiology.

This is an Open Access article distributed under the terms of the Creative Commons Attribution Non-Commercial License (<http://creativecommons.org/licenses/by-nc/4.0/>), which permits non-commercial re-use, distribution, and reproduction in any medium, provided the original work is properly cited. For commercial re-use, please contact [journals.permissions@oup.com](mailto:journals.permissions@oup.com)

## Introduction

Takotsubo (or 'stress') cardiomyopathy is characterized by left ventricular (LV) apical ballooning with transient systolic dysfunction and absence of obstructive coronary artery disease.<sup>1</sup> A minority of patients will develop significant dynamic left ventricular outflow tract (LVOT) obstruction leading to cardiogenic shock.<sup>2,3</sup> Early identification of LVOT obstruction is critical as traditional therapies for cardiogenic shock that focus on increased inotropy and afterload reduction can be detrimental. We present a case of cardiogenic shock secondary to Takotsubo cardiomyopathy complicated by dynamic LVOT obstruction and severe mitral regurgitation to discuss the pathophysiological rationale for appropriate treatment strategies.

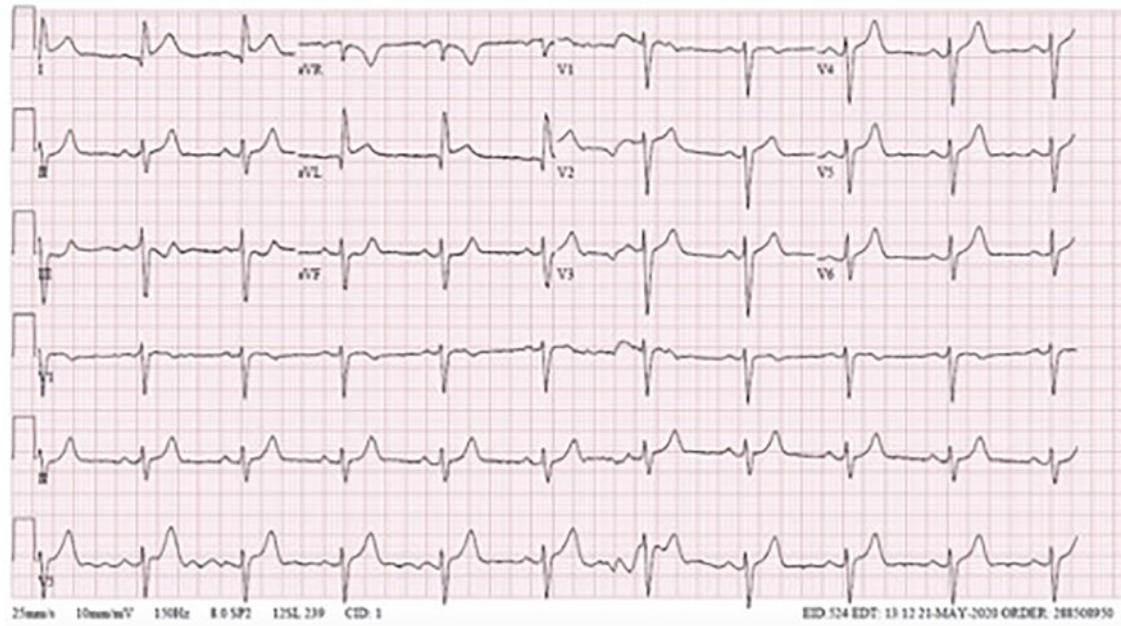
## Timeline

|                      |  |
|----------------------|--|
| Initial presentation | Presented with chest pain, found to have lateral ST-elevations on electrocardiogram.   |
| Day 0                | Taken to the catheterization lab urgently. Left heart catheterization notable for non-obstructive coronary artery disease with left ventriculogram consistent with takotsubo cardiomyopathy. Right heart catheterization revealed cardiogenic shock. Initial echocardiogram showed systolic dysfunction with apical akinesis, hyperdynamic basal segments, systolic anterior motion (SAM) of the mitral valve, left ventricular outflow tract (LVOT) obstruction, and severe mitral regurgitation. |
| Day 1–5              | Admitted to the intensive care unit and started on vasopressors (phenylephrine/norepinephrine) with slow improvement in haemodynamics and cardiac output. Initiation of diuretics for hypoxic respiratory failure due to pulmonary oedema.   |
| Day 6                | Downgraded to medical surgical telemetry level of care. Repeat echocardiogram showed preserved systolic function with residual hypokinesis of the apex with resolution of mitral SAM, LVOT gradient, and only mild mitral regurgitation.   |
| Day 8                | Discharged from the hospital with mild shortness of breath with exertion, but no chest pain.   |
| Day 14               | Outpatient clinic visit with primary cardiologist with resolution of symptoms and back to exercising.  |
| Day 21               | Follow-up echocardiogram showed complete resolution of previous abnormalities.   |

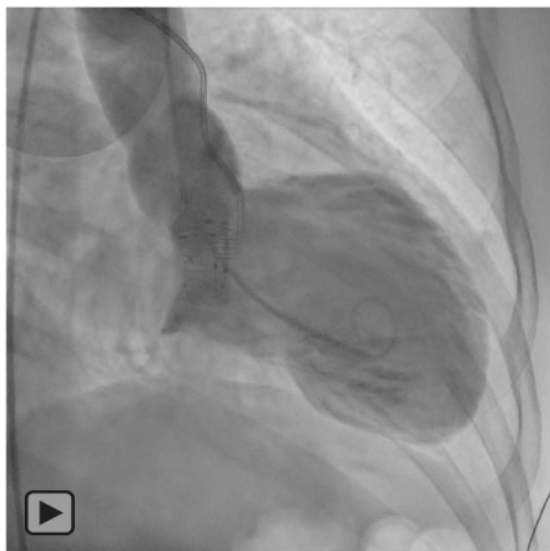## Case presentation

A 71-year-old woman presented to the emergency department with 1 h of substernal chest pain after hiking up a steep hill. Medical history was only significant for gastroesophageal reflux disease, which she initially thought was the cause of her chest discomfort. Vital signs included a heart rate of 59 beats per minute, blood pressure of 82/56 mmHg and oxygen saturation of 99% on room air. Physical examination was notable for an uncomfortable appearing woman with a 2/6 holosystolic murmur localized to the left upper sternal border, jugular venous pressure of 12 cm H<sub>2</sub>O, and cool bilateral lower extremities. Electrocardiogram demonstrated 1-mm ST-elevations in leads I and aVL with reciprocal ST depressions in the inferior leads, concerning for a lateral ST-elevation myocardial infarction and the patient was taken urgently to the catheterization laboratory (*Figure 1*). Coronary angiography showed no significant coronary artery disease and a left ventriculogram demonstrated marked apical akinesis with basal hyperkinesis, consistent with takotsubo cardiomyopathy. Right heart catheterization revealed cardiogenic shock [Fick cardiac output of 2.74 (ref 4–8) L/min and index of 1.61 (ref 2.5–4) L/min/m<sup>2</sup>] with elevated filling pressures [mean right atrial pressure 10 (ref 2–6) mmHg, right ventricular pressure 46/13 (ref 15–30/2–8) mmHg, pulmonary artery pressure 44/21 (mean 29) (ref 15–30/8–15; 9–18) mmHg, mean pulmonary capillary wedge pressure of 27 (ref 6–12) mmHg with a peak v-wave of 45 mmHg] (*Figure 2A*). Given the presence of cardiogenic shock, severely depressed LV systolic function, and marked hypotension with a blood pressure of approximately 70/50 mmHg, a trial of dopamine and placement of an intra-aortic balloon pump (IABP) was attempted but resulted in worsening hypotension. With increasing suspicion for possible LVOT obstruction, invasive assessment with catheter pull back from the left ventricle to the aorta demonstrated a gradient of 34 mmHg, suggesting dynamic LVOT obstruction (*Figure 2B*). Echocardiogram, performed immediately after catheterization, showed an ejection fraction (EF) of 32 (ref 52–72) % with apical akinesis, hyperdynamic basal segments, the systolic anterior motion of the mitral valve with LVOT obstruction [ $V_{max}$  2.6 (ref 0.8–1.0) m/s] and severe mitral regurgitation (MR) (*Figure 3*). Chest X-ray demonstrated moderate pulmonary oedema (*Figure 4*). Labs were notable for a troponin T generation 5 peak of 1692 (ref <22) ng/L, CK-MB peak of 36 (ref 0.0–4.8) ng/mL, creatine phosphokinase (CPK) peak 309 (ref 0–175) U/L, and NT-pro brain natriuretic peptide of 420 (ref 0–449) pg/mL.

The patient was monitored for 5 days in the intensive care unit for cardiogenic shock and acute hypoxic respiratory failure. In the presence of LVOT obstruction, blood pressure was primarily supported with phenylephrine. Low-dose norepinephrine was added to help with concomitant systolic dysfunction, but with cautious up-titration due to fear of worsening obstruction with beta agonism. Aggressive beta-blockade was deferred due to systolic dysfunction and sinus bradycardia, but low-dose metoprolol succinate was initiated after resolution of cardiogenic shock. Fluid administration was avoided due to symptomatic respiratory failure from pulmonary edema. Oxygen supplementation was administered via nasal cannula and was successfully weaned off with the resolution of shortness of breath after gentle diuresis following improvement of LVOT obstruction on repeat echocardiogram. The patient initially received one dose of intravenous furosemide 20 mg with a net negative fluid balance of

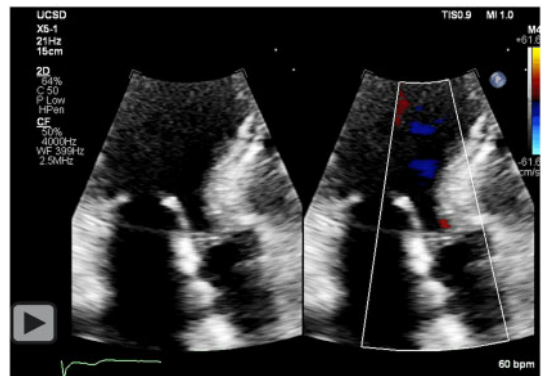


**Figure 1** Admission electrocardiogram.

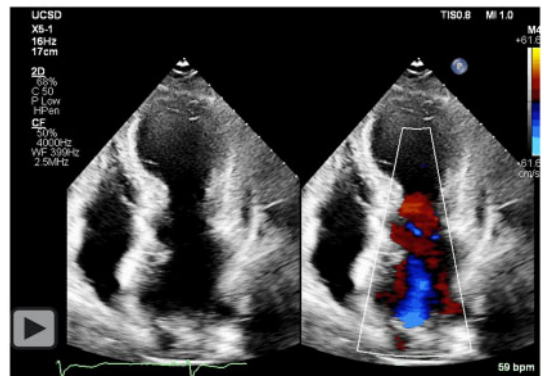


**Video 1** Left ventriculogram demonstrated marked apical akinesis with basal hyperkinesis, consistent with takotsubo cardiomyopathy.

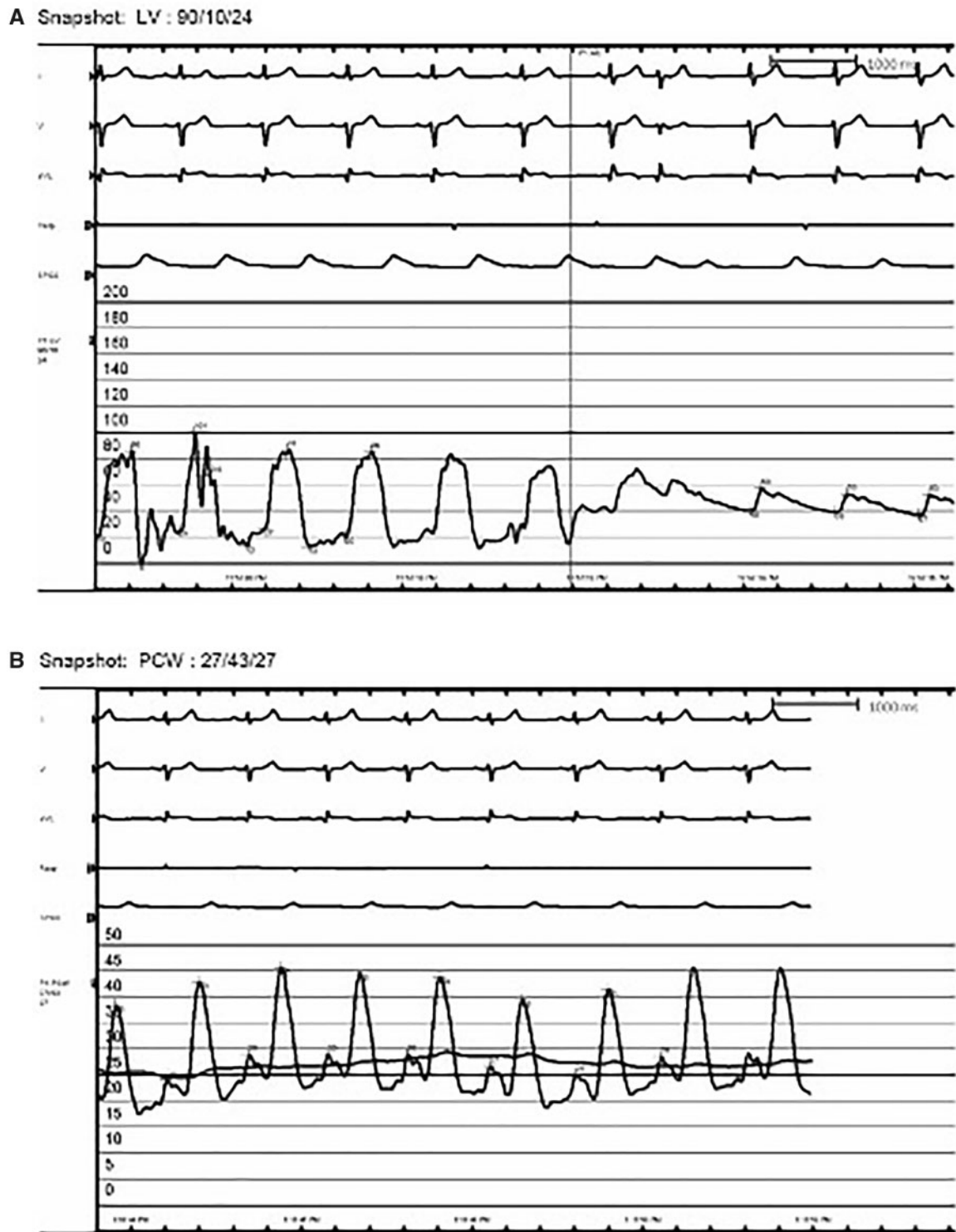
750 mL and then transitioned to oral furosemide 20 mg daily to maintain an even to slightly negative fluid balance. Chest discomfort was initially treated with low-dose narcotics and improved after resolution of cardiogenic shock and the patient was pain free prior to discharge on Day 7 of the hospital course. Two weeks after hospitalization, the patient had resumed low-intensity exercises and



**Video 2** Apical three chamber with colour compare on echocardiogram demonstrating increased velocities across the LVOT.



**Video 3** Apical four chamber with colour compare on echocardiogram demonstrating severe mitral regurgitation.

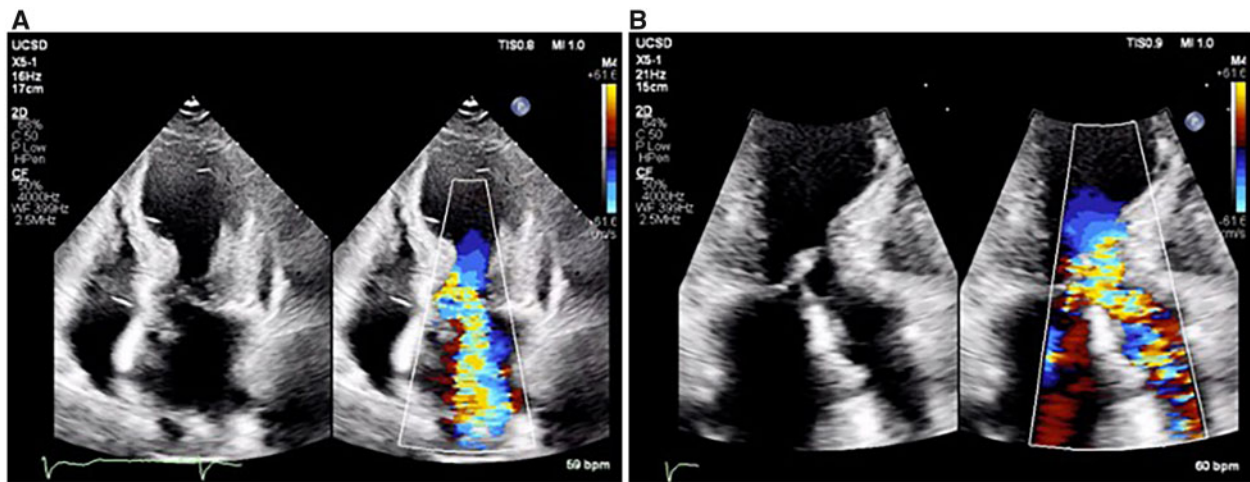


**Figure 2** Cardiac catheterization haemodynamic logs. (A) Left ventricular outflow tract gradient seen on left ventricular to aorta pullback with marked hypotension. (B) Pulmonary capillary wedge pressure tracing with large v-wave.

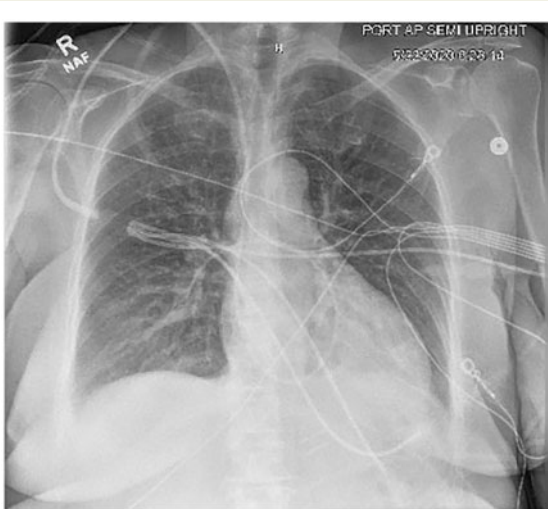remained asymptomatic on beta-blocker and diuretic therapy. Repeat echocardiography 21 days after diagnosis showed normalization of systolic function and complete resolution of apical akinesis, LVOT obstruction, and MR.

## Discussion

In a retrospective study, the estimated prevalence of takotsubo cardiomyopathy amongst patients with the troponin-positive acute



**Figure 3** Transthoracic echocardiogram images. (A) Apical four chamber with colour compare demonstrating severe mitral regurgitation. (B) Apical three chamber with colour compare demonstrating increased velocities across the left ventricular outflow tract.



**Figure 4** Admission chest X-ray.

coronary syndrome is 1% with affected patients predominantly being postmenopausal women.<sup>2</sup> Left ventricular outflow tract obstruction occurs in approximately 19% of those diagnosed with takotsubo cardiomyopathy, more commonly affects the elderly, and is more often complicated by cardiogenic shock than those without obstruction.<sup>2,3</sup>

The key to this case is recognizing that this patient's cardiogenic shock is caused not only by acute systolic dysfunction but also by dynamic LVOT obstruction with severe mitral regurgitation. According to the European Society of Cardiology Guidelines for Treatment of Heart Failure, traditional strategies for acute decompensated heart failure and cardiogenic shock focus on aggressive decongestion, increased inotropy, afterload reduction, and consideration of mechanical circulatory support if no response to pharmacotherapy.<sup>4</sup> However, these therapies can be detrimental in patients with

significant LVOT obstruction. In this case and in concordance with the guidelines, a trial of dopamine and IABP support was pursued given significant hypotension and the assumption that the primary driver of cardiogenic shock was systolic dysfunction. This resulted in augmented LV contraction, further reduction of mean arterial pressure, and worsening clinical status. Subsequently, the IABP was removed and dopamine was discontinued. Given suspicion for LVOT obstruction, the authors performed an invasive assessment for the presence of LVOT obstruction, which can be completed by careful, smooth pull back from the LV cavity to the distal LVOT, then across the aortic valve to the proximal aorta, revealing an LV-distal LVOT gradient of 34 mmHg. Therefore, given the presence of LVOT obstruction, corrective therapy should focus on reducing the gradient and includes fluid administration to improve preload, beta-blocker therapy to increase diastolic filling time, and vasopressors to raise afterload. In this case, the first two strategies were deferred due to significantly elevated left- and right-sided filling pressures on invasive measurement and baseline sinus bradycardia. The patient had improvement in both symptoms and blood pressures with the initiation of vasopressors, including phenylephrine and norepinephrine.

The mechanism of LVOT obstruction involves hyperdynamic contraction of the LV basal segments that create an outflow obstruction and intraventricular pressure gradient, which is further potentiated by a resultant Venturi effect and the systolic anterior motion (SAM) of the anterior mitral valve leaflet.<sup>5</sup> The degree and duration of mitral SAM have been associated with the severity of the dynamic LVOT obstruction gradient.<sup>5</sup> Mitral SAM along with LV dysfunction also contributes to improper leaflet coaptation and mitral regurgitation.

Elucidating whether dynamic LVOT obstruction is contributing to cardiogenic shock physiology is paramount since the management radically differs depending on the presence or absence of obstruction. Early echocardiography should be pursued but is often deferred since most patients are urgently taken for cardiac catheterization when ST-elevations are present.<sup>6</sup> Left ventriculography and catheter pullback gradient can confirm the diagnosis as it did in this case.

Therapies to improve or stabilize haemodynamics should be pursued if LVOT obstruction and cardiogenic shock are encountered.<sup>7,8</sup> Initial fluid resuscitation helps increase LV preload and volume to reduce mitral SAM.<sup>5</sup> Beta-blockers and non-dihydropyridine calcium channel blockers further reduce LVOT obstruction by decreasing heart rate (target < 60 to 70 b.p.m.), increasing diastolic filling time, and decreasing ventricular contractility. However, these interventions should be introduced cautiously in the presence of severe LV dysfunction. Shorter-acting, intravenous agents are initially preferred compared to longer-lasting alternatives.<sup>6</sup> Systemic blood pressure should be supported by therapies that purely increase systemic vascular resistance such as phenylephrine or vasopressin. Conversely, vasodilators (such as nitrates and dihydropyridine calcium channel blockers) should be avoided due to decreased preload, decreased afterload, and worsening of the intraventricular gradient. Norepinephrine may be an option if beta agonism is required in the setting of severe LV dysfunction, but agents with more potent inotropic effect, such as dopamine and dobutamine, have been observed to worsen LVOT obstruction by increasing LV basal contractility. However, if no significant LVOT obstruction is found on either non-invasive or invasive techniques, cardiogenic shock is primarily related to severe LV systolic dysfunction and traditional therapies with afterload reduction, inotropes and mechanical circulatory support are warranted. Where mechanical circulatory support is required in the presence of LVOT obstruction, IABP counter pulsation can deleteriously unload the left ventricle, increase outflow obstruction, and worsen MR.<sup>8–10</sup> In this scenario, case reports have described the successful use of Impella, TandemHeart, and extracorporeal membrane oxygenation as bridges to recovery through left-sided unloading and bypass of the LVOT.<sup>10,11</sup>

The prognosis for patients with takotsubo cardiomyopathy with LVOT obstruction appears favourable and similar to those without obstruction.<sup>5</sup> Most patients have full recovery of LVEF, resolution of dynamic LVOT obstruction, and normalization of MR after 19 days on average.<sup>2</sup>

## Lead author biography



Quan M. Bui, MD, is currently a cardiology fellow at the University of California, San Diego. He plans on pursuing a career in Advanced Heart Failure. His research interests include genetic cardiomyopathies, HCM phenocopies, myocardial strain, and cardiac medical devices.

## Supplementary material

Supplementary material is available at *European Heart Journal—Case Reports* online.

**Consent:** The authors confirm that written consent for submission and publication of this case report including images and associated text has been obtained from the patient in line with the COPE guidance.

**Slide sets:** A fully edited slide set detailing this case and suitable for local presentation is available online as [Supplementary data](#).

**Conflict of interest:** None declared.

**Funding:** None declared.

## References

- Templin C, Ghadri JR, Diekmann J, Napp LC, Bataiosu DR, Jaguszewski M et al. Clinical features and outcomes of takotsubo (stress) cardiomyopathy. *N Engl J Med* 2015;**373**:929–938.
- Backer OD, Debonnaire P, Gevaert S, Missault L, Gheeraert P, Muyldermans L. Prevalence, associated factors and management implications of left ventricular outflow tract obstruction in takotsubo cardiomyopathy: a two-year, two center experience. *BMC Cardiovasc Disord* 2014;**14**.
- El Mahmoud R, Mansencal N, Pilliere R, Leyer F, Abbou N, Michaud P et al. Prevalence and characteristics of left ventricular outflow tract obstruction in Takotsubo syndrome. *Am Heart J* 2008;**156**:543–548.
- Ponikowski P, Voors AA, Anker SD, Bueno H, Cleland JGF, Coats AJS, et al.; ESC Scientific Document Group. ESC Guidelines for the diagnosis and treatment of acute and chronic heart failure. *Eur Heart J* 2016;**37**:2129–2200.
- Fefer P, Chelvanathan A, Dick AJ, Teitelbaum EJ, Strauss BH, Cohen EA. Takotsubo cardiomyopathy and left ventricular outflow tract obstruction. *J Interv Cardiol* 2009;**22**:444–452.
- Chockalingam A, Tejwani L, Aggarwal K, Dellspenger KC. Dynamic left ventricular outflow tract obstruction in acute myocardial infarction with shock: cause, effect, and coincidence. *Circulation* 2007;**116**:e110-3–e113.
- Doucet KM, Labinaz MX, Beauchesne LM, Burwash IG. Cardiogenic shock in takotsubo cardiomyopathy: a focus on management. *Can J Cardiol* 2015;**31**:84–87.
- Lyon AR, Bossone E, Schneider B, Sechtem U, Citro R, Underwood SR et al. Current state of knowledge on Takotsubo syndrome: a position statement from the Taskforce on Takotsubo Syndrome of the Heart Failure Association of the European Society of Cardiology. *Eur J Heart Fail* 2016;**18**:8–27.
- Good CW, Hubbard CR, Harrison TA, Qureshi A. Echocardiographic guidance in treatment of cardiogenic shock complicating transient left ventricular apical ballooning syndrome. *JACC Cardiovasc Imaging* 2009;**2**:372–374.
- Dias A, Núñez Gil JJ, Santoro F, Madias JE, Pelliccia F, Brunetti ND et al. Takotsubo syndrome: state-of-the-art review by an expert panel – Part 2. *Cardiovasc Revasc Med* 2019;**20**:153–166.
- Mohammedzein A, Taha A, Salwan A, Nambiar R. Impella use in cardiogenic shock due to takotsubo cardiomyopathy with left ventricular outflow tract obstruction. *JACC: Case Rep* 2019;**1**:161–165.