



Transbronchial Needle Aspiration Cytology and Purulent Pericarditis

Journal of Investigative Medicine High Impact Case Reports
Volume 8: 1–4
© 2020 American Federation for Medical Research
DOI: 10.1177/2324709620951345
journals.sagepub.com/home/hic


Srilakshmi Vallabhaneni, MD¹, Asim Kichloo, MD² , Amir Rawan, MD², Michael Aljadah, MD², Michael Albosta, MD² , Jagmeet Singh, MD³, and Christopher Cutitta, DO¹

Abstract

Endobronchial ultrasound with transbronchial needle aspiration (TBNA) is commonly performed for the evaluation of mediastinal lymphadenopathy. Purulent pericarditis is a rare, yet potentially fatal complication of TBNA. It commonly presents with nonspecific symptoms such as chest pain, shortness of breath, palpitations, or vague abdominal discomfort. Additionally, more severe symptoms such as cardiac tamponade and even death have been reported. In this article, we present the case of a 58-year-old male who developed purulent pericardial effusion with tamponade thought to be caused by TBNA cytology. This case raises an important question regarding the current guidelines for prophylactic antibiotic treatment for patients at high risk of developing purulent pericarditis as a complication of TBNA.

Keywords

purulent pericarditis, transbronchial needle aspiration cytology

Case Report

A 58-year-old male presented to the hospital with symptoms of nausea, vomiting, abdominal pain, and change in mental status. He was found to have severe hyponatremia at 105 mmol/L requiring treatment with hypertonic saline. During further workup, he was found to have large mediastinal lymphadenopathy and a right middle lobe thin-walled cavitary lesion with multifocal ground-glass opacities (Figure 1). He underwent endobronchial ultrasound (EBUS) with biopsy of the large sub-carinal lymph node, large anterior lymph node, and right hilar lymph nodes. A bronchoscopy was performed, and cytology specimens from the right middle lobe of the lung were collected followed by bronchoalveolar lavage. Pathology from the lymph nodes and bronchial washings revealed high-grade neuroendocrine carcinoma. He was discharged post procedure with plan for an outpatient positron emission tomography scan and Oncology follow-up.

One week later, the patient presented back to the hospital prior to scheduled follow-up with symptoms of nausea, vomiting, abdominal pain, and loss of appetite. Initial vital signs were stable. His laboratory results were significant for serum sodium of 125 mmol/L, chloride of 89 mmol/L, and white blood cell count of 12800/ μ L with a normal differential. Serum creatinine and lactate were normal. A few hours after presentation, he reported symptoms of chest pain and shortness of breath. He subsequently developed atrial fibrillation with rapid ventricular rate and hypotension (86/55 mm Hg).

A transthoracic echo showed moderate to large circumferential pericardial effusion with tamponade physiology (Figures 2 and 3). He underwent pericardial window with drainage of 300 cc of frank pus. Cultures from the pericardial fluid showed colonies of *Streptococcus anginosus* and *Actinomyces odontolyticus*. Cytology was negative for malignancy and acid-fast bacilli. Examination of the pericardial tissue showed acute fibrinous pericarditis.

The patient was started on broad-spectrum antibiotics, with eventual narrowing to vancomycin. Two sets of blood cultures on 2 separate days demonstrated no growth. His vital signs improved, and he was continued on vancomycin. He was started on colchicine for pericarditis and Cardizem for rate control of atrial fibrillation. However, 5 days post procedure, the patient developed melanic stools with a drop-in hemoglobin and hematocrit from 10.7 g/dL/30.8% to 7.9 g/dL/22.7% requiring transfusion. He was also found to have hepatic lesions suspicious for metastases. He had

¹St. Luke's University Health Network, Bethlehem, PA, USA

²Central Michigan University, Saginaw, MI, USA

³Guthrie Robert Packer Hospital, Sayre, PA, USA

Received July 8, 2020. Revised July 22, 2020. Accepted July 25, 2020.

Corresponding Author:

Asim Kichloo, MD, Department of Internal Medicine, Central Michigan University, 1000 Houghton Avenue, Saginaw, MI 48602, USA.
Email: kichloosim@gmail.com



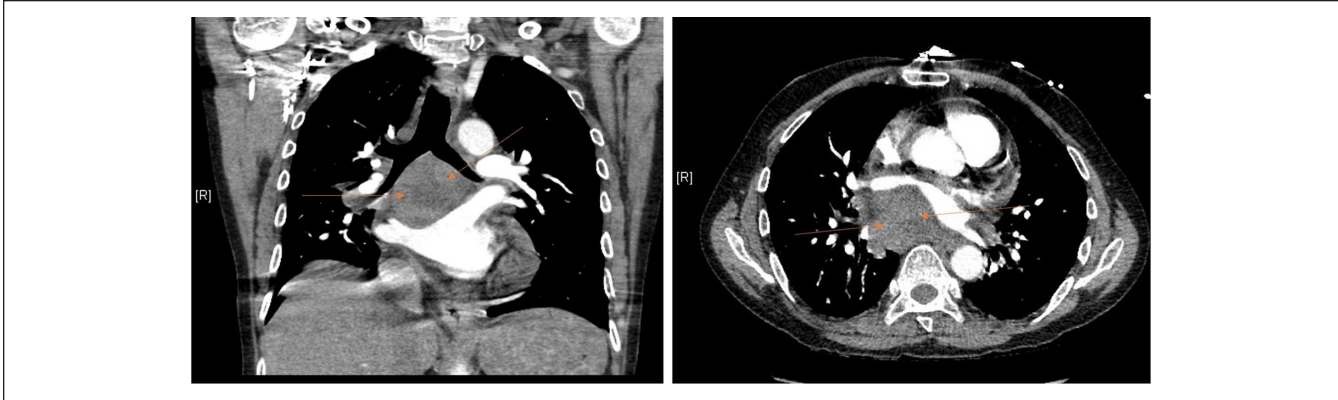


Figure 1. (A) Computed tomography (CT) chest without contrast coronal view demonstrating large mediastinal lymphadenopathy (orange arrows). (B) CT chest without contrast axial view also demonstrating large mediastinal lymphadenopathy (orange arrows).

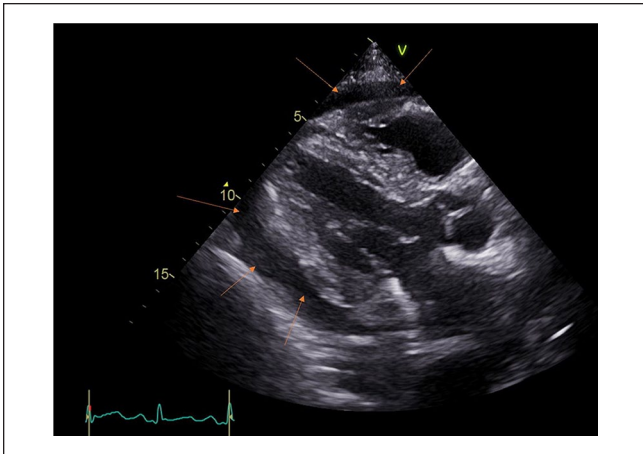


Figure 2. Transthoracic echocardiogram parasternal long-axis view showing moderate to large circumferential effusion (orange arrows). The patient subsequently underwent drainage of pus.

worsening hypotension, and repeat transthoracic echo showed no re-accumulation. He was transferred to the intensive care unit for further care; however, the family requested comfort care. The palliative team was consulted, and the patient was transitioned to comfort care.

Discussion

Endobronchial ultrasound with transbronchial needle aspiration (EBUS-TBNA) is frequently performed to investigate unexplained mediastinal lymphadenopathy, pulmonary nodules, or to aid in the diagnosis or staging of lung cancers. It is believed to be a relatively safe procedure with complication rates ranging from 0.15% to 1.23%.^{1,2} Complications reported in literature thus far include pneumothorax, pneumomediastinum, mediastinitis, hemorrhage, and bacteremia.²

Recently, attention has been drawn to another infectious complication of this procedure, purulent pericarditis. Based

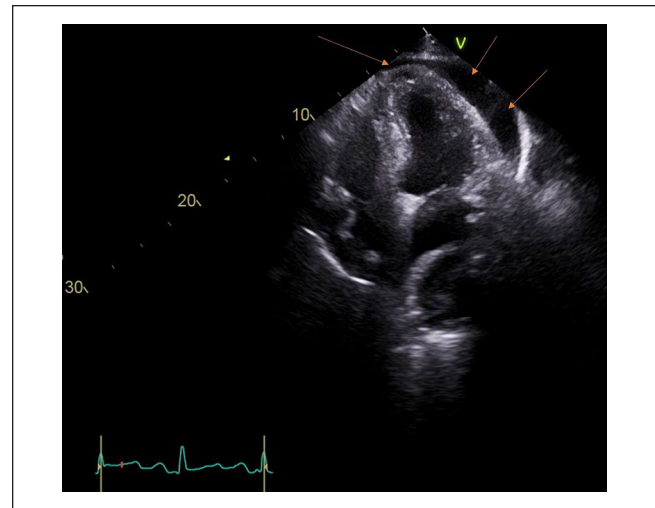


Figure 3. Transthoracic echocardiogram apical 4-chamber view also showing moderate to large circumferential effusion (orange arrows). Cultures of the pus that was subsequently drawn grew *Streptococcus anginosus* and *Actinomyces odontolyticus*.

on data from the limited cases that have been reported, patients suffering this complication often present with non-specific symptoms including shortness of breath, chest pain, palpitations, or vague abdominal complaints, usually within 1 month of the procedure.³⁻⁸ Despite this, some patients may present asymptotically with incidental discovery of the complication. In severe cases, patients may present with cardiac tamponade and development of hemodynamic compromise. Visualization of pericardial effusion on echocardiogram and obtaining pericardial fluid cultures via pericardiocentesis confirms the diagnosis.

Thus far, identified organisms have included *Streptococcus pyogenes*, *Streptococcus viridans*, *Streptococcus mutans*, group C *Streptococcus*, *Actinomyces odontolyticus*, and *Gemella sanguinis*.³⁻⁸ Table 1 demonstrates various case reports describing EBUS-TBNA-induced pericarditis and

Table 1. Literature Review of EBUS-TBNA–Induced Purulent Pericarditis.

Author, year	Age	Gender	Initial presentation	Cultured organism	Outcome
Ostman et al, ⁸ 2008	53	Female	Chest pain, fever, delirium, and joint pain	No organism identified	Discharged
Haas et al, ⁶ 2009	50	Male	Epigastric discomfort, dyspnea, and palpitations	<i>Actinomyces odontolyticus</i> , <i>Streptococcus mutans</i>	Discharged
	58	Female	Fever, cough	N/A	Discharged
Lee et al, ⁴ 2015	55	Male	Cough, dyspnea	<i>Streptococcus viridans</i>	Deceased
	54	Male	Fever, chills, and chest pain	Group C <i>Streptococcus</i> species	Discharged
Matsuoka et al, ⁵ 2015	72	Male	Fever	Group C <i>Streptococcus</i> species	Discharged
Sayan et al, ³ 2019	53	Male	Cough, dyspnea, and orthopnea	<i>Streptococcus pyogenes</i>	Discharged
Inoue et al, ⁷ 2020	69	Male	General fatigue, and appetite loss	<i>Gemella sanguinis</i>	Discharged

Abbreviations: EBUS-TBNA, endobronchial ultrasound with transbronchial needle aspiration; NA, not available.

the organisms yielded from cultures in these cases. In other cases, the organism was unable to be identified on culture.⁸ Interestingly, these organisms, although belonging to different species or strains, are all similar in that they are a part of the normal flora of the oral cavity and mucous membranes. This is an important concept when considering the theory behind the development of purulent pericarditis. The current supported hypothesis states that contamination of bronchoscopy fibers or transbronchial needle (TBN) occurs during the procedure, leading to relocation of normal flora to the pericardium.⁹ This theory was first suggested by Epstein et al in 1992, after potential TBN contamination was studied via culturing TBNs from 7 patients all of which grew mixed aerobic and anaerobic bacteria.⁹ Increased risk of inoculation occurs with repeated puncturing during TBNA, as well as from obtaining biopsies from necrotic or cystic lesions, as these areas are postulated to have reduced blood flow and impaired bacterial clearance.² In our case, pericardial fluid cultures grew *Streptococcus anginosus* (a member of group C Streptococci) and *Actinomyces odontolyticus*. Both are part of the normal flora of the oral cavity, further supporting the above-mentioned hypothesis.

Reported cases were treated with culture-appropriate antibiotics, and although some recovered well and were discharged, others deteriorated with development of cardiac tamponade and subsequent hemodynamic compromise leading to fatality. Thus, a critical question remains, how can we prevent the development of such complications in the future?

First and foremost, following recommended guidelines for equipment decontamination must be strictly adhered to. In addition, ensuring clear visualization of the puncture site by ultrasound during TBNA, limiting the number of punctures, and avoiding necrotic and cystic lesions is predicted to reduce rate of infectious complications. Also, ensuring adequate oral hygiene prior to EBUS-TBNA may aid in minimizing the risk of infectious complications. There is much

debate surrounding the question of whether or not prophylactic antibiotics are indicated for such procedures. Currently, the British Thoracic Society Guidelines for flexible bronchoscopy recommend prophylactic antibiotics only in patients with prosthetic heart valves, history of endocarditis, or asplenia.¹⁰ The question we raise is the following: Should antibiotic prophylaxis be included for patients with necrotic/cystic lesions requiring biopsy or patients with difficult biopsies anticipated to require multiple punctures in an attempt to reduce the rate of this rare yet potentially catastrophic complication of EBUS-TBNA?

Conclusion

Only a few cases of purulent pericarditis secondary to EBUS-TBNA have been reported in the literature thus far. Risk factors include poor oral hygiene, targeting necrotic or cystic lesions, and repeated punctures during procedure. Herein we report a case of EBUS-TBNA–induced purulent pericarditis in an attempt to raise awareness of this rare yet potentially fatal complication. Additionally, we present the concern of whether antibiotic prophylaxis guidelines should be broadened to include those with the aforementioned risk factors and the need of further research.

Author Contributions

All authors have contributed equally to the manuscript.

Declaration of Conflicting Interests

The author(s) declared no potential conflicts of interest with respect to the research, authorship, and/or publication of this article.

Funding

The author(s) received no financial support for the research, authorship, and/or publication of this article.

Ethics Approval

Our institution does not require ethical approval for reporting individual cases or case series.

Informed Consent

Verbal informed consent was obtained from the patient(s) for their anonymized information to be published in this article.

ORCID iDs

Asim Kichloo  <https://orcid.org/0000-0003-4788-8572>

Michael Albosta  <https://orcid.org/0000-0003-4187-4911>

References

1. Gu P, Zhao YZ, Jiang LY, Zhang W, Xin Y, Han BH. Endobronchial ultrasound-guided transbronchial needle aspiration for staging of lung cancer: a systematic review and meta-analysis. *Eur J Cancer*. 2009;45:1389-1396. doi:10.1016/j.ejca.2008.11.043
2. Asano F, Aoe M, Ohsaki Y, et al. Complications associated with endobronchial ultrasound-guided transbronchial needle aspiration: a nationwide survey by the Japan Society for Respiratory Endoscopy. *Respir Res*. 2013;14:50. doi:10.1186/1465-9921-14-50
3. Sayan M, Arpag H. A rare complication of endobronchial ultrasound-guided transbronchial needle aspiration: pericardial empyema. *Lung India*. 2019;36:154-156. doi:10.4103/lungindia.lungindia_262_18
4. Lee HY, Kim J, Jo YS, Park YS. Bacterial pericarditis as a fatal complication after endobronchial ultrasound-guided transbronchial needle aspiration. *Eur J Cardiothorac Surg*. 2015;48:630-632. doi:10.1093/ejcts/ezu477
5. Matsuoka K, Ito A, Murata Y, et al. Severe mediastinitis and pericarditis after transbronchial needle aspiration. *Ann Thorac Surg*. 2015;100:1881-1883. doi:10.1016/j.athoracsur.2014.12.093
6. Haas AR. Infectious complications from full extension endobronchial ultrasound transbronchial needle aspiration. *Eur Respir J*. 2009;33:935-938. doi:10.1183/09031936.00025708
7. Inoue T, Nishikawa T, Kunimasa K, et al. Infectious pericarditis caused by *Gemella sanguinis* induced by endobronchial ultrasound-guided transbronchial needle aspiration (EBUS-TBNA): a case report. *Respir Med Case Rep*. 2020;30:101057. doi:10.1016/j.rmcr.2020.101057
8. Ostman H, Sheperd RW. Mediastinitis and purulent pericarditis following endobronchial ultrasound transbronchial needle aspiration of lymph node. *Chest*. 2008;134:26.
9. Epstein SK, Winslow CJ, Brecher SM, Faling LJ. Polymicrobial bacterial pericarditis after transbronchial needle aspiration. Case report with an investigation on the risk of bacterial contamination during fiberoptic bronchoscopy. *Am Rev Respir Dis*. 1992;146:523-525. doi:10.1164/ajrccm/146.2.523
10. British Thoracic Society Bronchoscopy Guidelines Committee, a Subcommittee of Standards of Care Committee of British Thoracic Society. British Thoracic Society guidelines on diagnostic flexible bronchoscopy. *Thorax*. 2001;56(suppl 1):i1-i21. doi:10.1136/thorax.56.suppl_1.i1